

Tim Knott

The Equine Eye Clinic & Rowe Referrals

www.equineeyeclinic.co.uk

Equine Ophthalmology: Making the most out of your equipment



[Home](#)[Locate a Member](#)[Membership](#)[Resources](#)[Education](#)[Research](#)

Edinburgh, Scotland, EU - 2023



2023 IEOC Equine Ophthalmology Symposium Edinburgh, Scotland

June 1-3, 2023



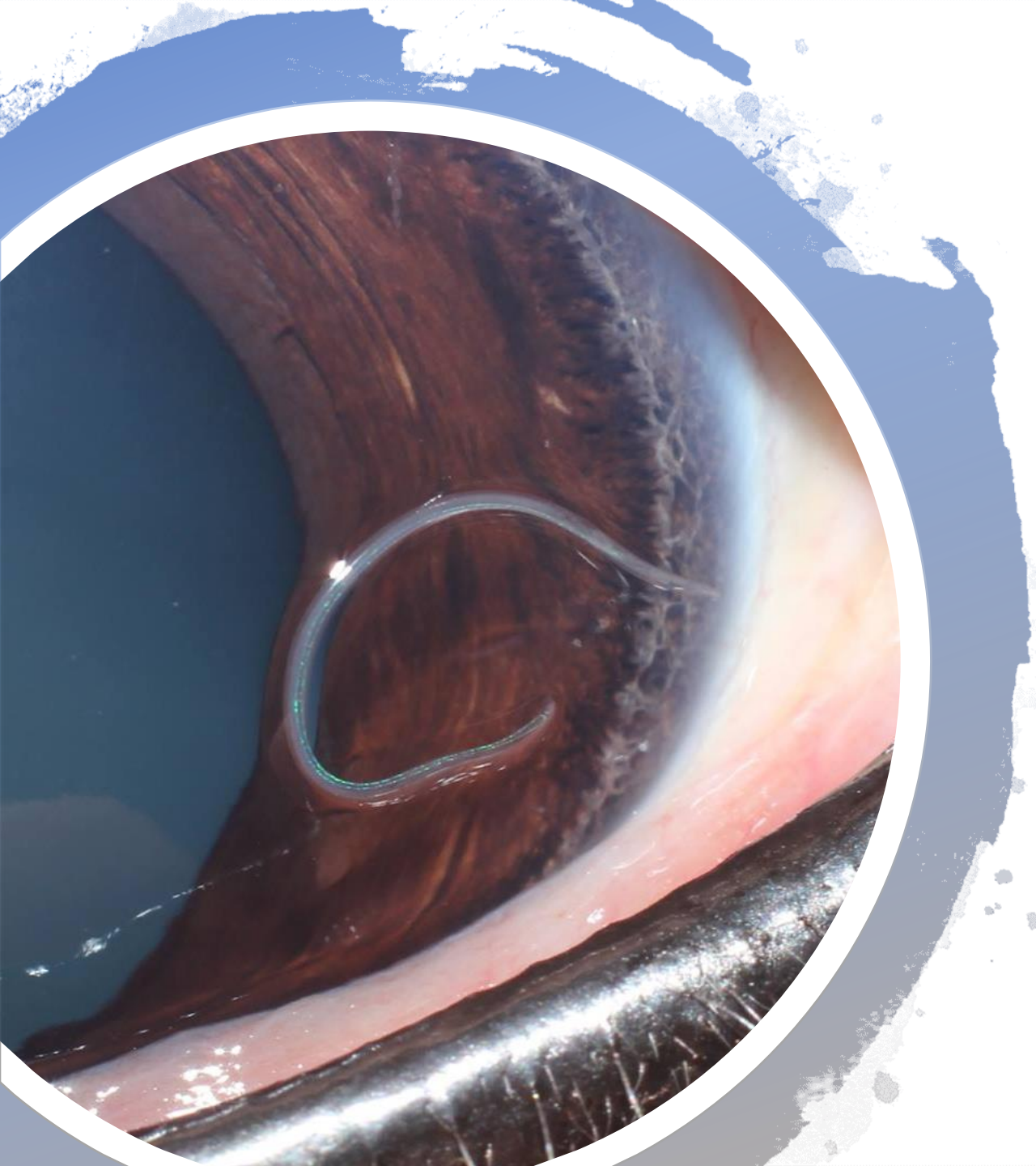
Quick Links

- [Home](#)
- [Forums](#)
- [Forum & Profile Help](#)
- [Industry News](#)
- [Resources](#)
- [Locate a Member](#)
- [What's Your Diagnosis?](#)
- [Member Publications](#)
- [Clinical Articles](#)
- [Glossary](#)

Equipment “must haves”

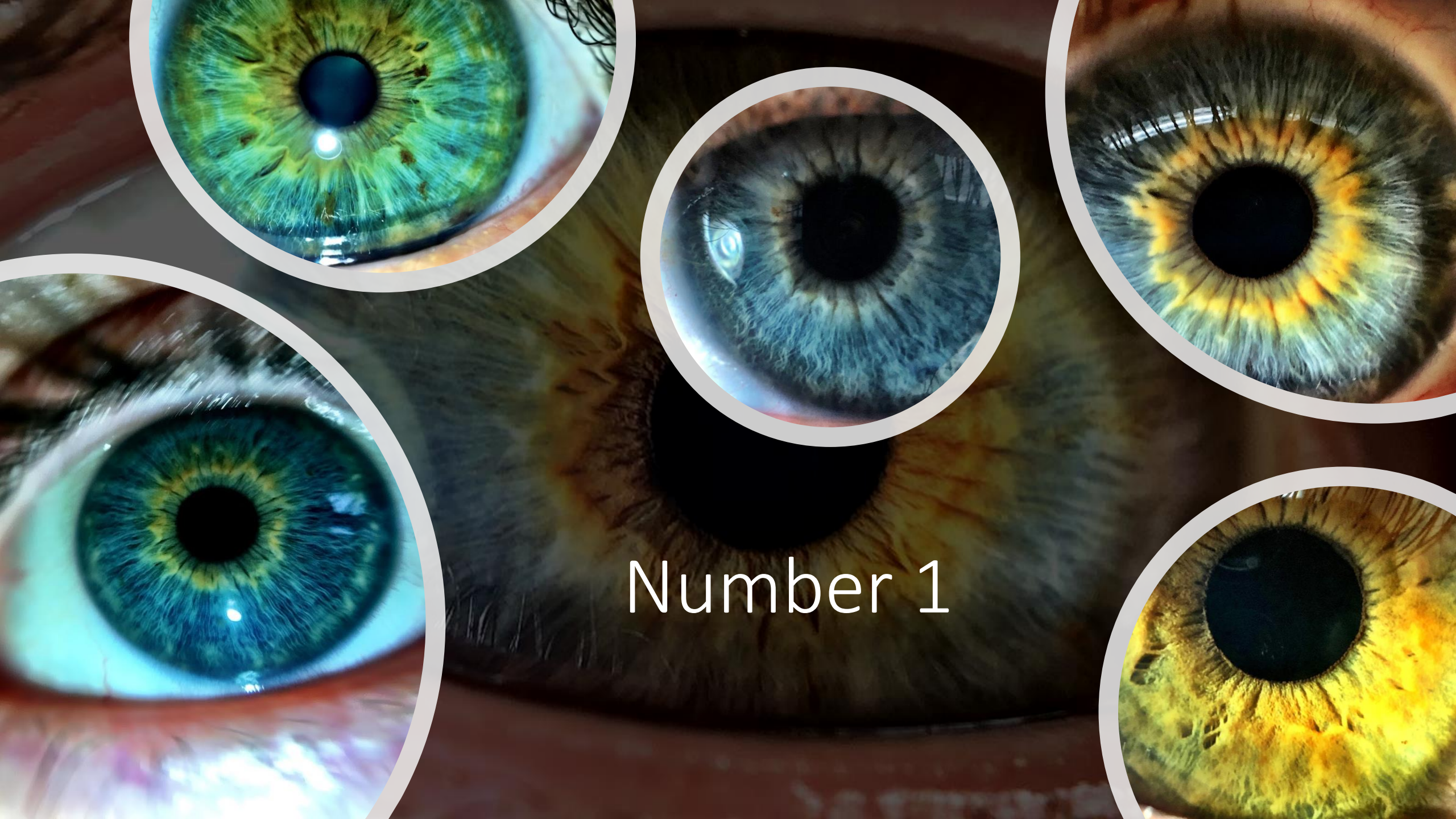What's number 1?



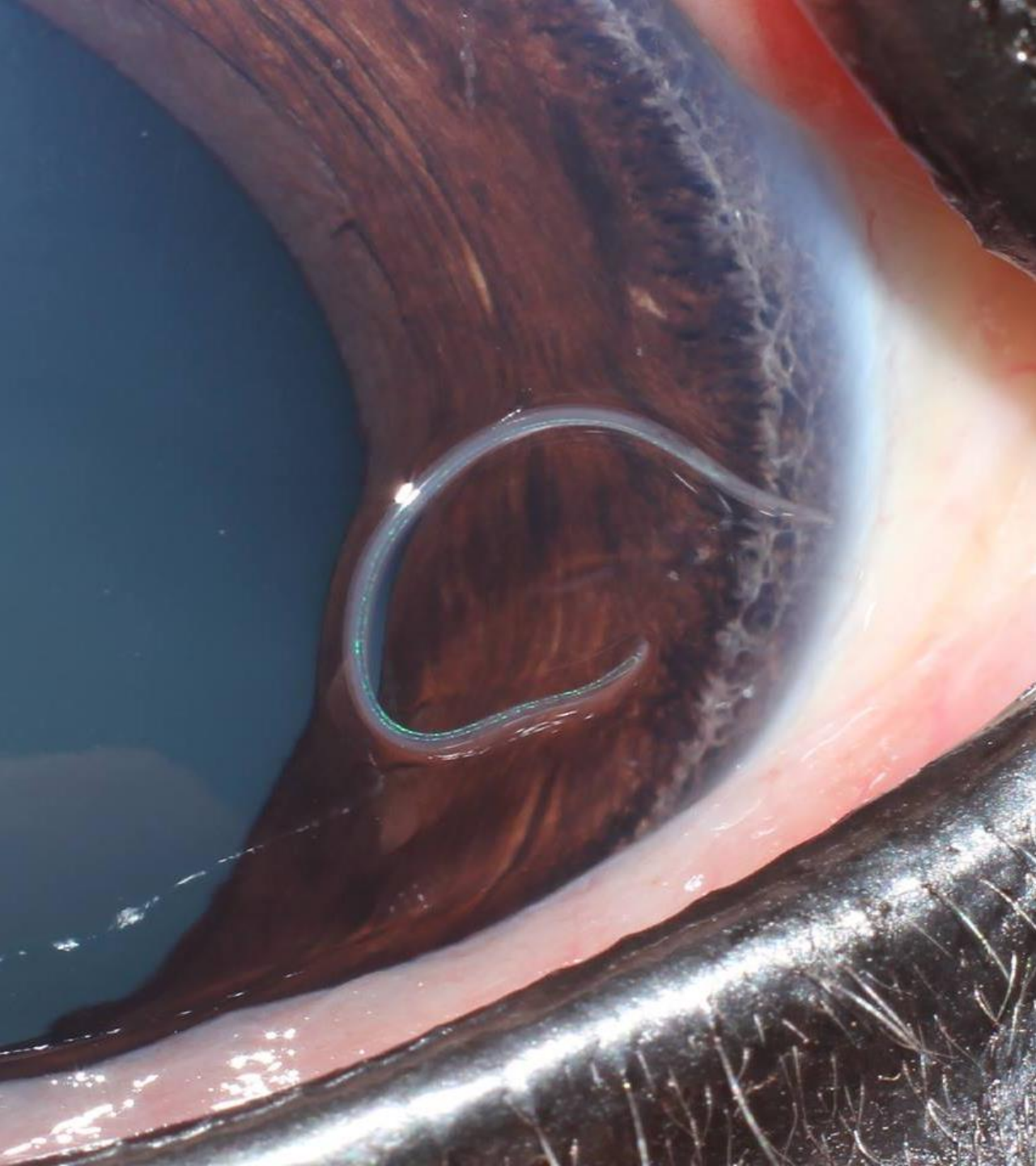

But first a competition...

#1 most important
diagnostic tool



Number 1



Hands up
& what is it?

Equipment-“must haves”

- Direct ophthalmoscope
- Smart phone
 - With an app to allow easier ocular examination
 - “Phone a friend” number
- Head torch
 - Ideally with a rheostat e.g. LedLenser HR7
- Cotton buds, bacteriology swabs & slides
- Magnification
 - Smart phone macro lens
 - Loupes – “optivisor”
 - Reading glasses
- Small needles, tropicamide, local & fluroscein



Equipment-“must haves”

- Direct ophthalmoscope
- Smart phone
 - With an app to allow easier ocular examination
 - “Phone a friend” number
- Head torch
 - Ideally with a rheostat e.g. LedLenser HR7
- Cotton buds, bacteriology swabs & slides
- Magnification
 - Smart phone macro lens
 - Loupes – “optivisor”
 - Reading glasses
- Small needles, tropicamide, local & fluroscein



Direct ophthalmoscope (DO)

Tips

- Batteries – reverse when not in use
- Shake before use
- Clean it
- Glasses off, use DO lenses to compensate for prescription – “find **your** zero dioptre setting”
- Use your rheostat
- Need a new one? Heine, speak to us.

What can we use it for?

www.equineeyeclinic.co.uk

“how to.. section”:

“Demystifying ophthalmoscopy”

- Distant direct
- Lesion localisation, the “search light technique”
- Close direct

Distant direct ophthalmoscopy

- Ophthalmoscope on **your** zero diopter setting
- Large white spot
- Arms length
- Lights off
- Move through 180 degrees



Use as a “pupilometer” : assess pupil size, symmetry, shape and response to light.

Assess tapetal reflectivity & symmetry.

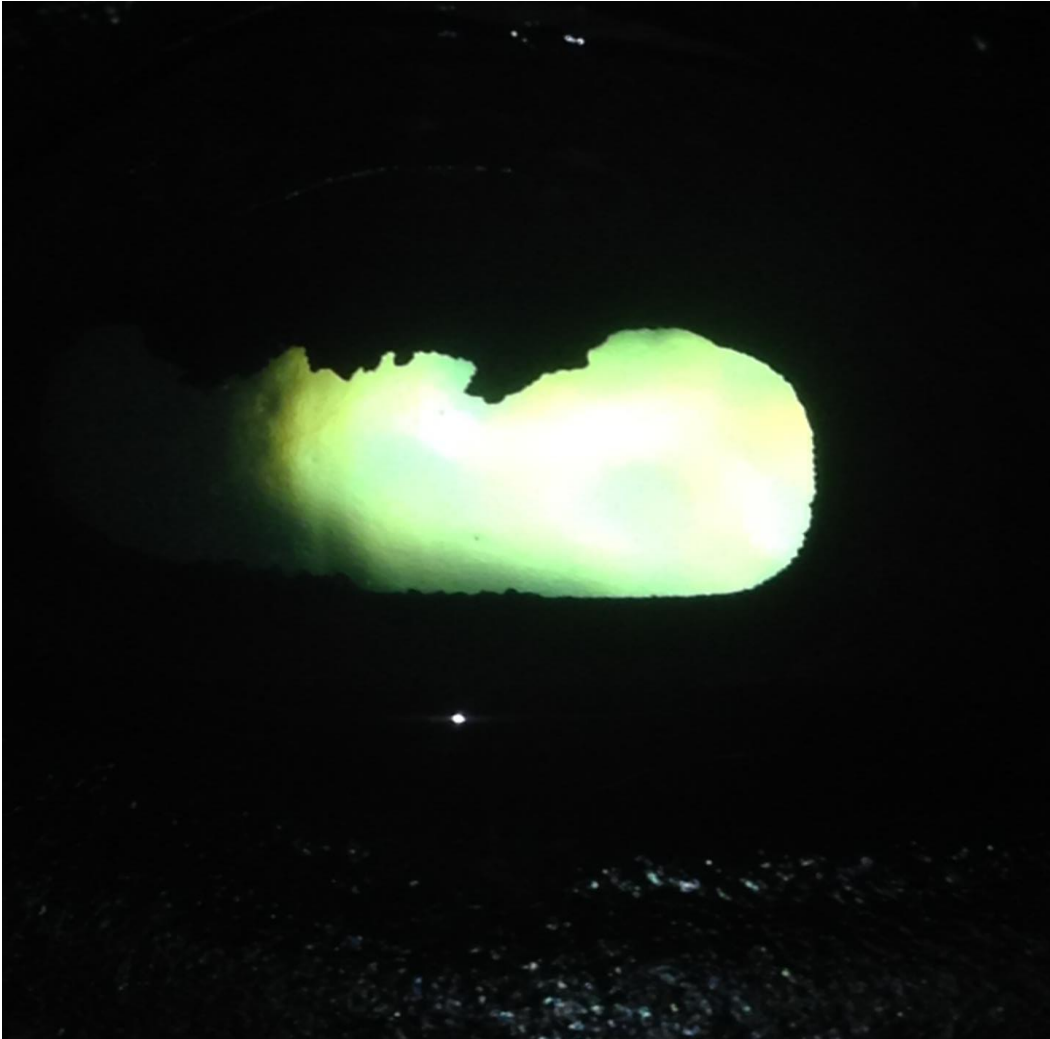
Assess opacities in the visual axis

Assess opacities outside the visual axis

Localisation of opacities using parallax

Localisation of opacities using oblique illumination “the search light technique”.

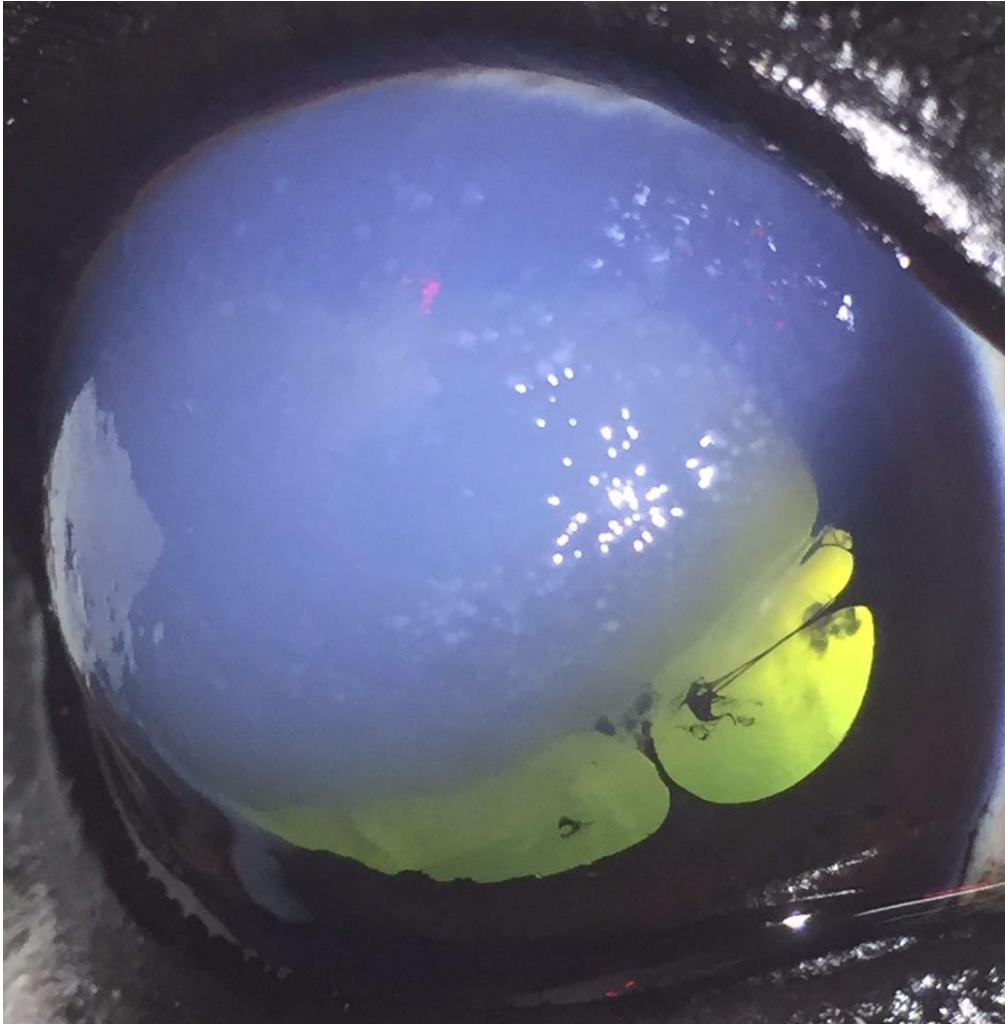
The normal distant direct pupil view



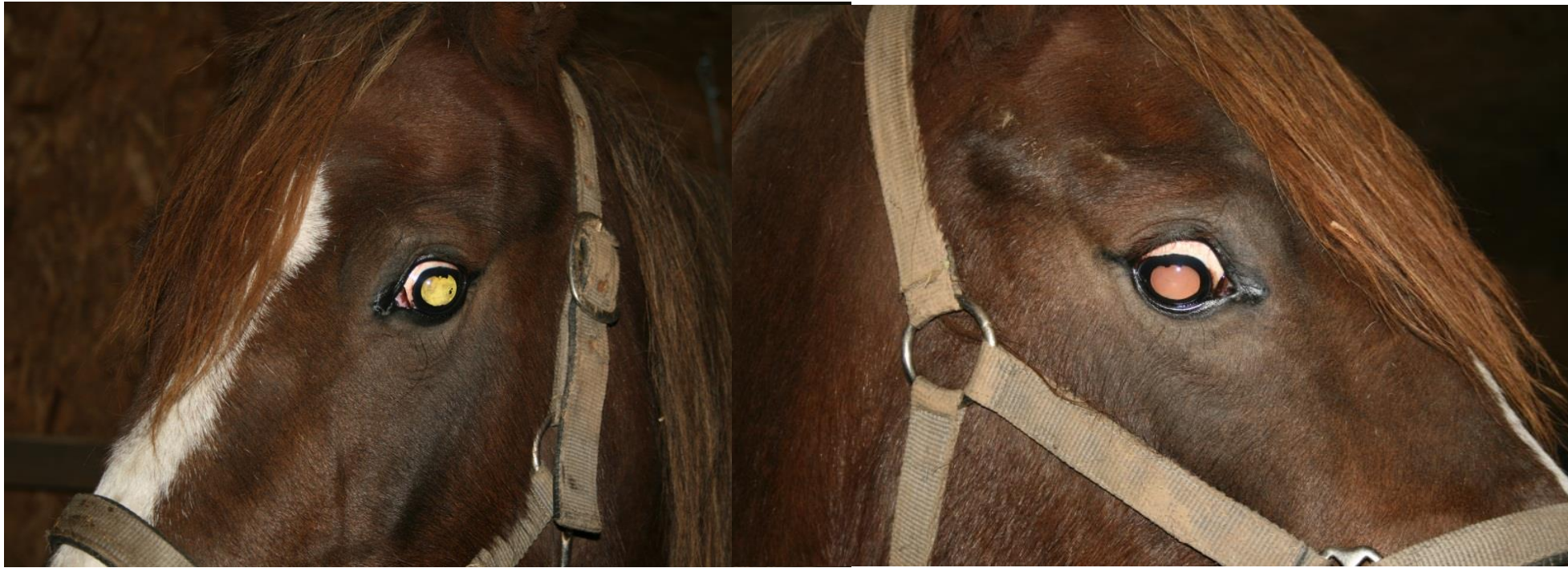- Size & response to light
- Shape
- Tapetal reflection & opacities
- Granular iridica



Chronic uveitis – distant direct pupil view



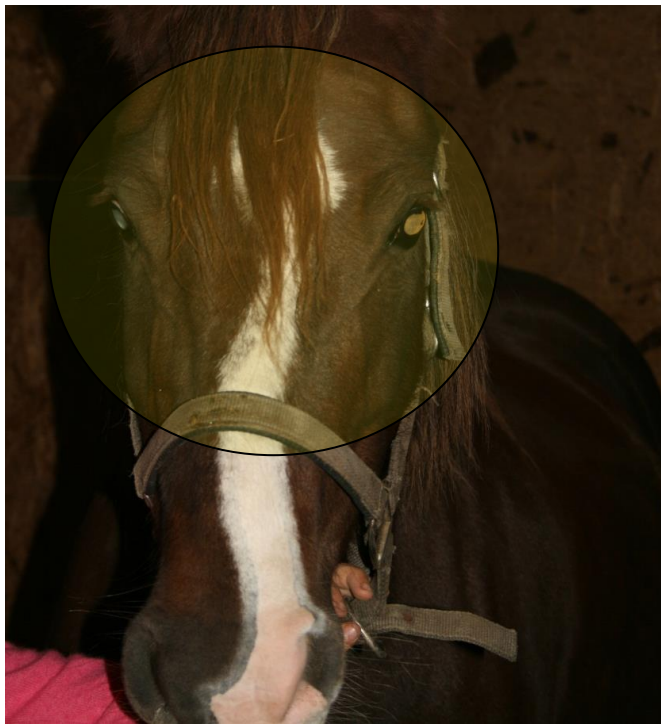
- Pupil dilated & unresponsive to light - Atropinised
- Shape – dyscopic
- Tapetal reflection – normal
- Opacities present – iris rests
- Granular iridica – barely visible but small and “softened” or “smoothed”



Diagnosis at a distance:

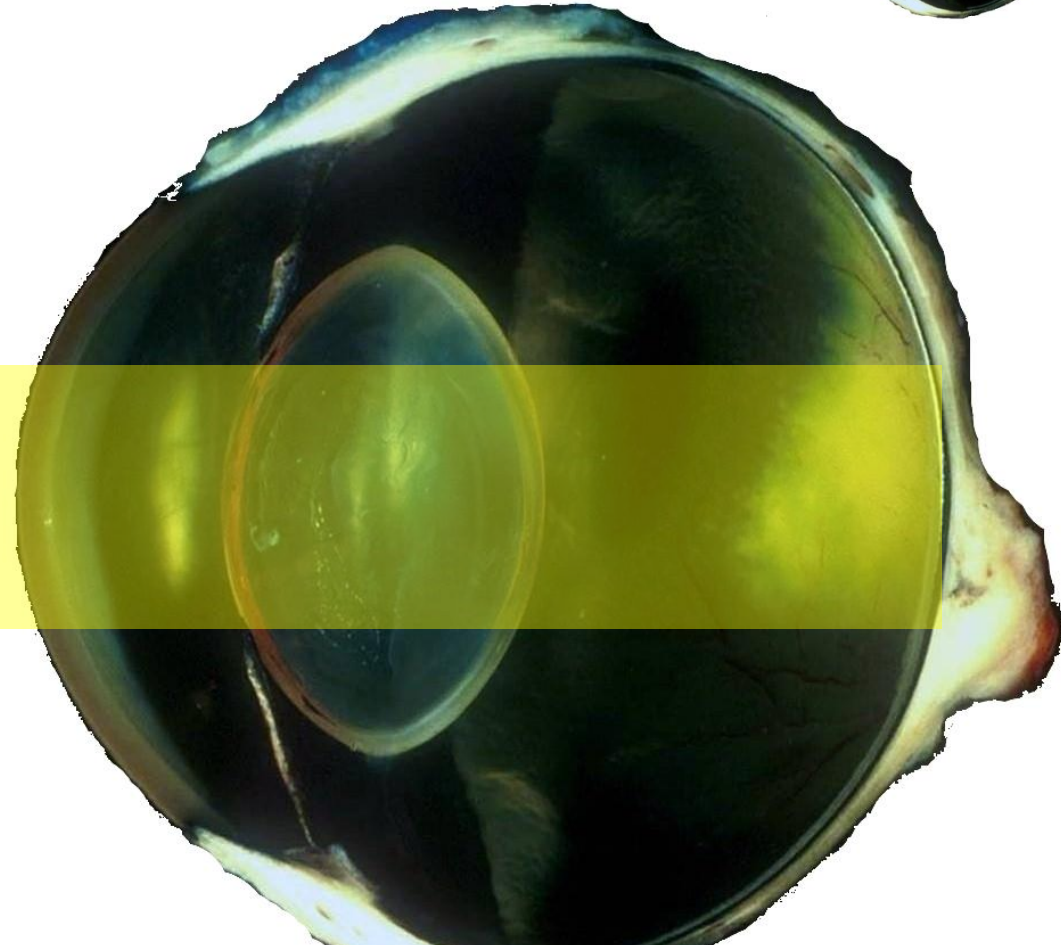

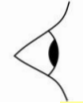
Sudden onset blindness, bilateral total cataract suspected cause

Pupillometer



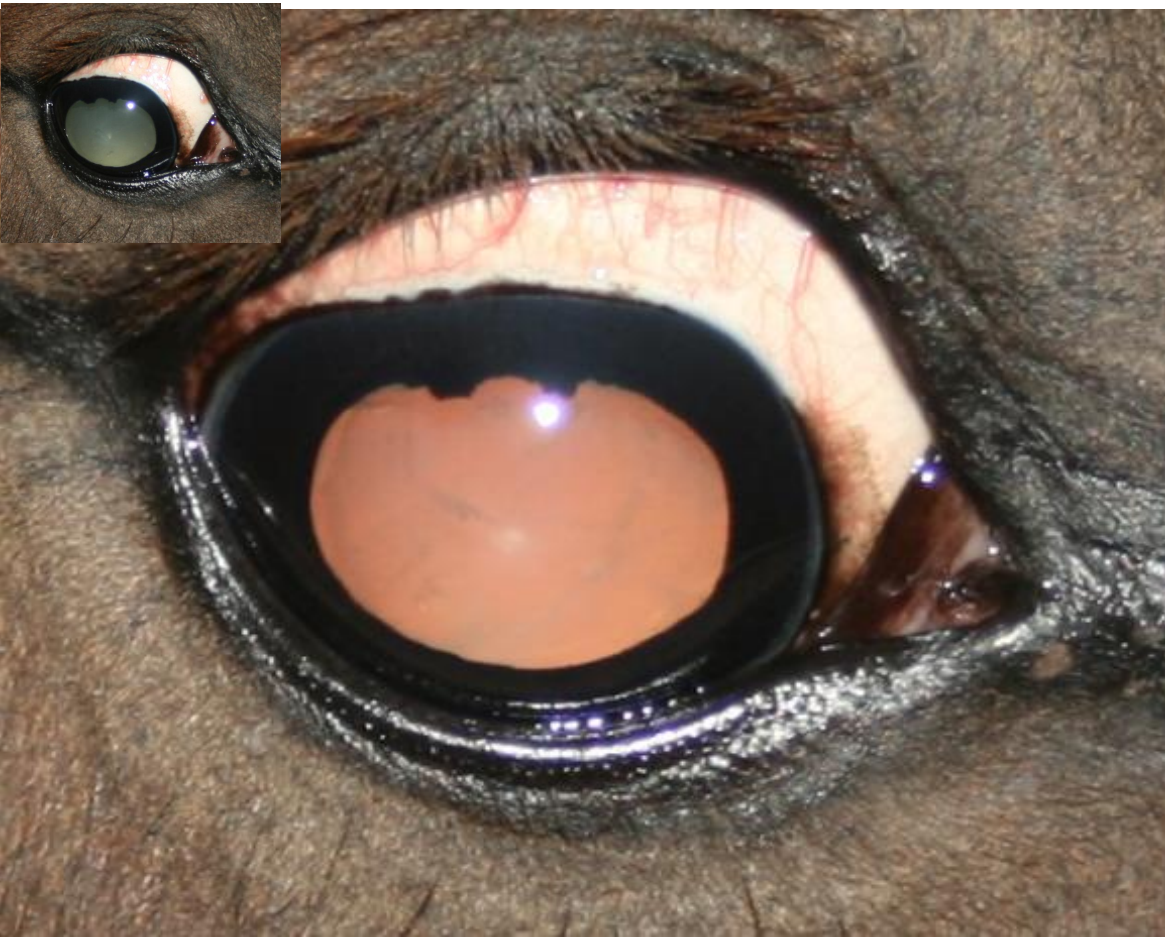

Compare tapetal reflection

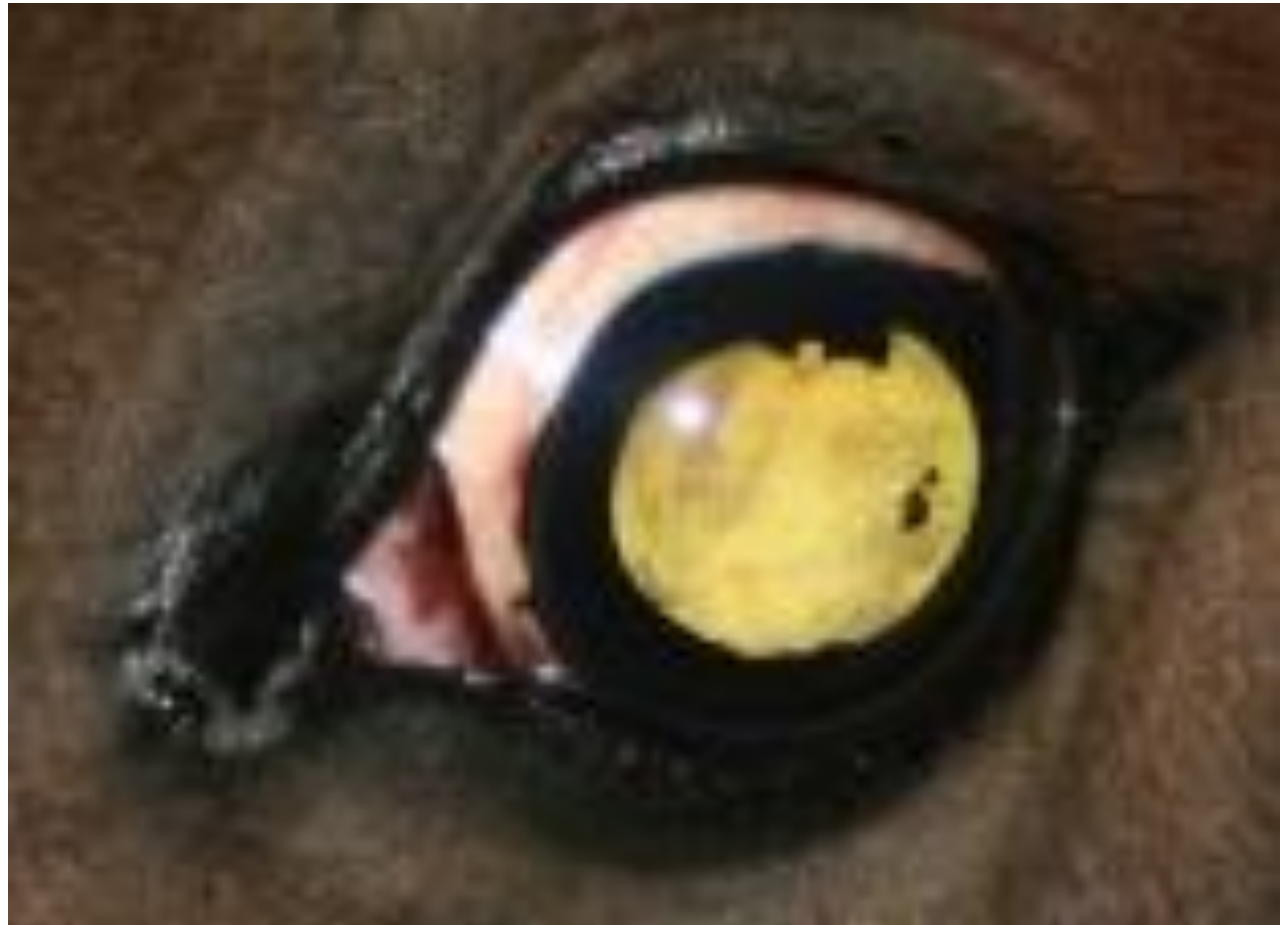

Compare tapetal reflection

- Subalbinotic atepetal fundus,retinal detachment, shrivelled granula iridica skylined.



- Yellow tapetum, hyperreflective, incipient cataract, iris rest, shrivelled granula iridica skylined.



Compare tapetal reflection



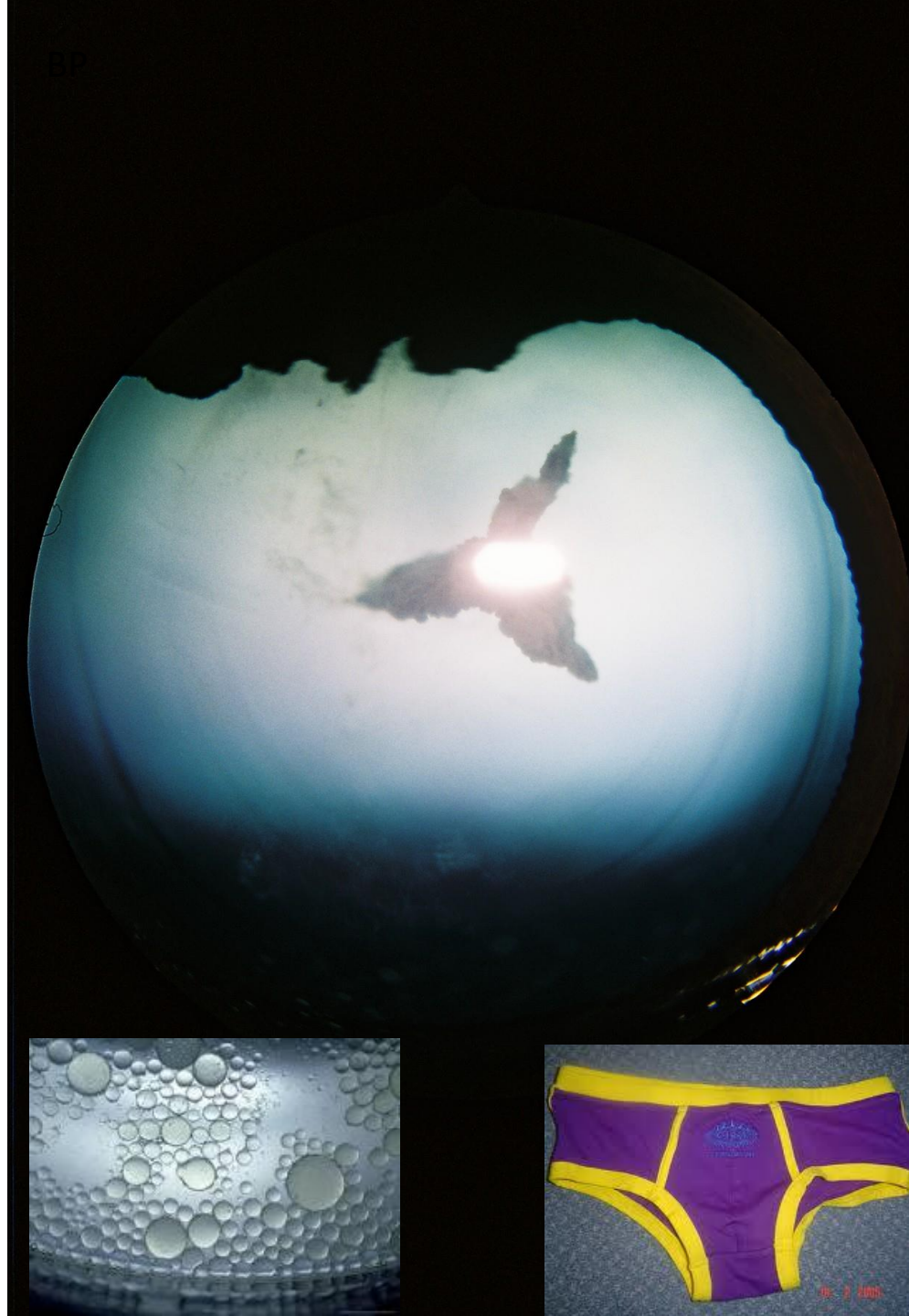


Diagnosis at a distance:

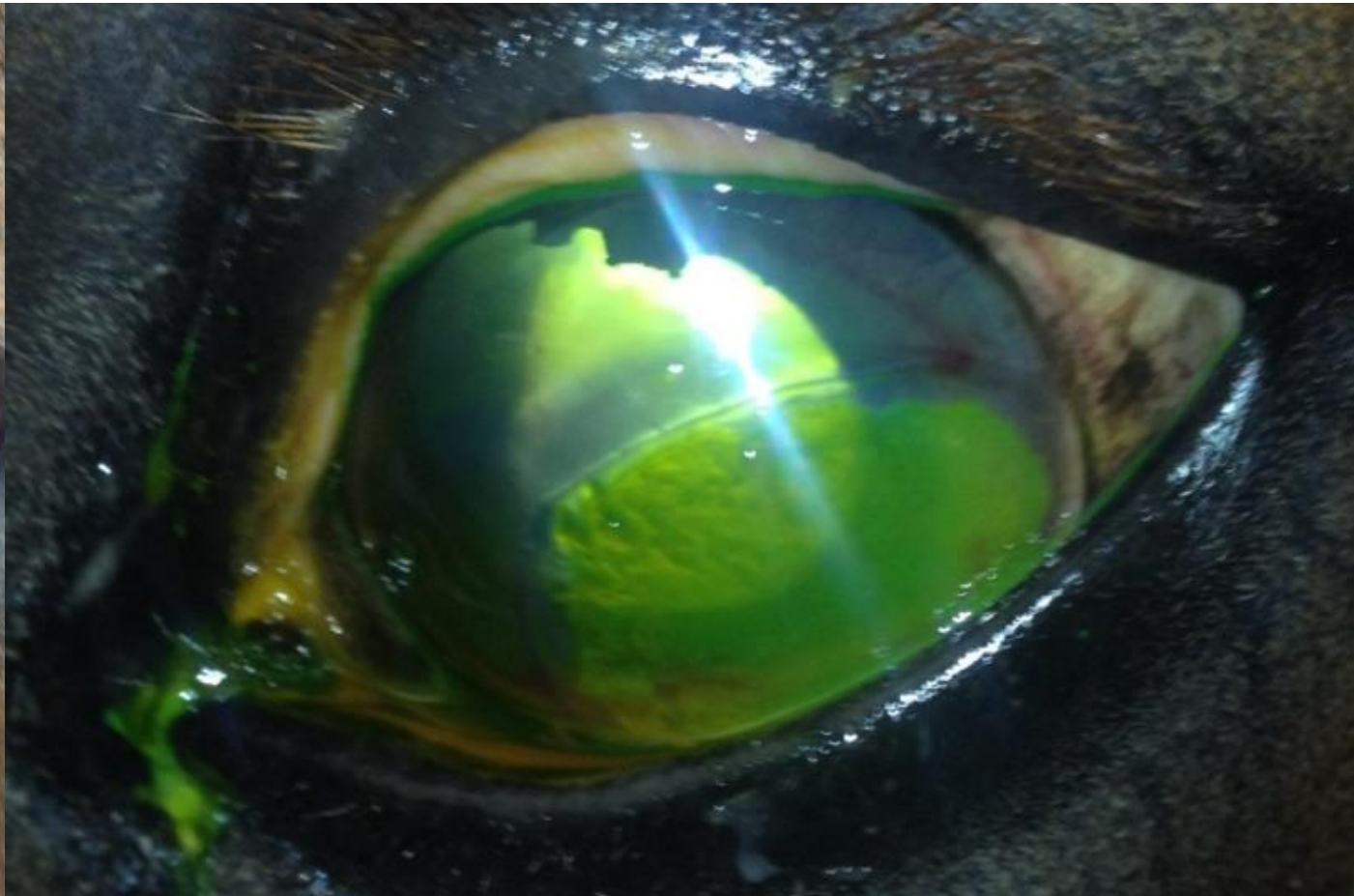
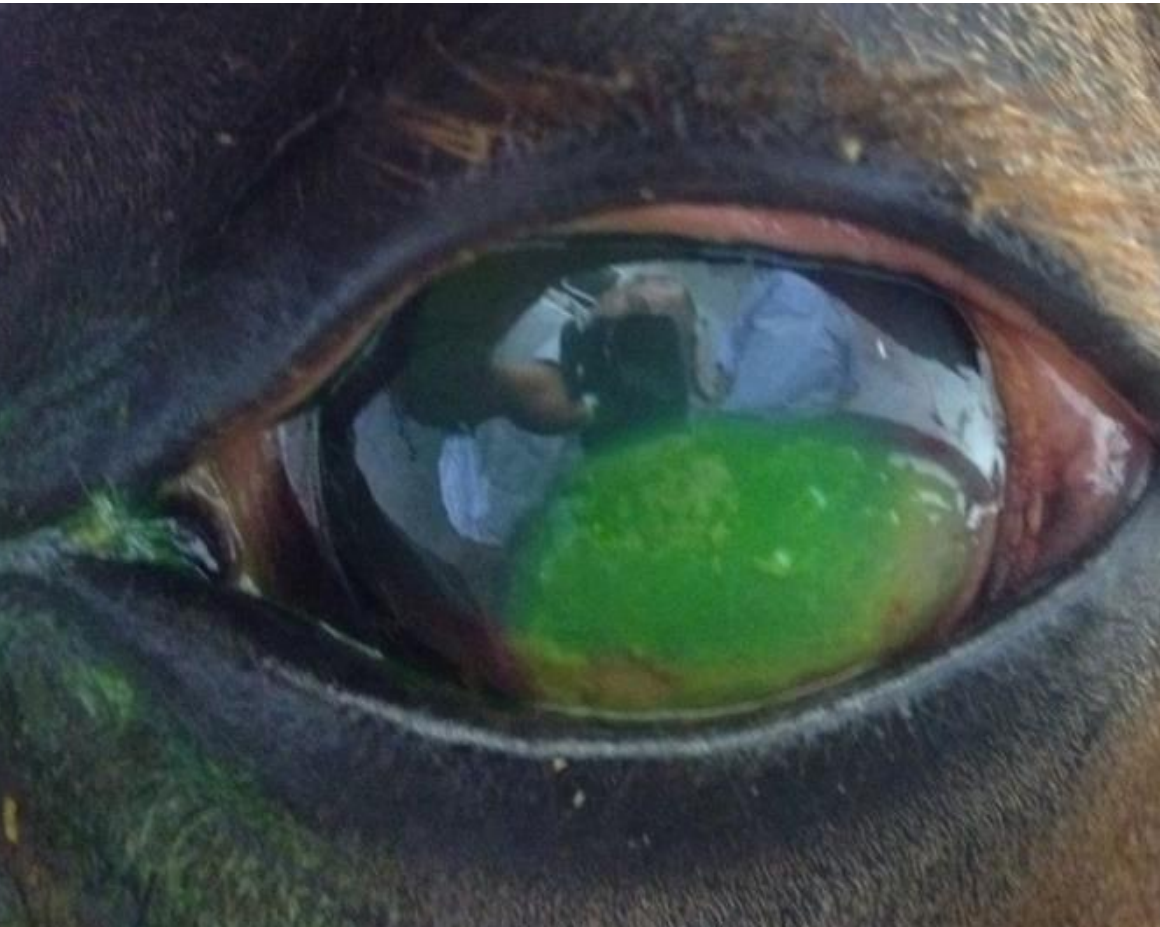Left eye watery discharge



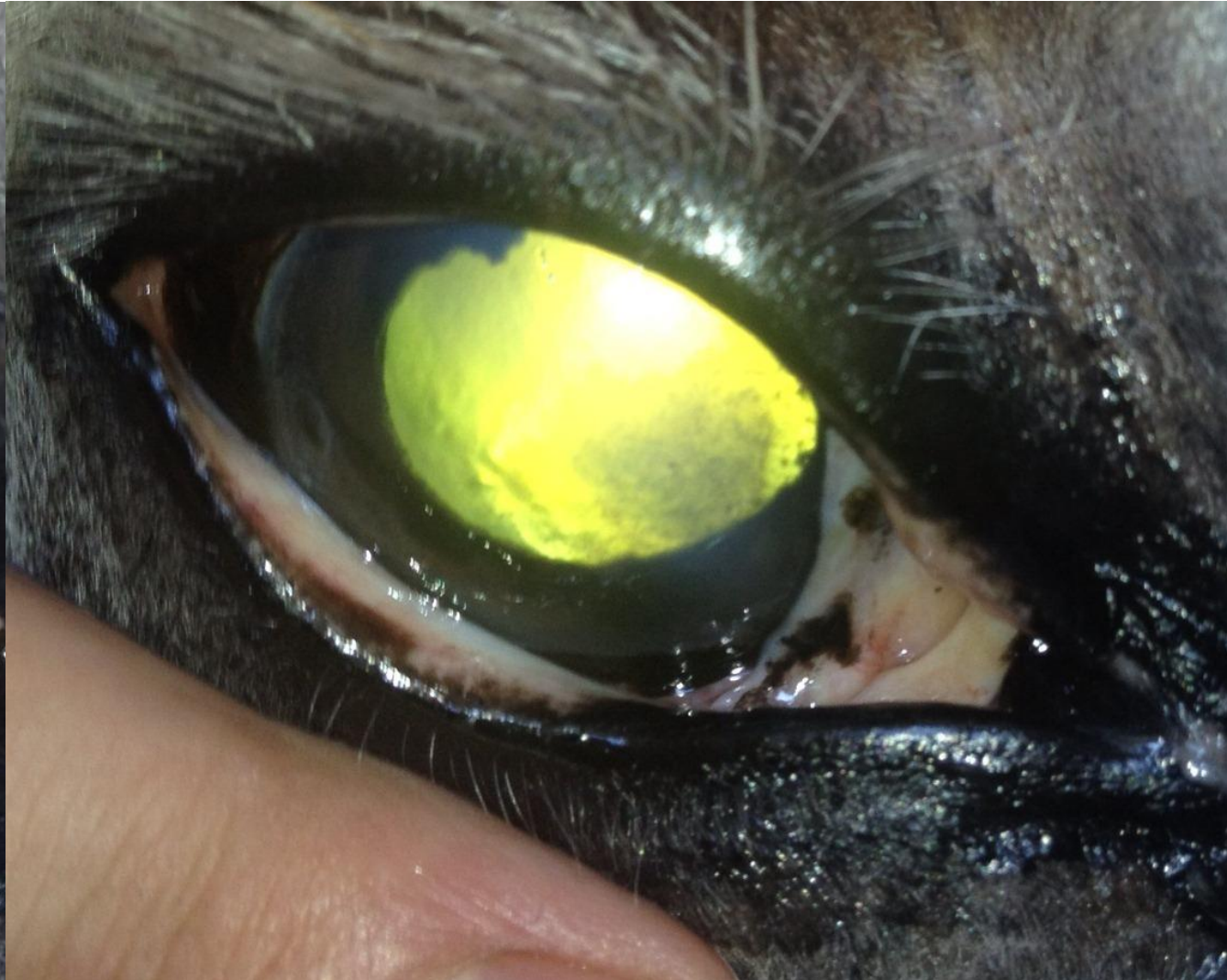
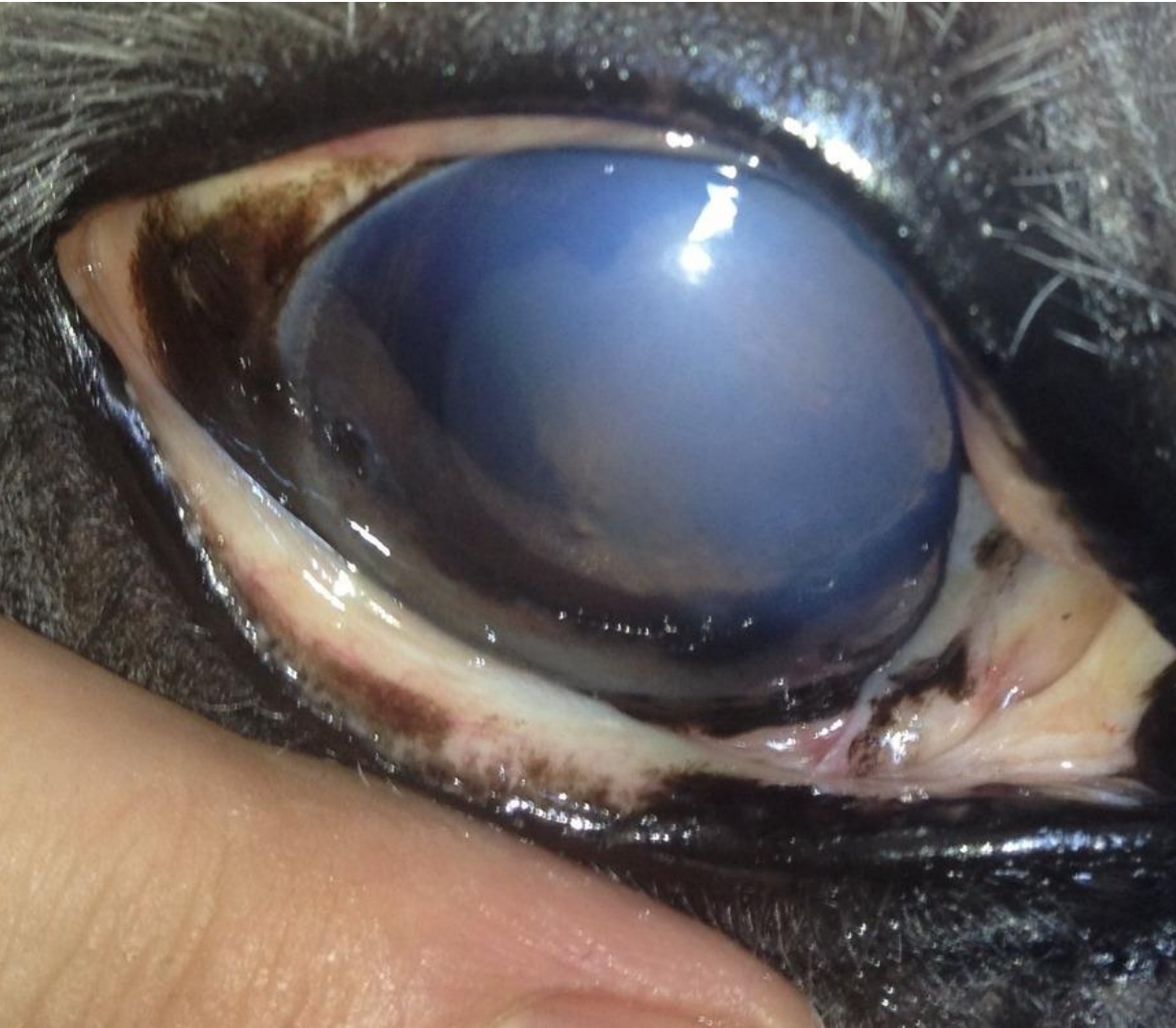
Opacities in the visual axis?



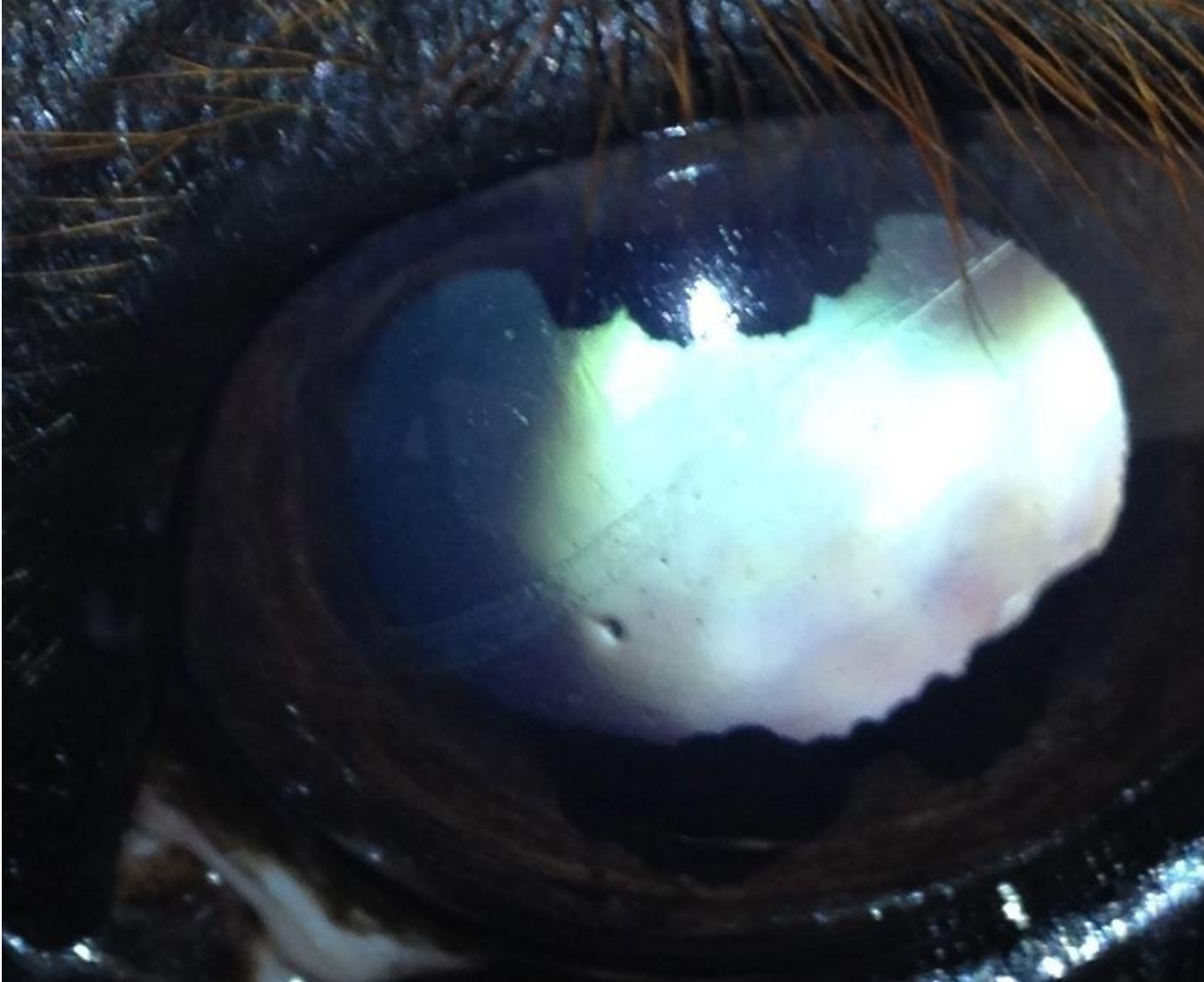
Opacities in the visual pathway:cornea




Opacities in the visual pathway: cornea




Opacities in the visual pathway: cornea



Opacities in the visual pathway: cornea



Simulating lens lesions: parallax

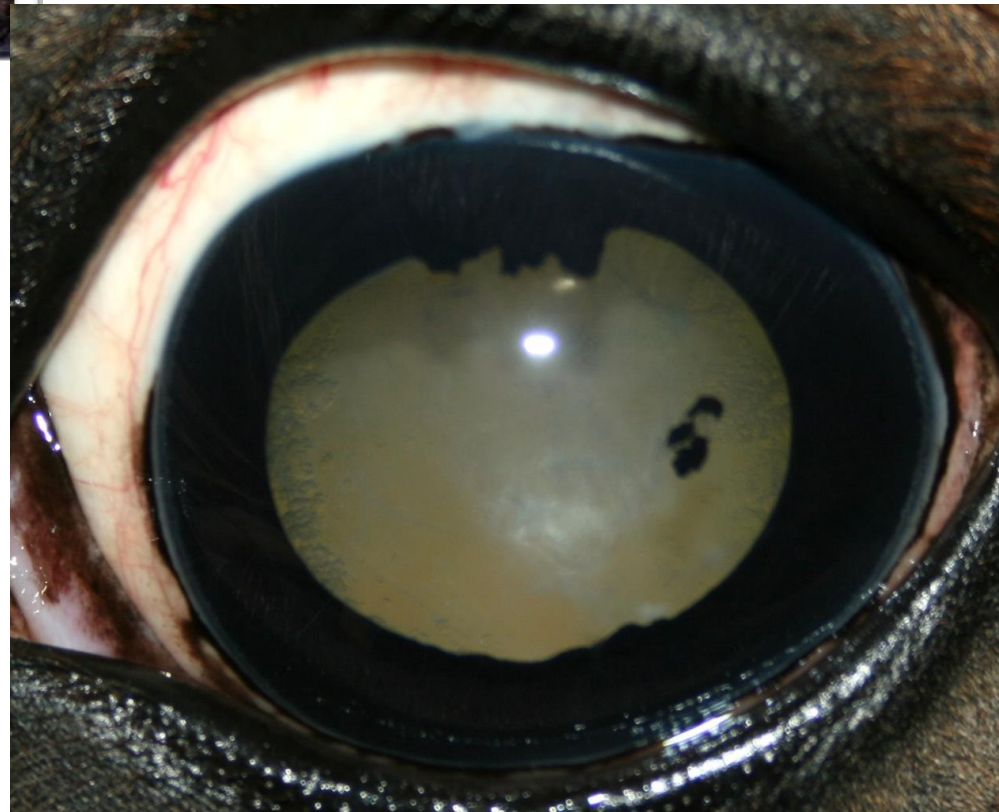


Interpreting lens lesions – an aside



Dendrochronology

Dendrochronology or tree-ring dating, is the scientific method of dating based on the analysis of patterns of tree rings, also known as growth rings. [Wikipedia](#)

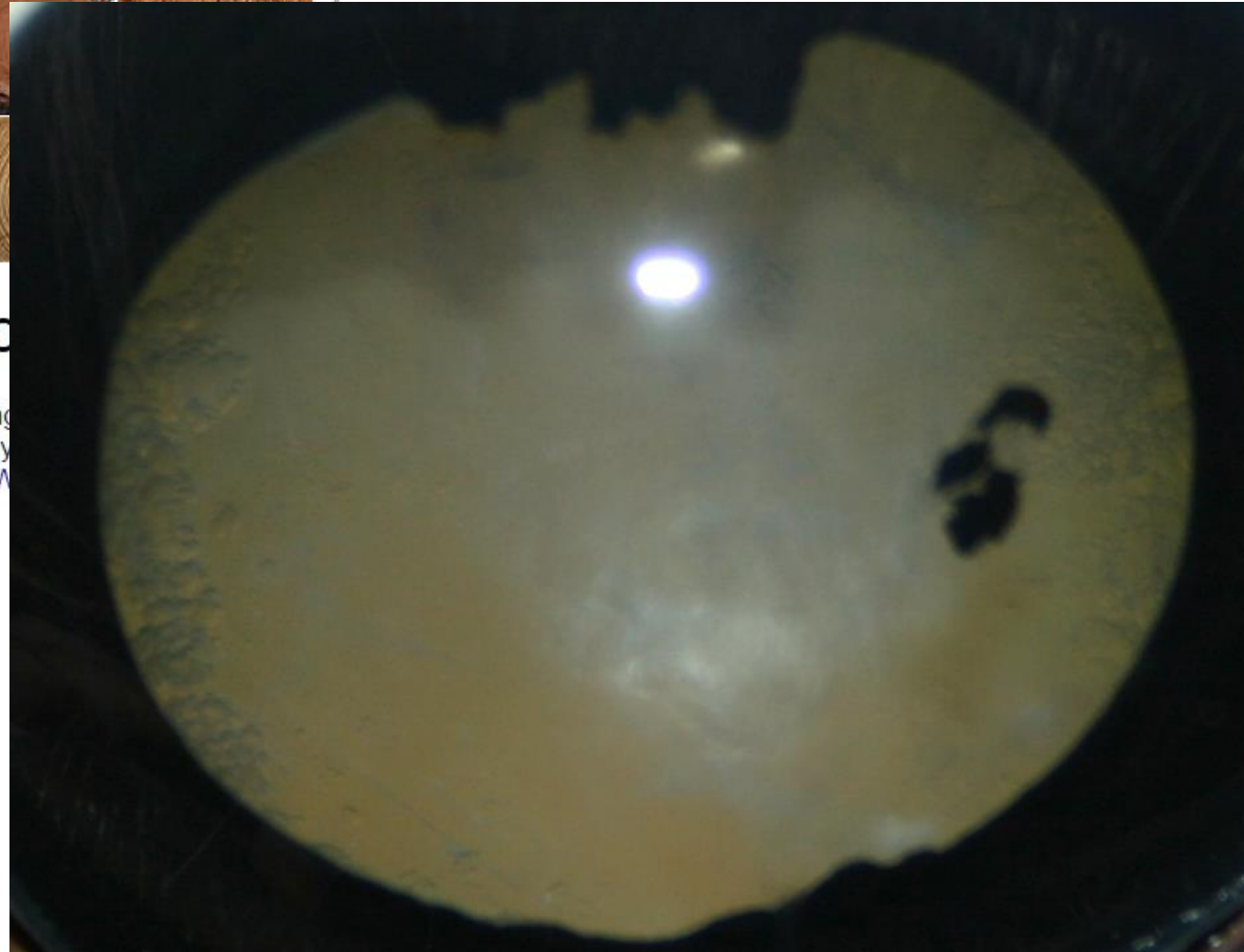


Interpreting lens lesions – an aside



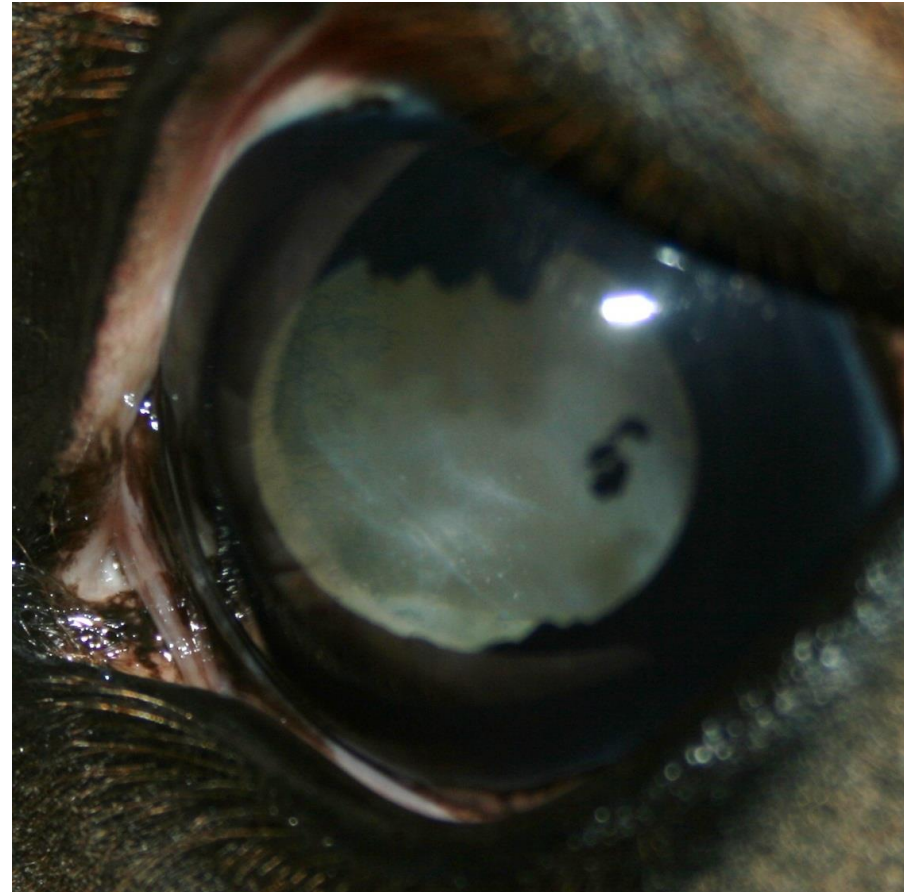Dendrochronolo

Dendrochronology or tree-ring dating is a method of dating based on the analysis of tree rings, also known as growth rings. W



Opacities outside the visual axis?

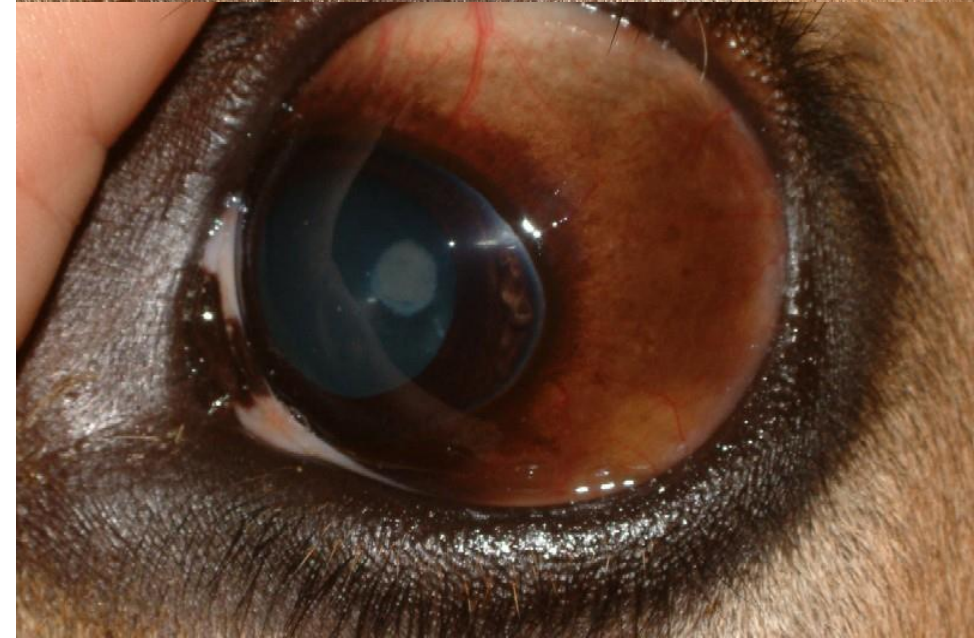
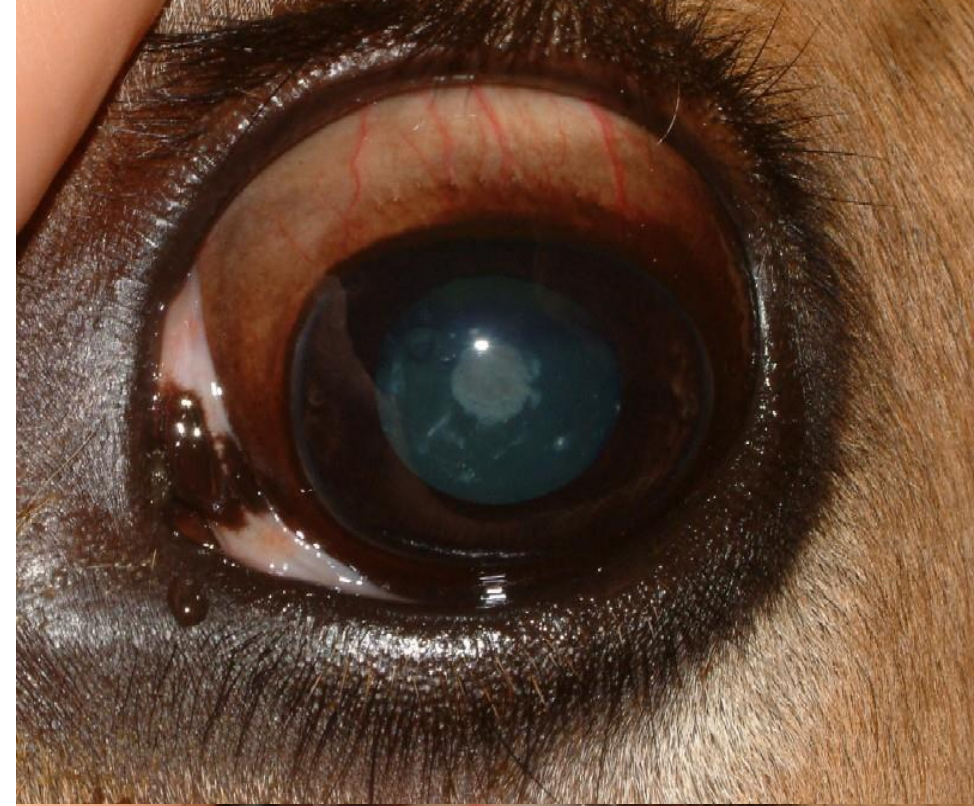- Aim to **visualise** opacities in :
 - Peripheral lens
 - Peripheral lens capsule
 - Ciliary body
 - Anterior peripheral vitreous
- Then aim to **localise** opacities using parallax



Opacities outside the visual axis?

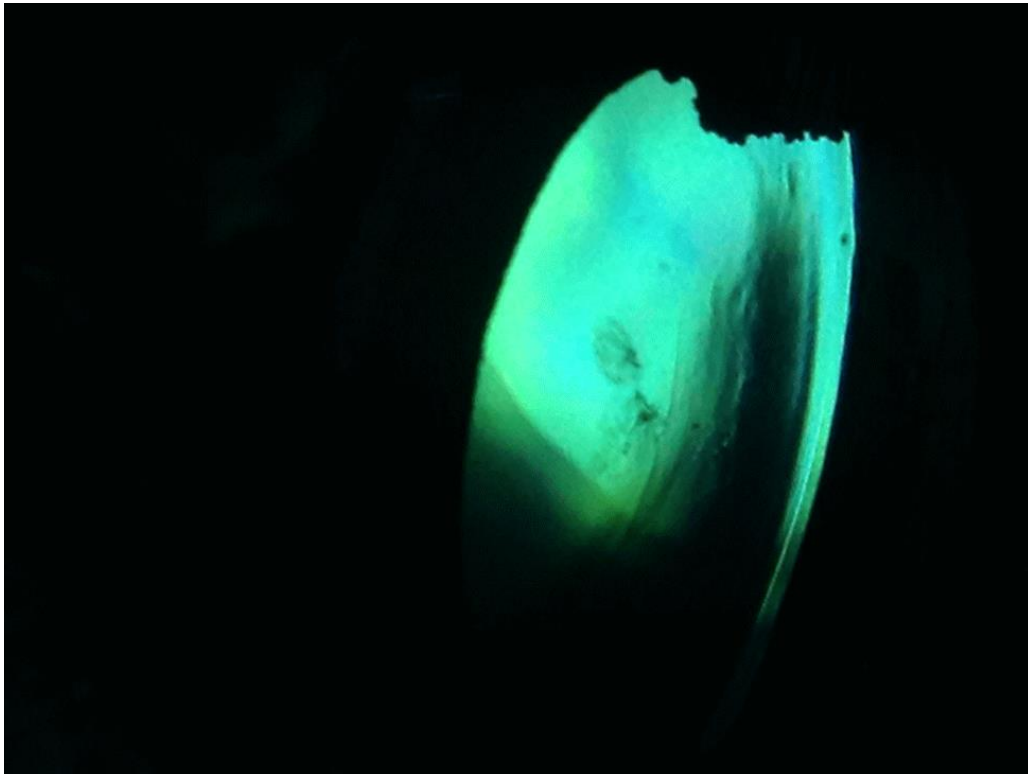
- Aim to **visualise** opacities in :
 - Peripheral lens
 - Peripheral lens capsule
 - Ciliary body
 - Anterior peripheral vitreous

- Then aim to **localise** opacities using parallax



Localising lens lesions

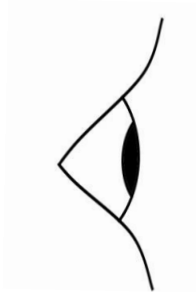Anterior lens lesion



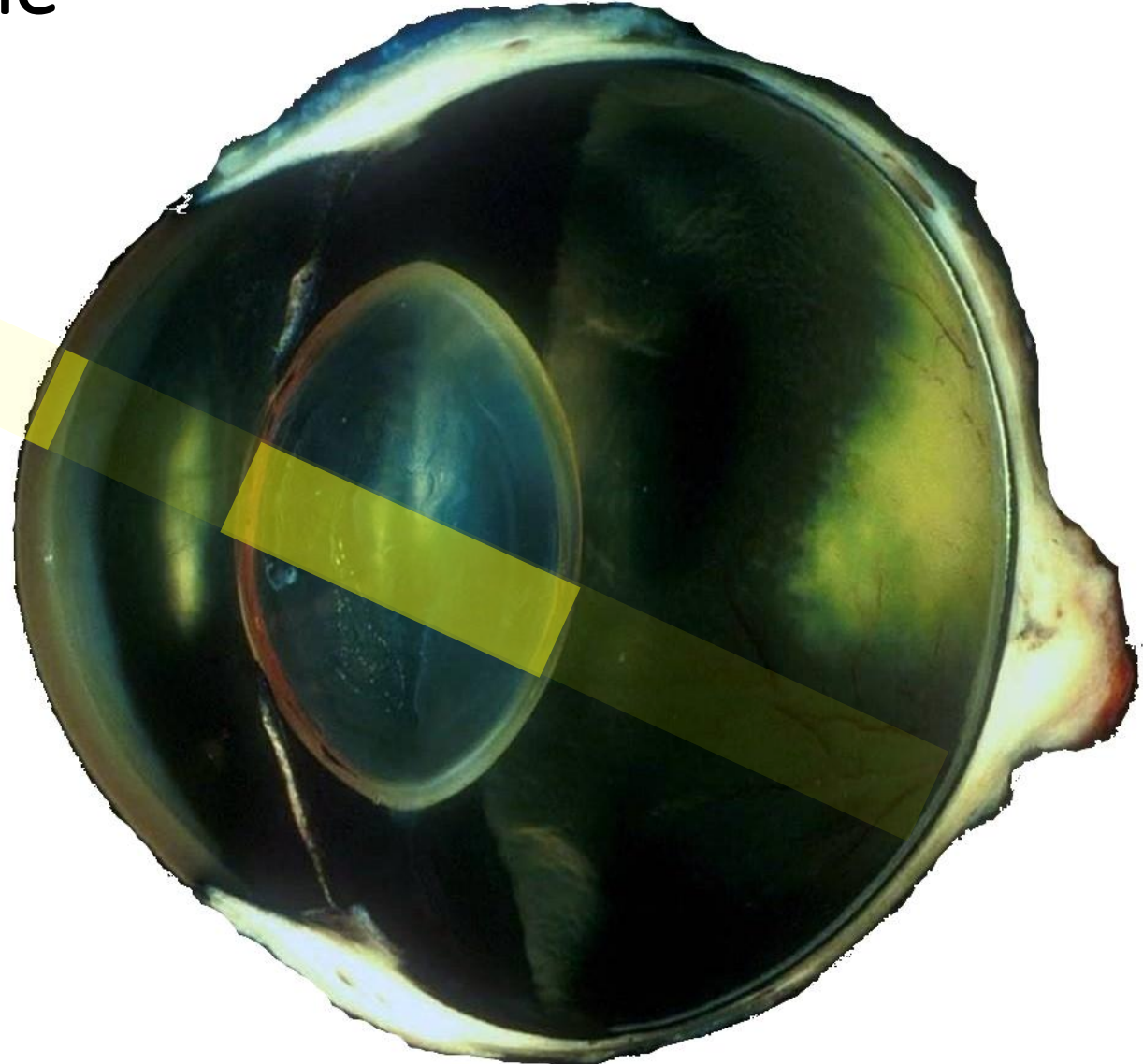
Posterior lens lesion



Localising lens lesions: the “search light technique”

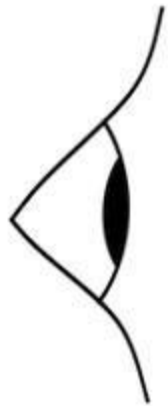

The use of purkinje reflexes, parallax and an obliquely directed focussed light can further allow localisation of lens lesions.



The optical section

Localising lens lesions: the “search light technique”

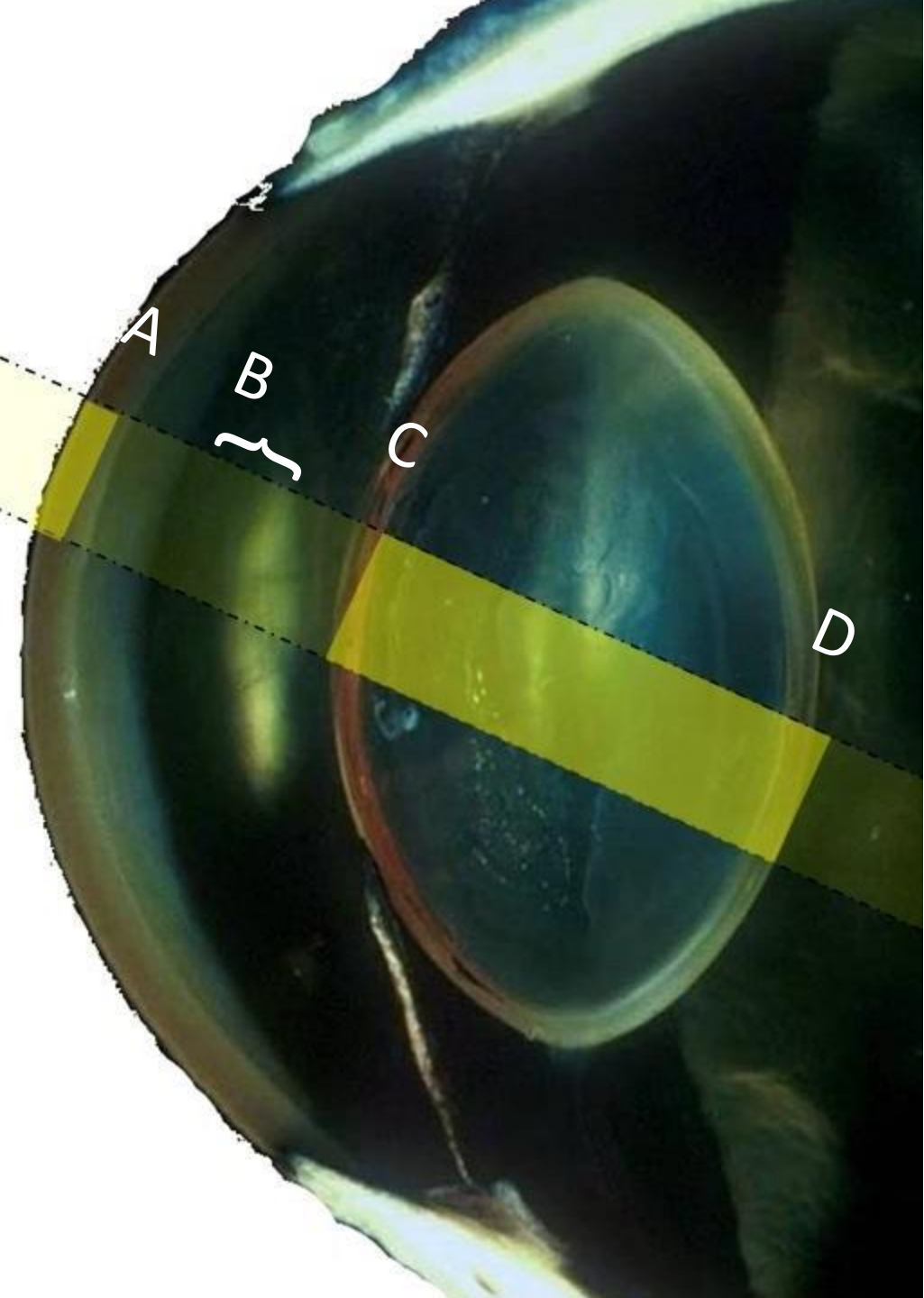


A Cornea

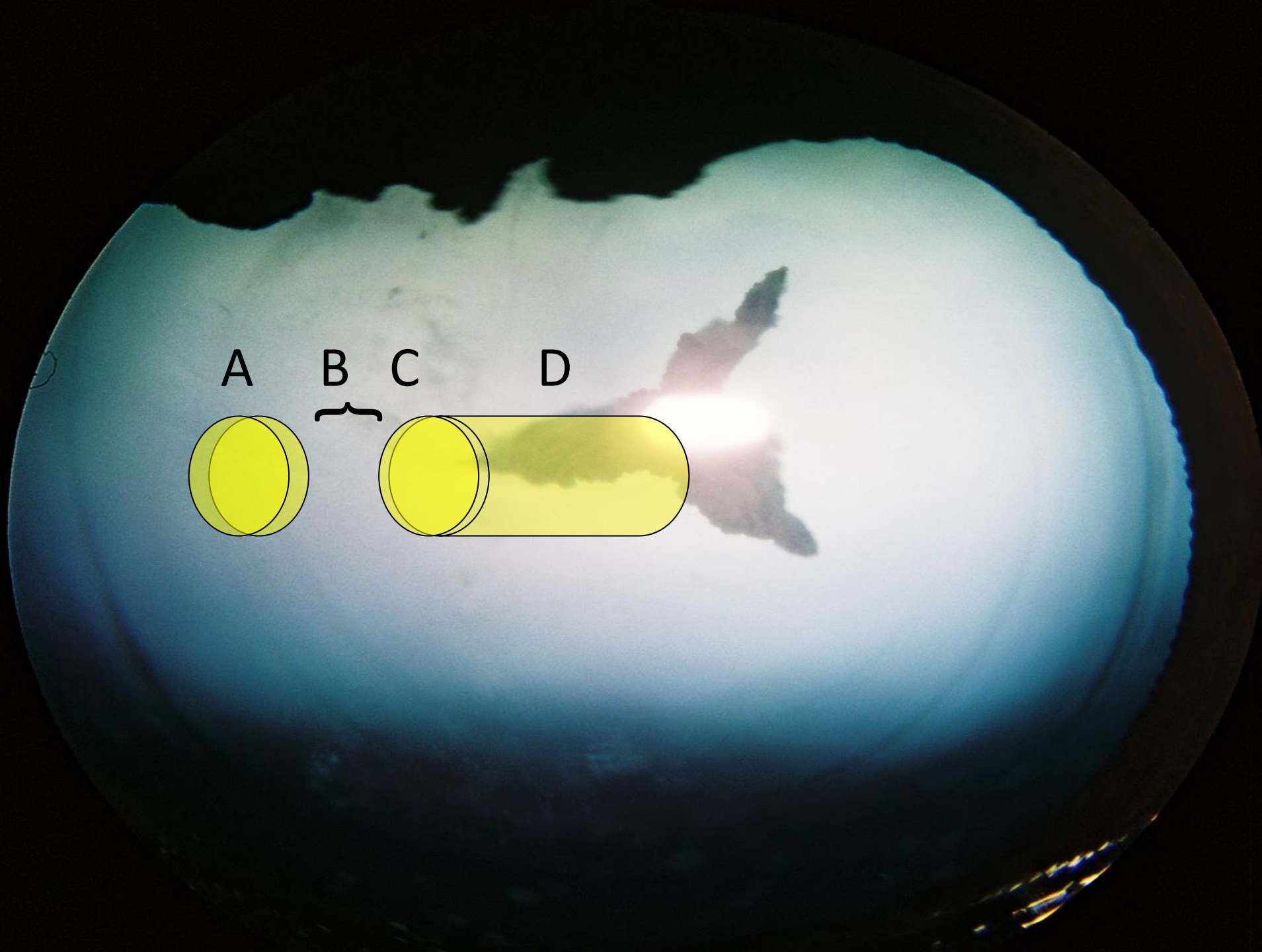
B Anterior chamber

C Anterior lens capsule

D Posterior lens capsule





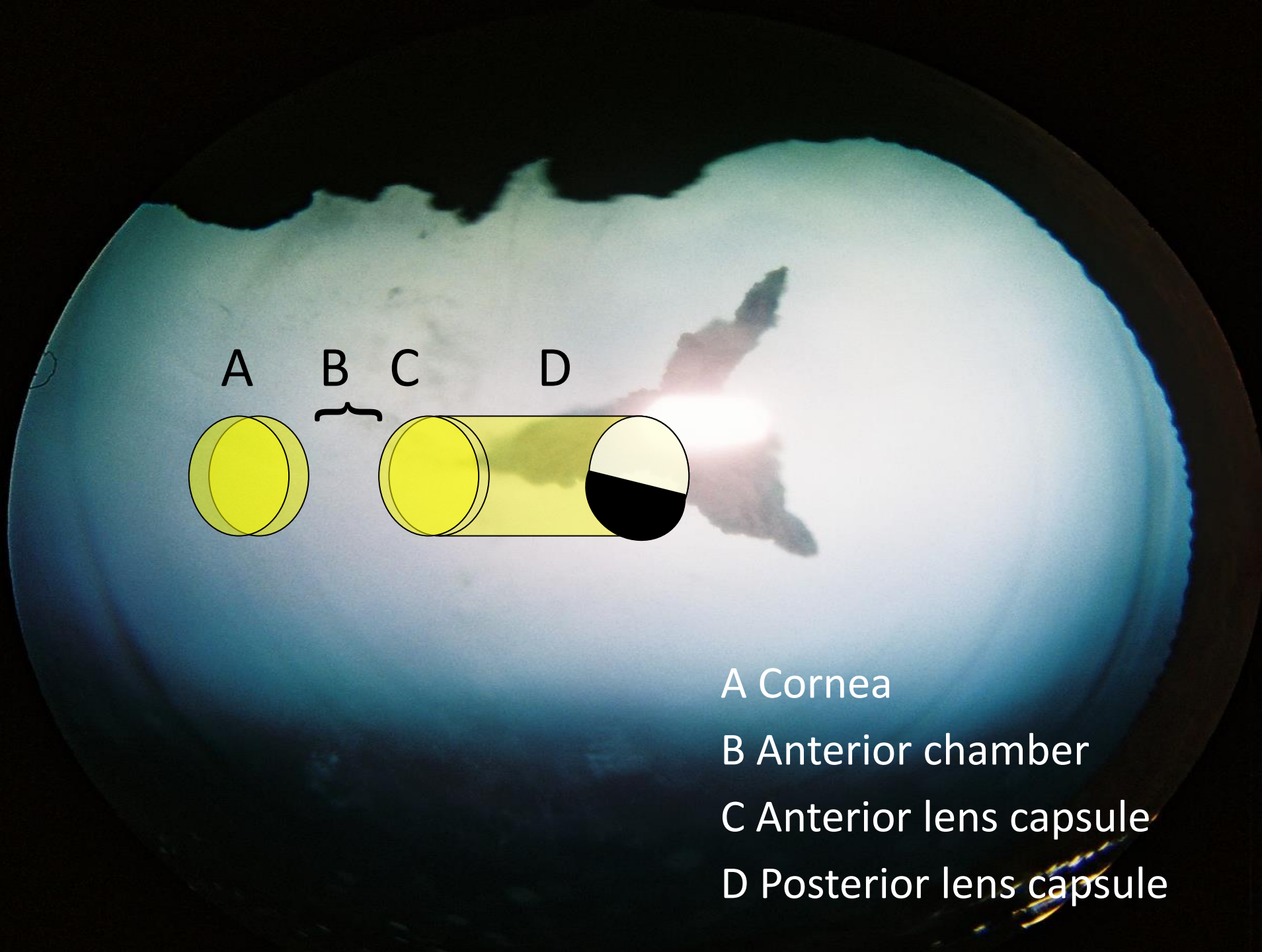


A

B

C

D



A

B

C

D

A Cornea

B Anterior chamber

C Anterior lens capsule

D Posterior lens capsule

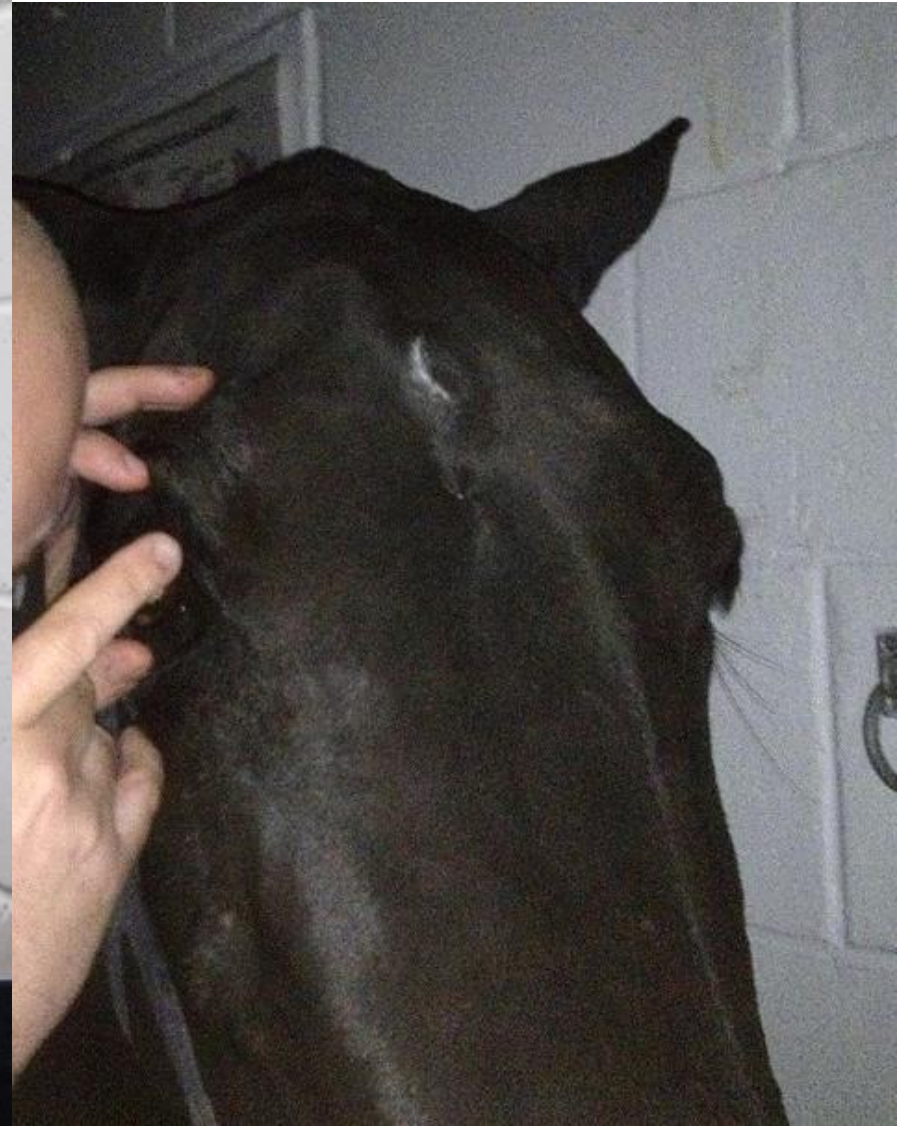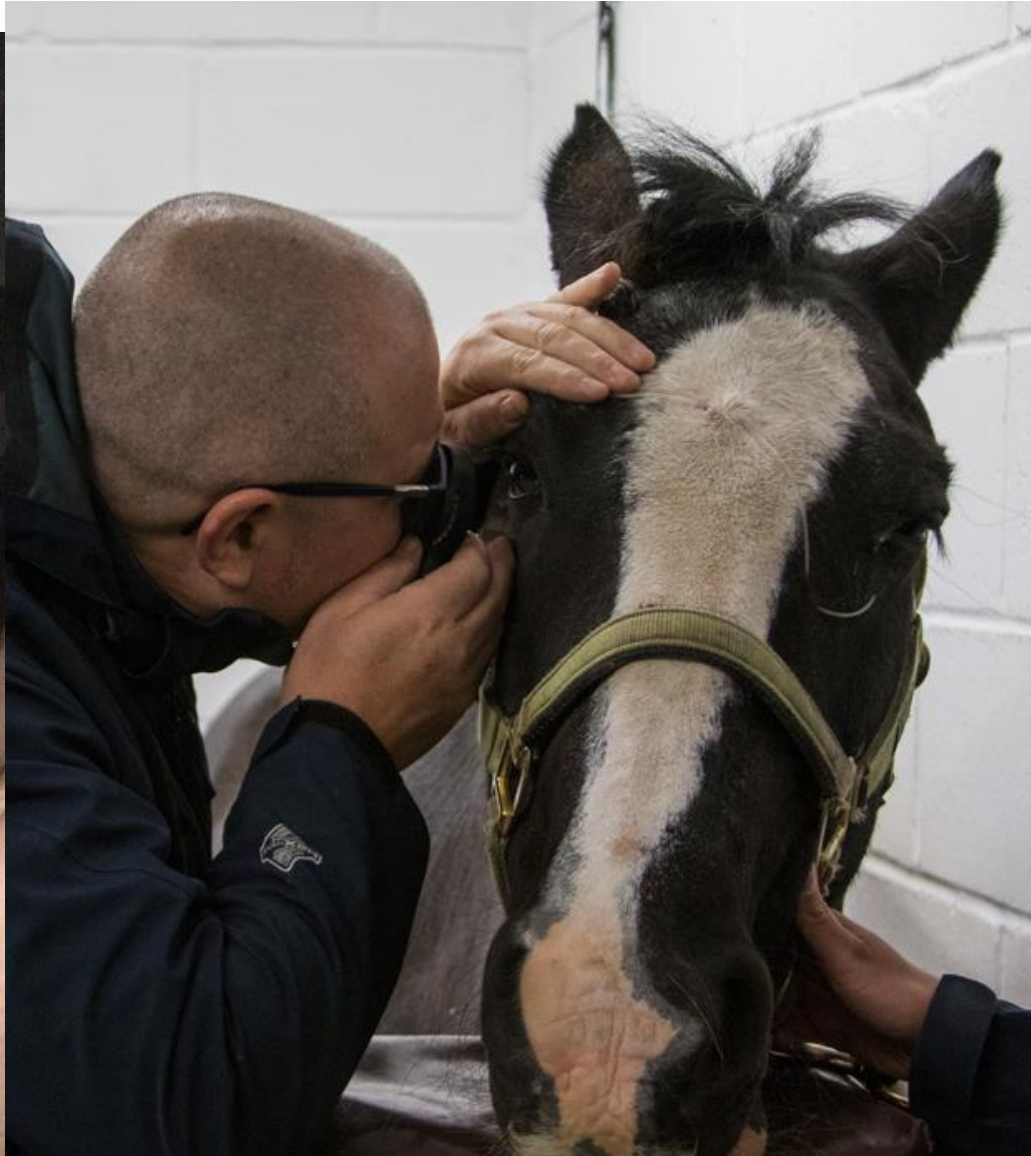Close direct: get close and wriggle about



Close direct: get close and wriggle about



Close direct: get close and wriggle about



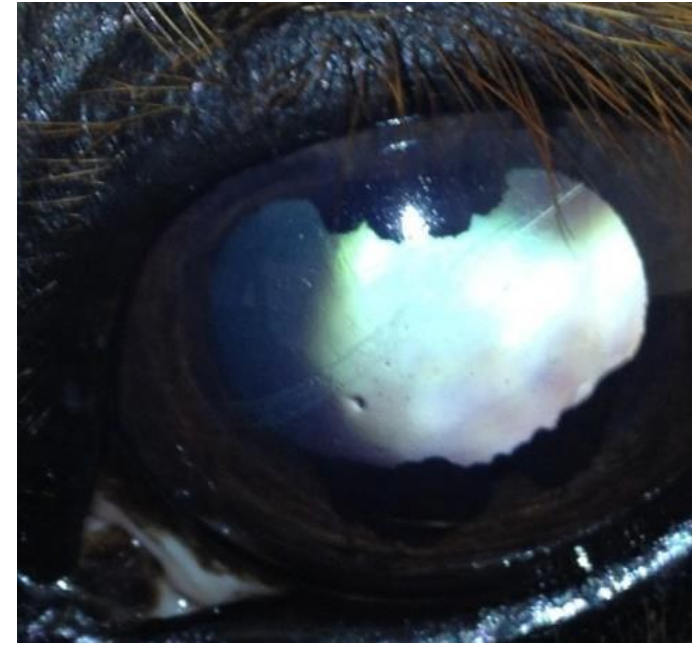
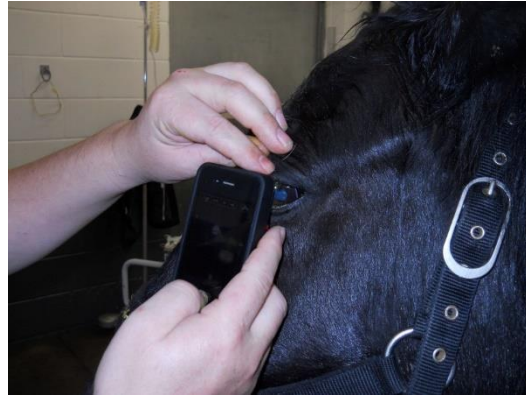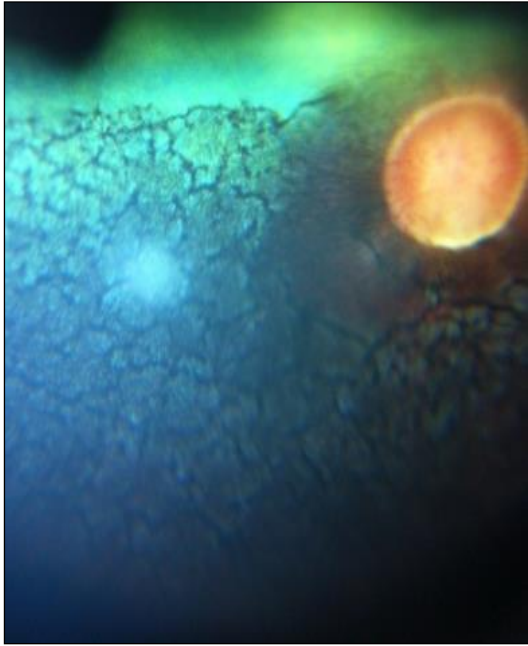
Equipment-“must haves”

- Direct ophthalmoscope
- Smart phone
 - With an app to allow easier ocular examination
 - “Phone a friend” number
- Head torch
 - Ideally with a rheostat e.g. LedLenser HR7
- Cotton buds, bacteriology swabs & slides
- Magnification
 - Smart phone macro lens
 - Loupes – “optivisor”
 - Reading glasses
- Small needles, tropicamide, local & fluroscein



Imaging the eye with your smart phone

- Distant direct ophthalmoscopy and direct visualization of the retina using close **direct ophthalmoscopy can be readily mimicked** using most smart phones with the correct camera application. More information is available at www.theeyephone.co.uk and www.equineeyeclinic.co.uk.
- Using a phone camera with a wide-angle lens allows us to directly image a wider retinal area than is achievable using a conventional direct ophthalmoscope. In many cases a direct view of the retina comparable to that previously only obtained using indirect ophthalmoscopy is possible.
The ideal camera phone for imaging the retina will have:
 - 1) a small Light to Lens (LL) distance
 - 2) the lens positioned near the corner of the phone.
 - 3) have a light whose illumination can be varied
 - 4) has a lens with a wide angle.
- **With the addition of readily available macro lens adaptors magnified views of the lids, ocular surface, iris and lens can be obtained.**

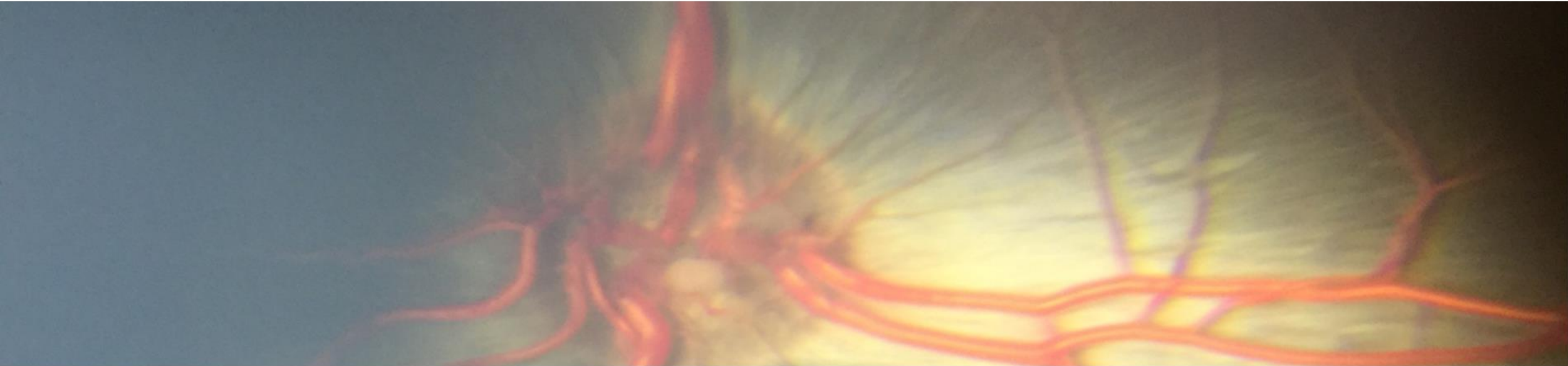


Direct “phoneoscopy”

How to mimic *close* and *distant* direct ophthalmoscopy with a smart phone camera...

THE "EYE" PHONE - EXPLORING THE ART OF PHONESCOPY

- HOME
- ABOUT
- CONTACT
- TRAINING EYES
- HOW TO IMAGE THE...
- WHICH CAMERA PHONE?
- WHAT APP?
- CLOUD STORAGE



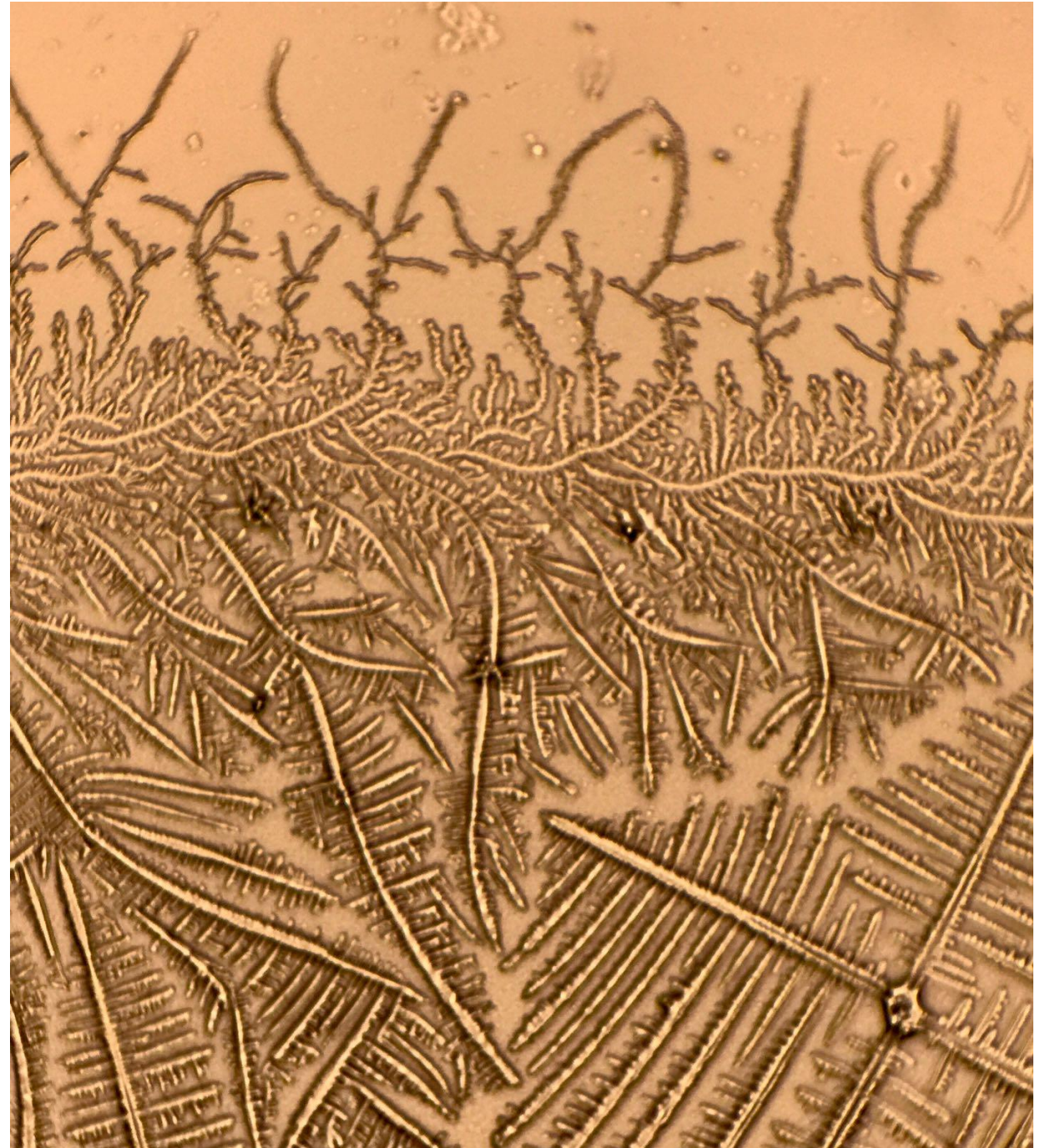
The art of phoneoscopy - using the smart phone to image the eye.

WELCOME to the home of phoneoscopy.

Imaging the eye well allows us to educate others and ourselves, document pathology and to share the beautiful and the unusual. This site is dedicated to making this easier than ever to achieve.

Check out our practice face book pages where we try to share cases at:

Don't forget your
microscope

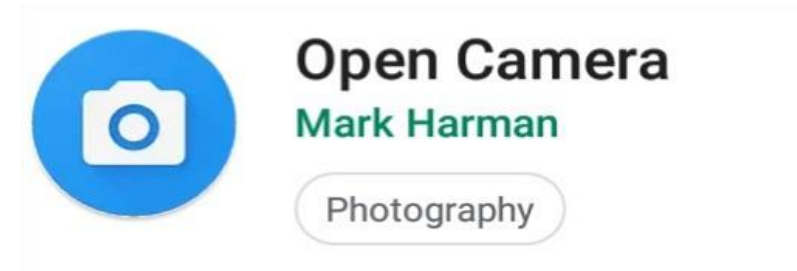


Apps: Must have light on all the time

Apple/iOS




Android



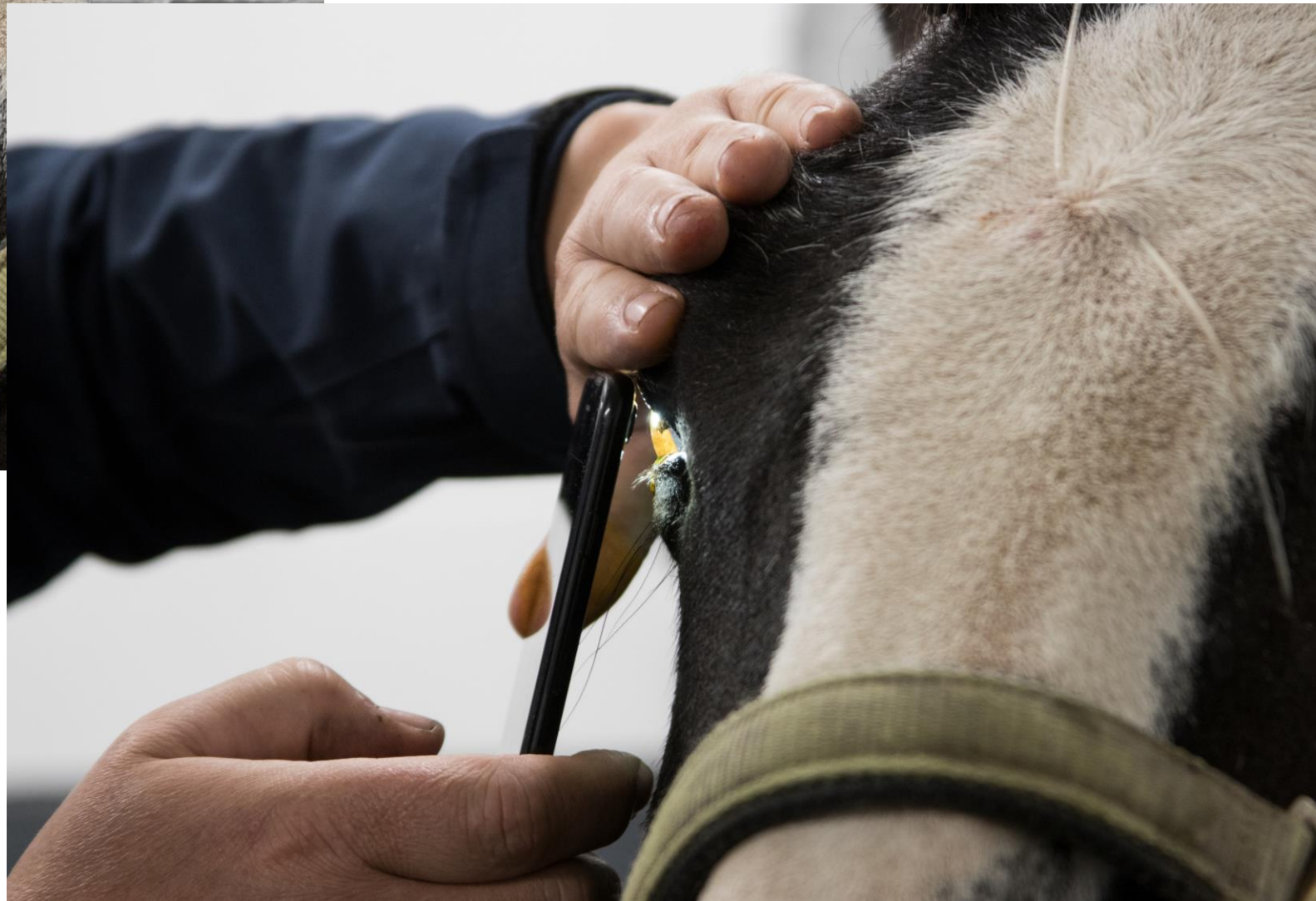www.TheEyePhone.com for links

Diffuser and/or an app to dim the light

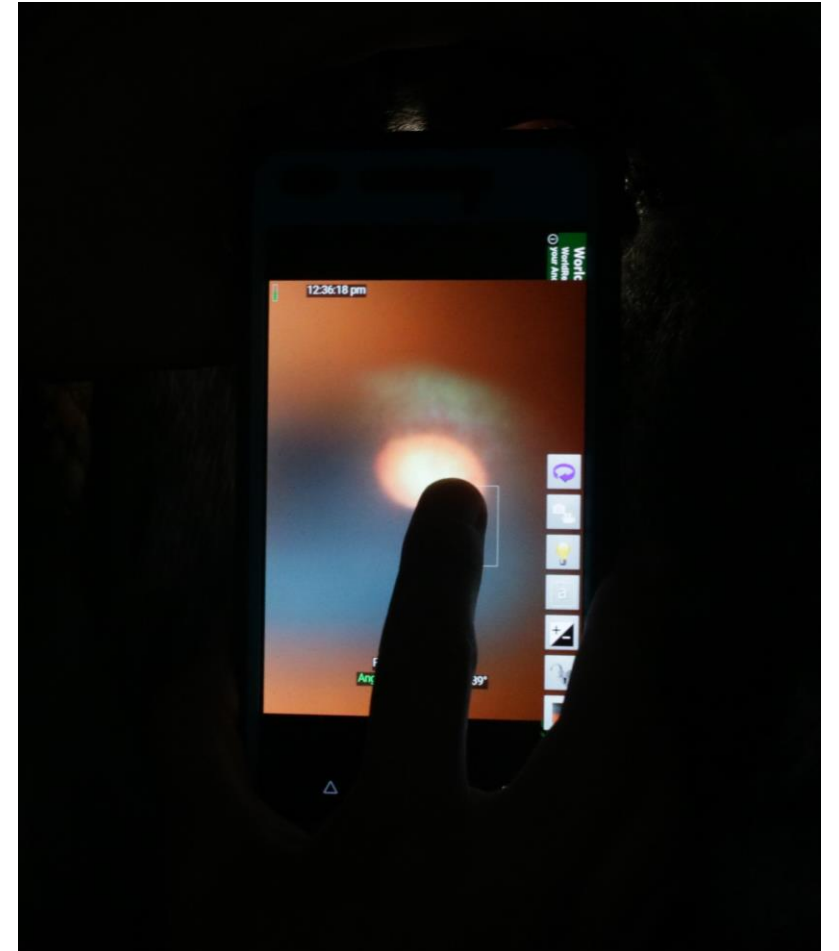


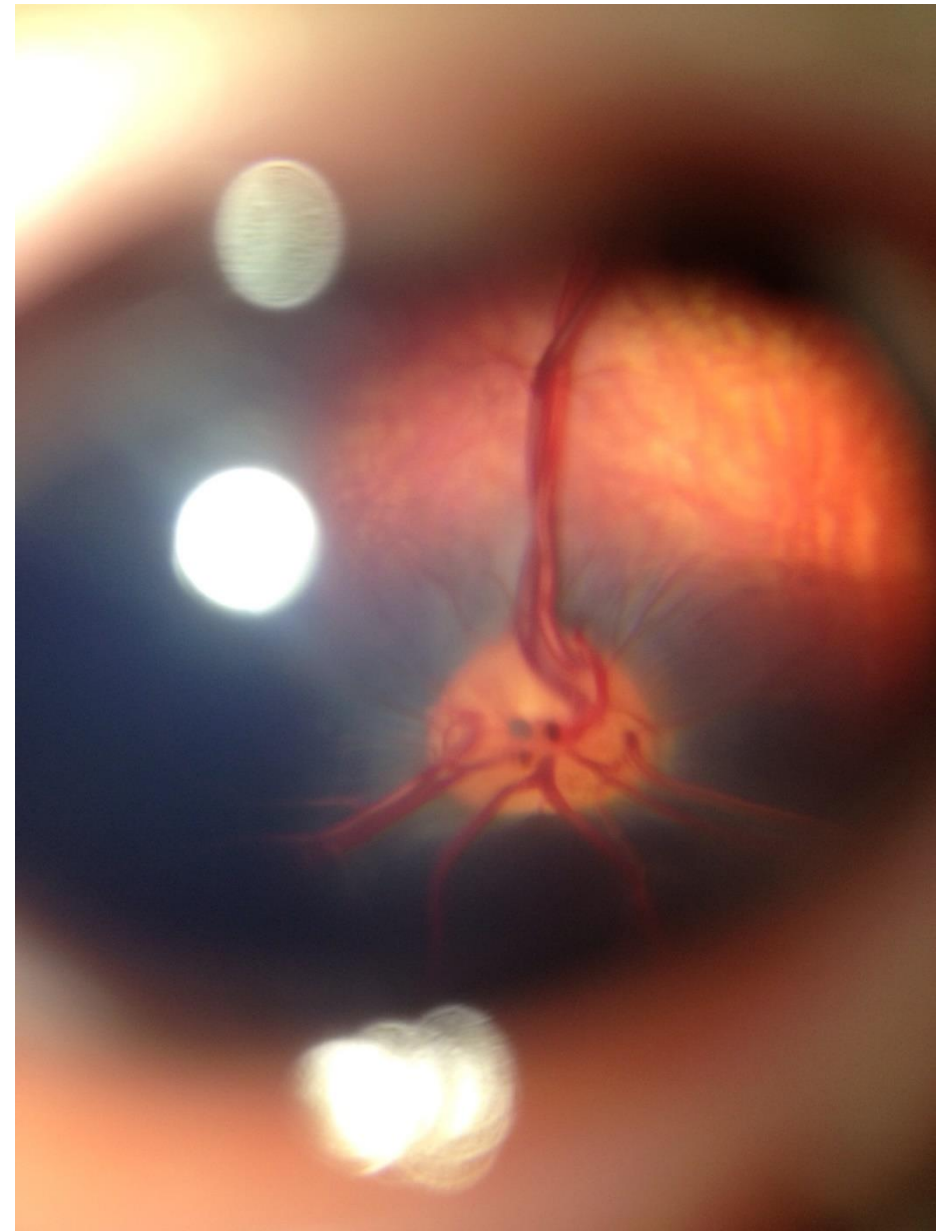
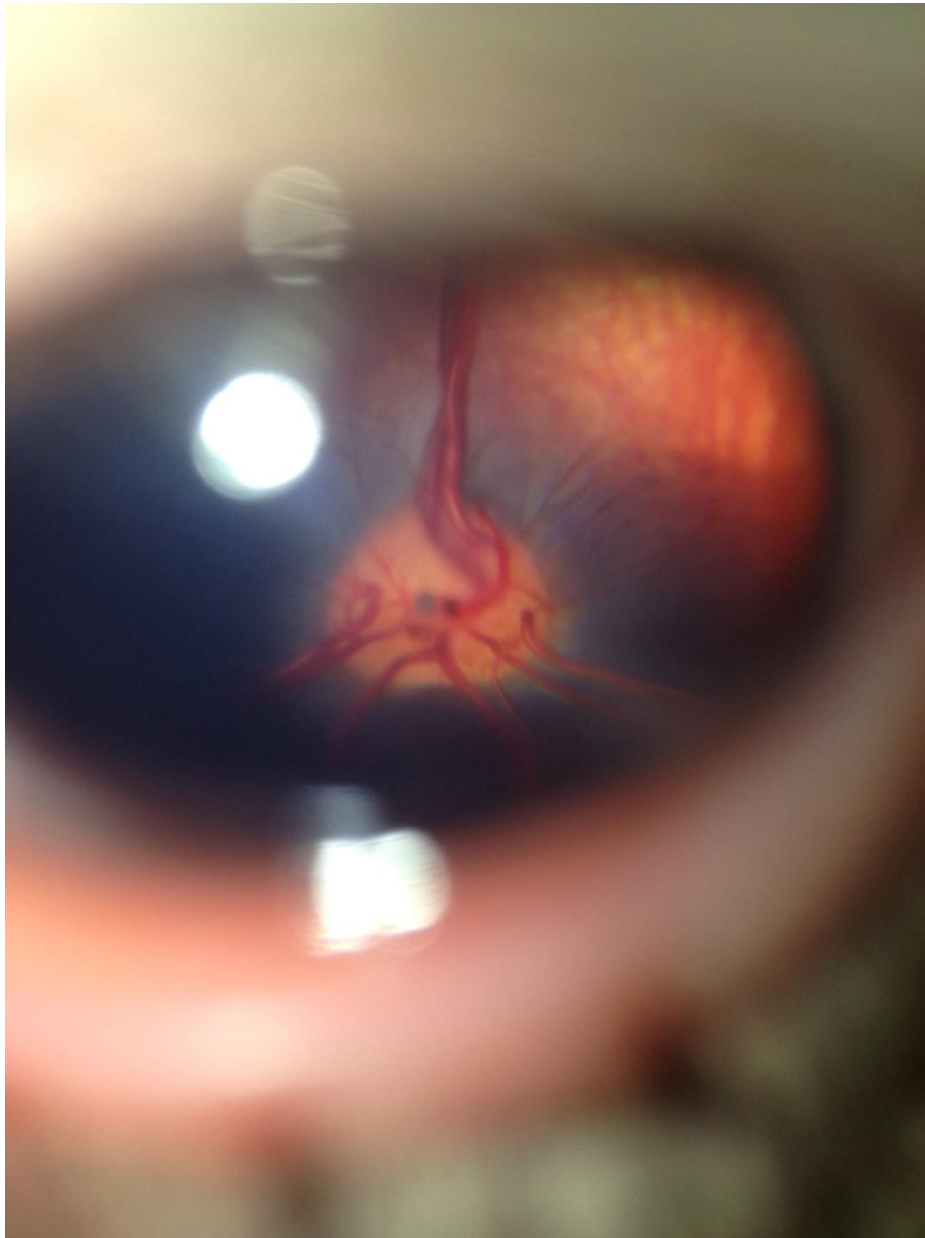

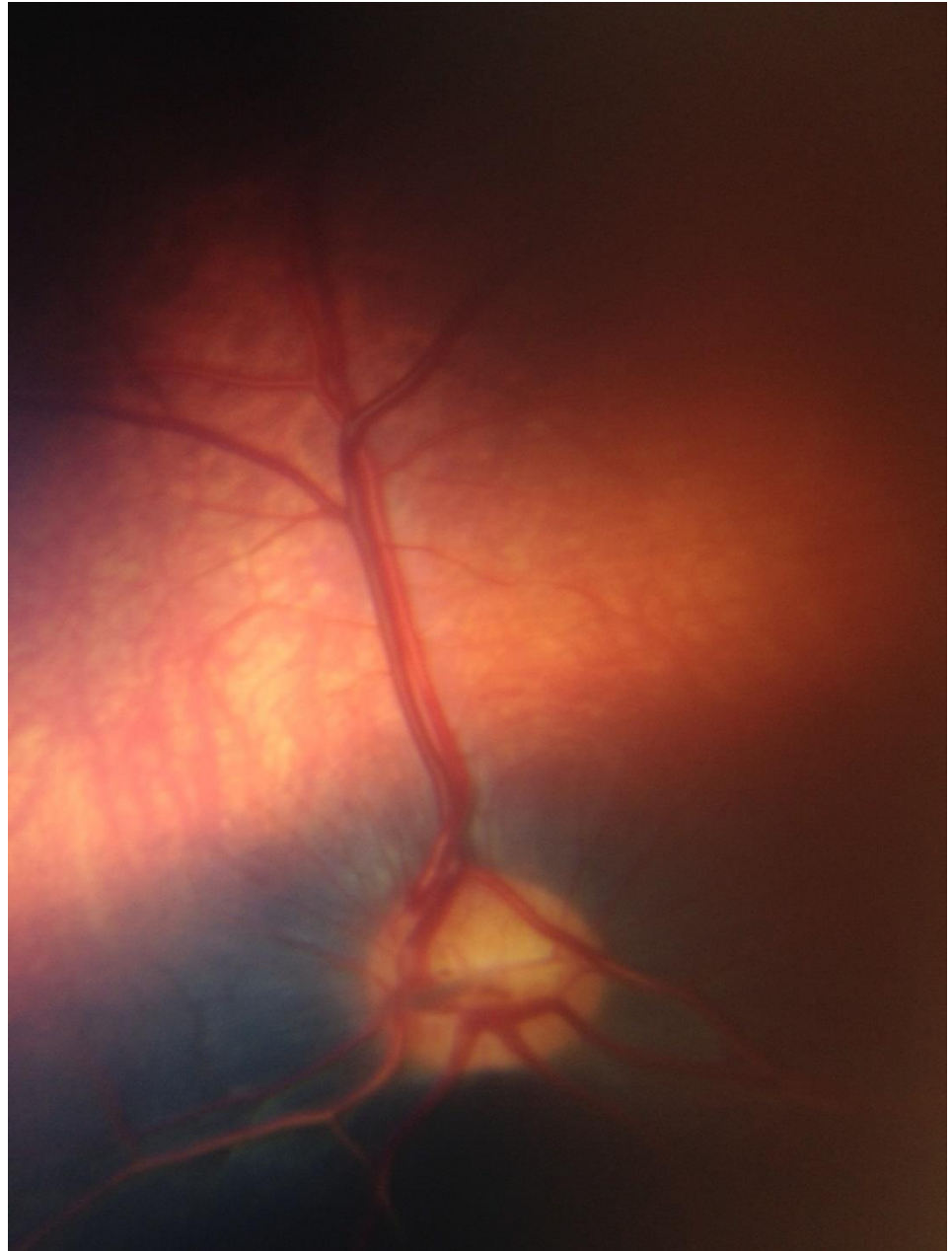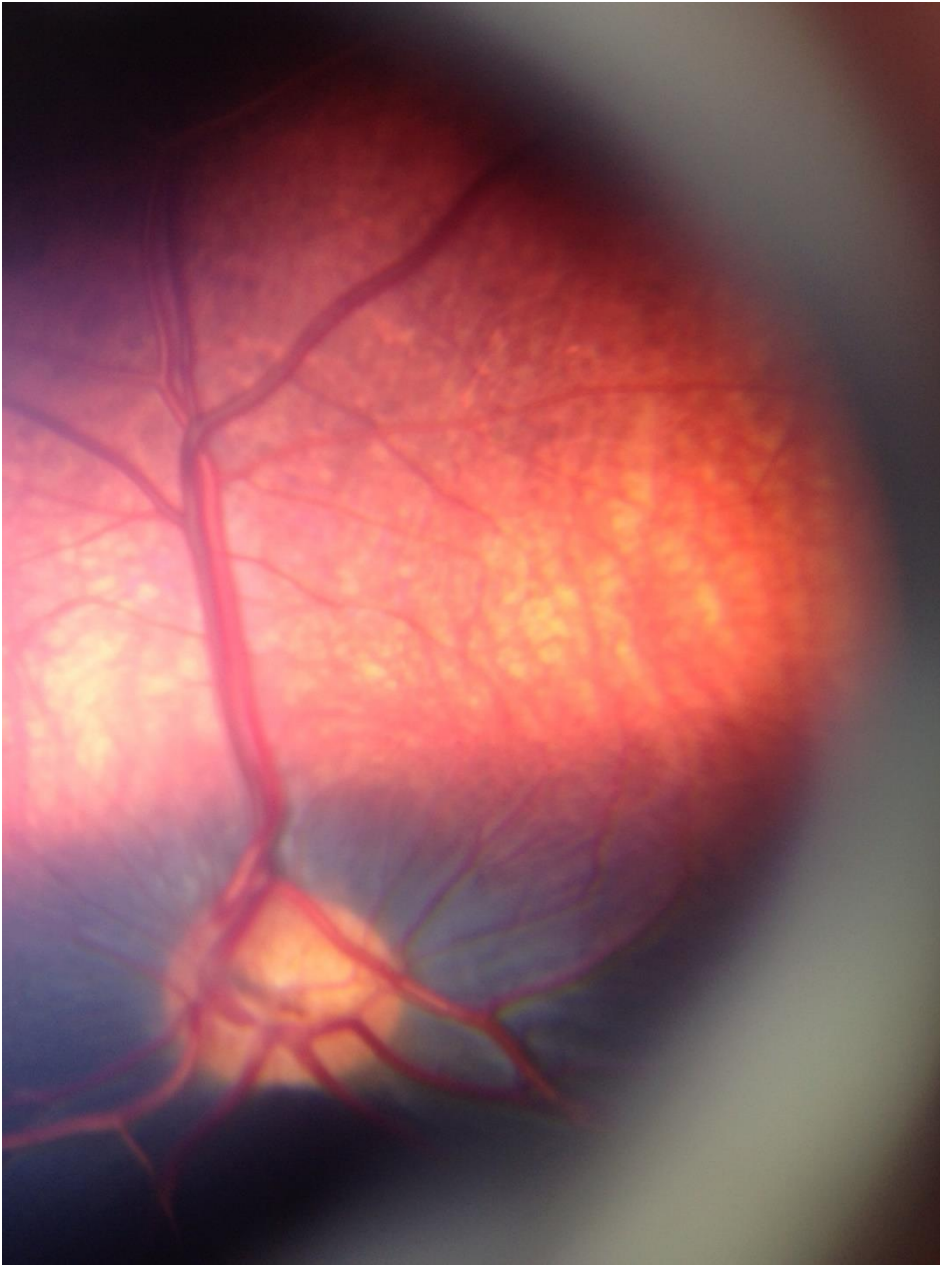
www.theeyephone.com



www.theeyephone.com

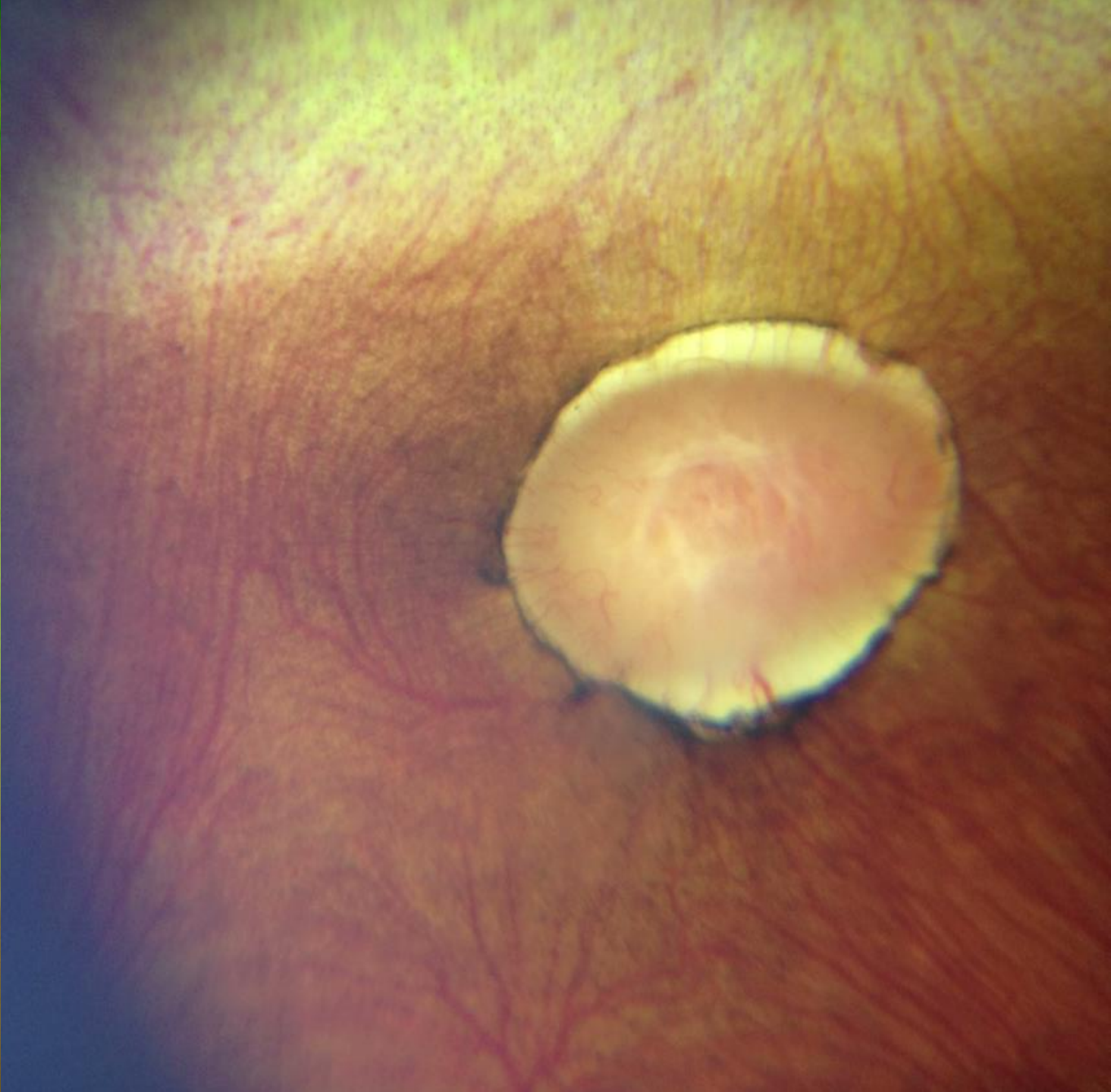
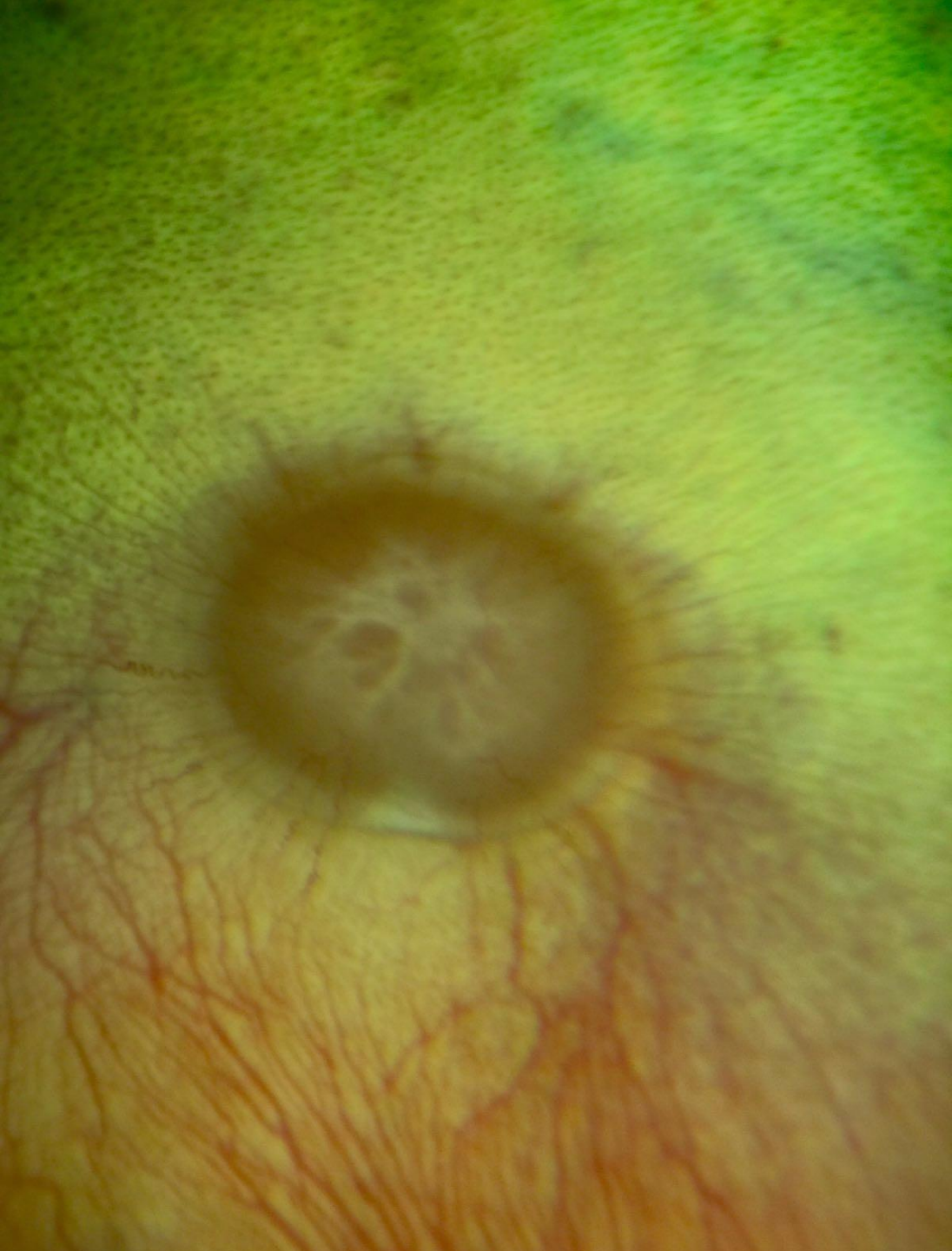


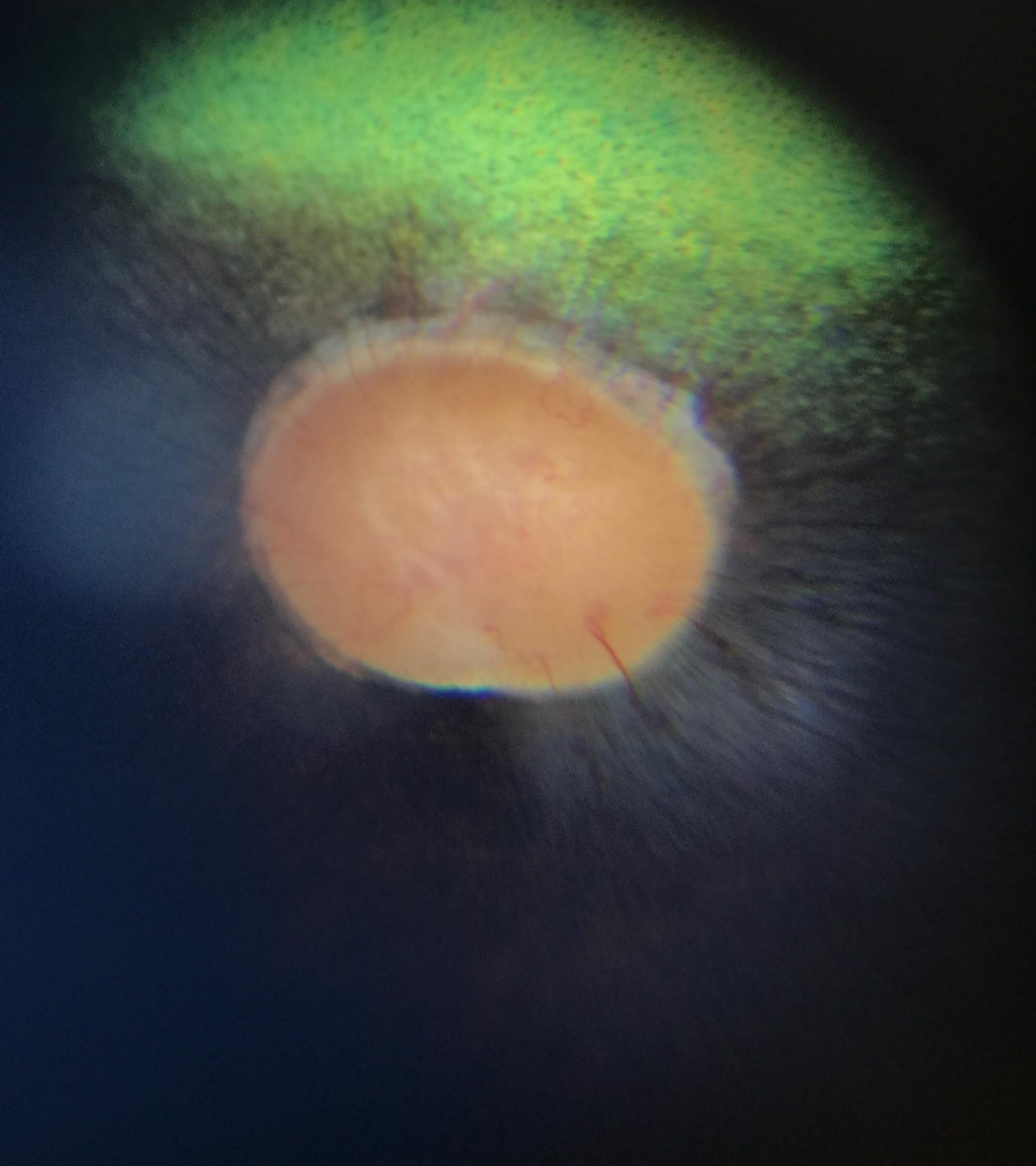
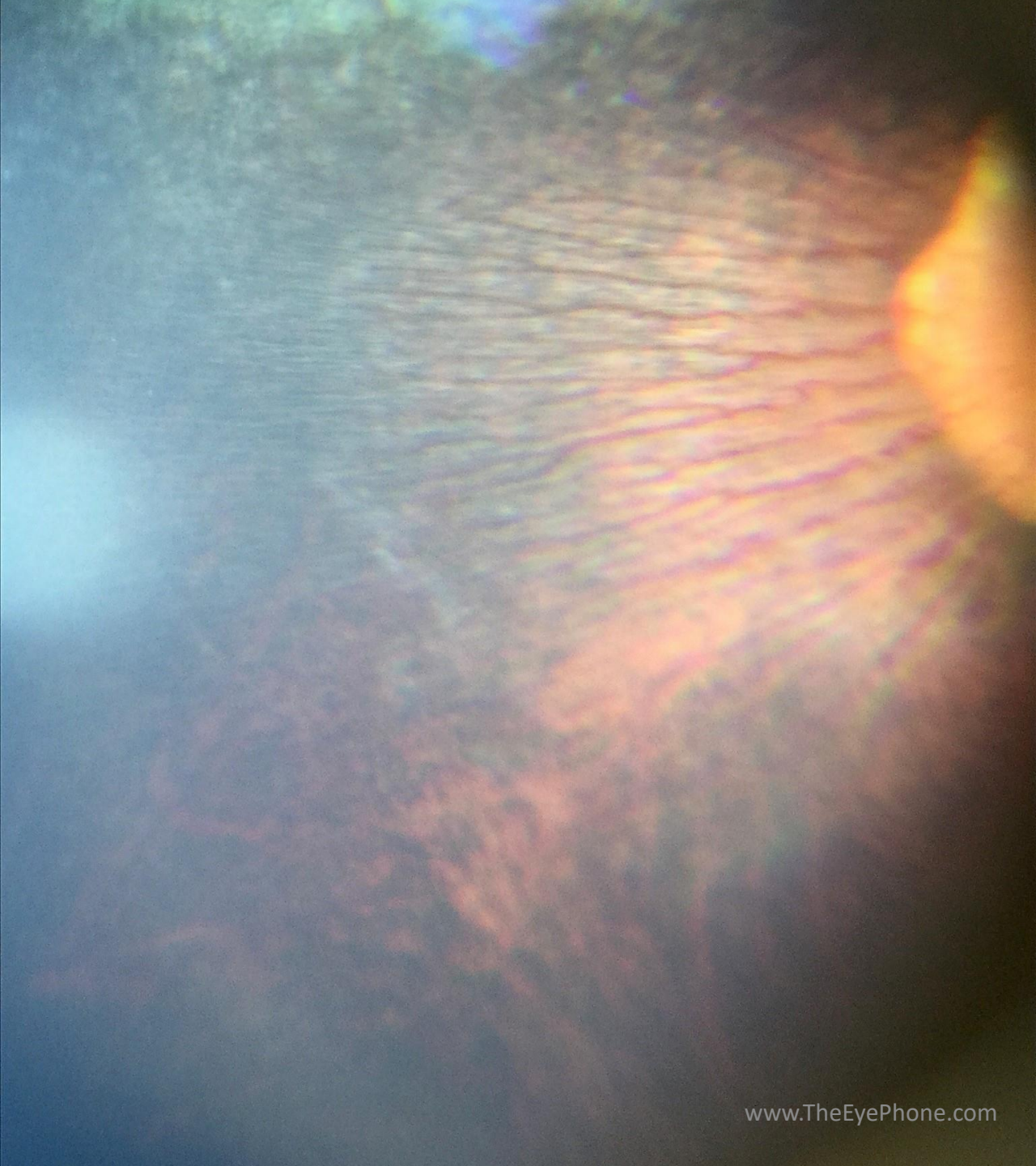




Direct phoneoscopy – a step by step guide:

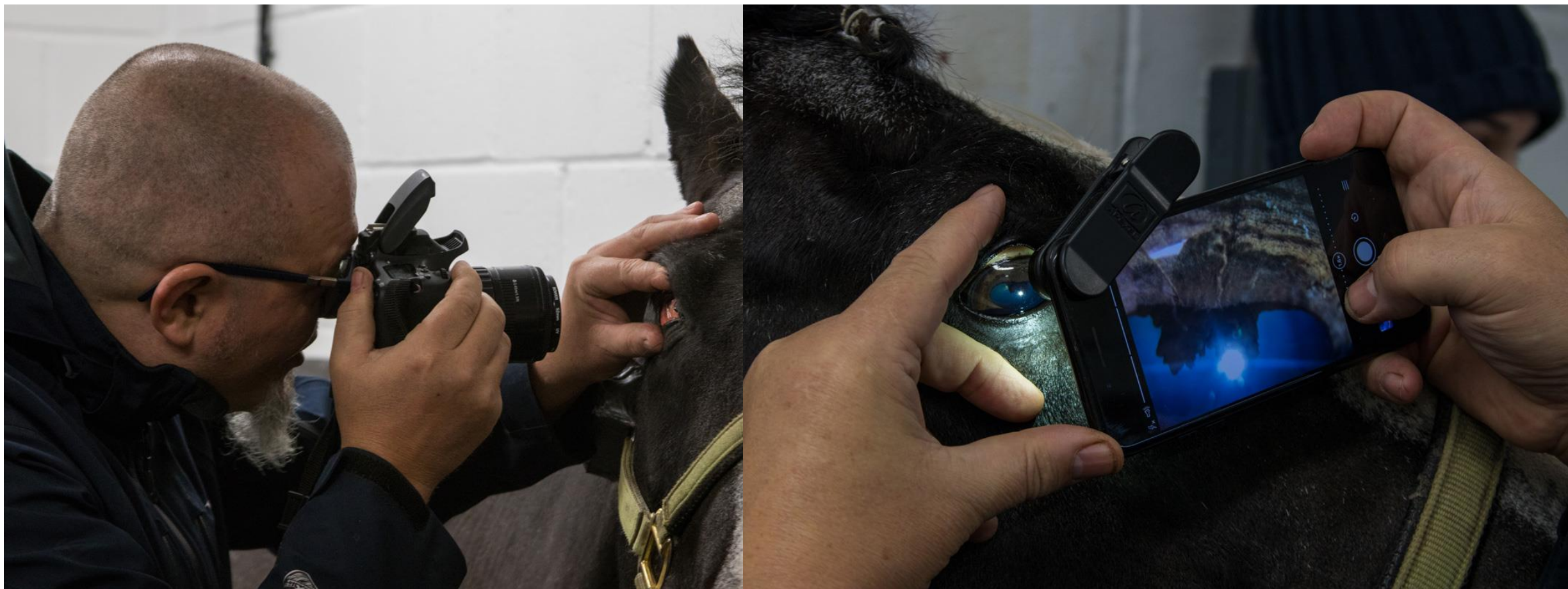
- Mydriasis is helpful but not always essential especially if using a phone with a short Light to lens distance.
- Open camera app – see the “Which App” section on www.theeyephone.com if you don’t already have a suitable app installed
- Turn the LED on continuously – if you do not have a suitable app installed use your embedded video app and turn the light on.
- Reduce the LED illumination – if this can not be done within the app then apply multiple (3) layers of micropore tape or similar to the LED.
- Image the tapetal reflection from arm’s length- the distant direct ophthalmoscopy technique can be mimicked in this fashion. Zoom in until the tapetal reflection fills the screen.
- Zoom out again prior to imaging the retina.
- Move the camera towards the eye – when the eye is closer than the camera’s minimum focal distance the retina will start to be imaged.
- Position the camera close to the cornea (2-5mm) in the same way you would position a direct ophthalmoscope when performing close direct ophthalmoscopy. Removing your camera case will make this easier.
- Tap the screen to focus on the optic nerve head.
- If your app allows separate focus and exposure (e.g. Camera +) then tap the tapetal fundus to avoid “white out” due to the highly reflective tapetum.
- Reposition the exposure on the non-tapetal fundus to image.







Smart phone macrophotography

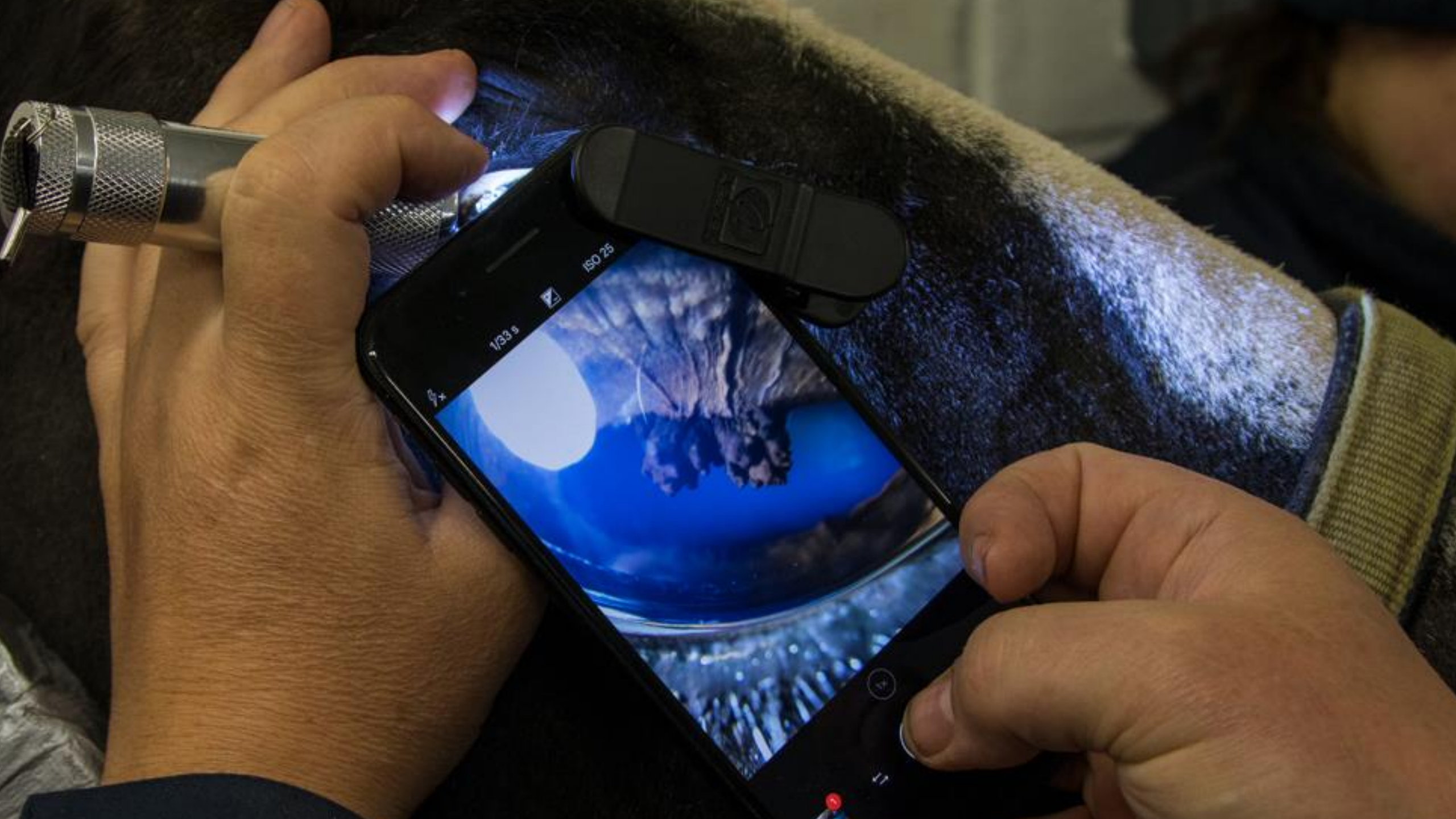




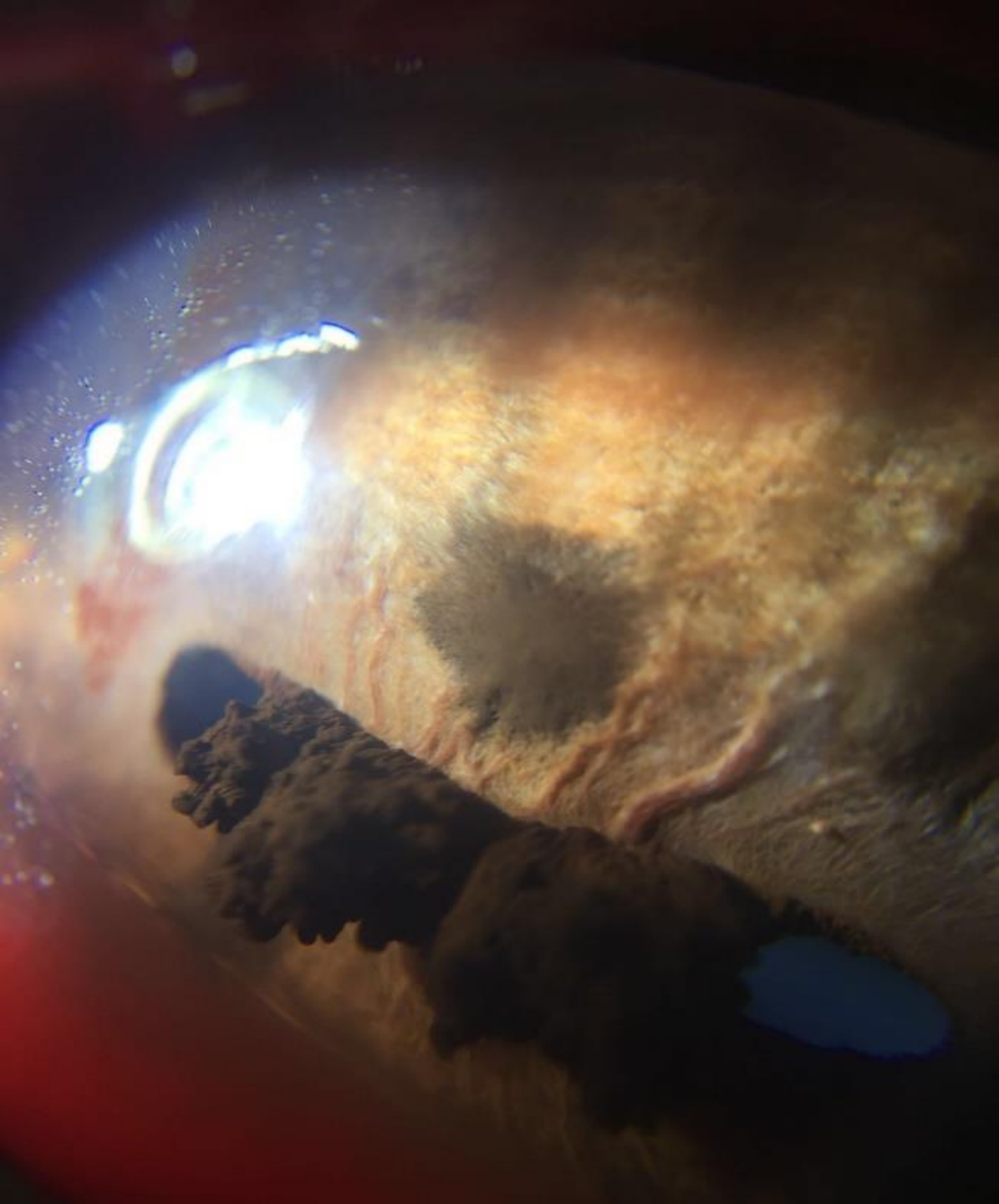


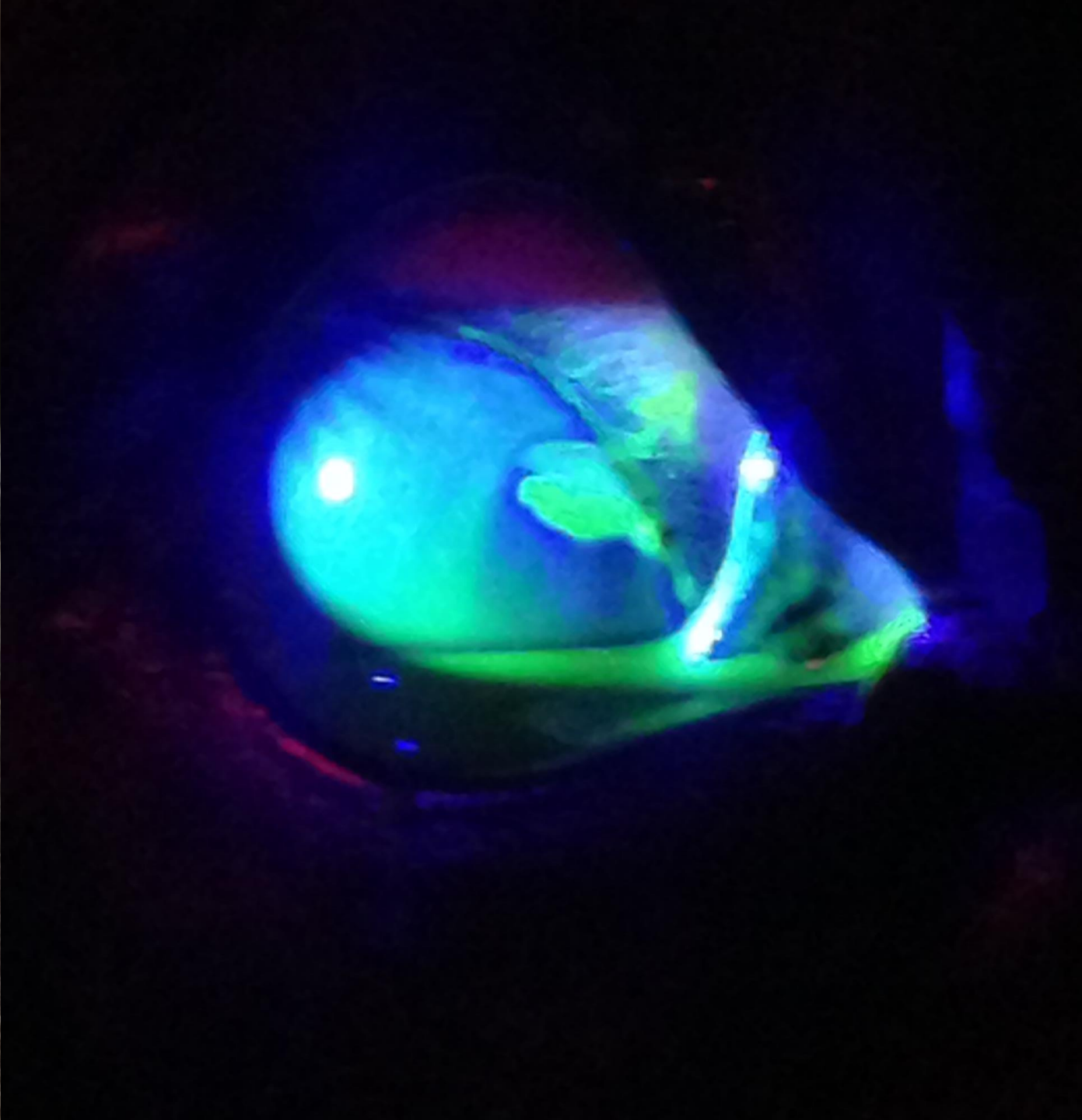


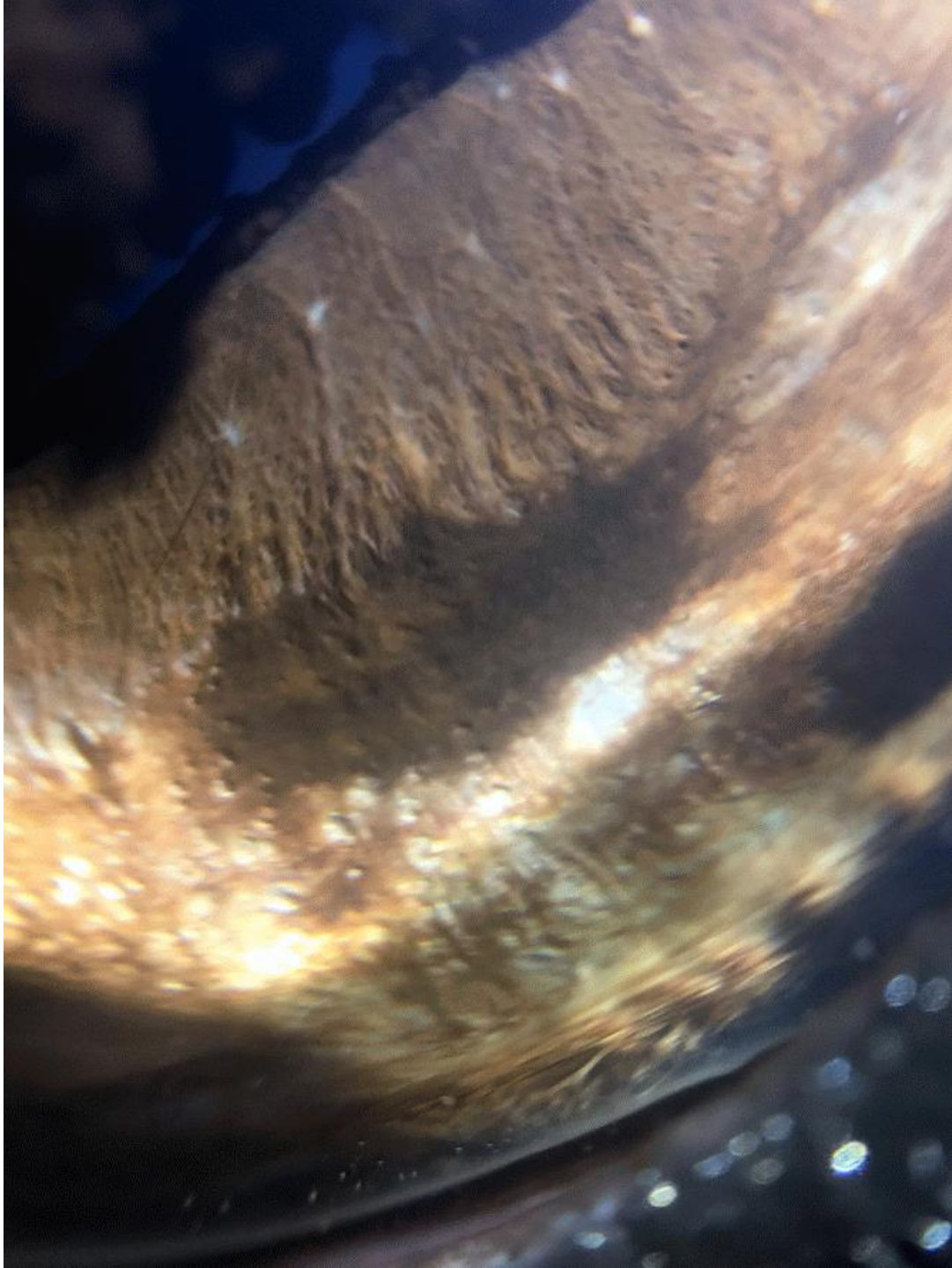




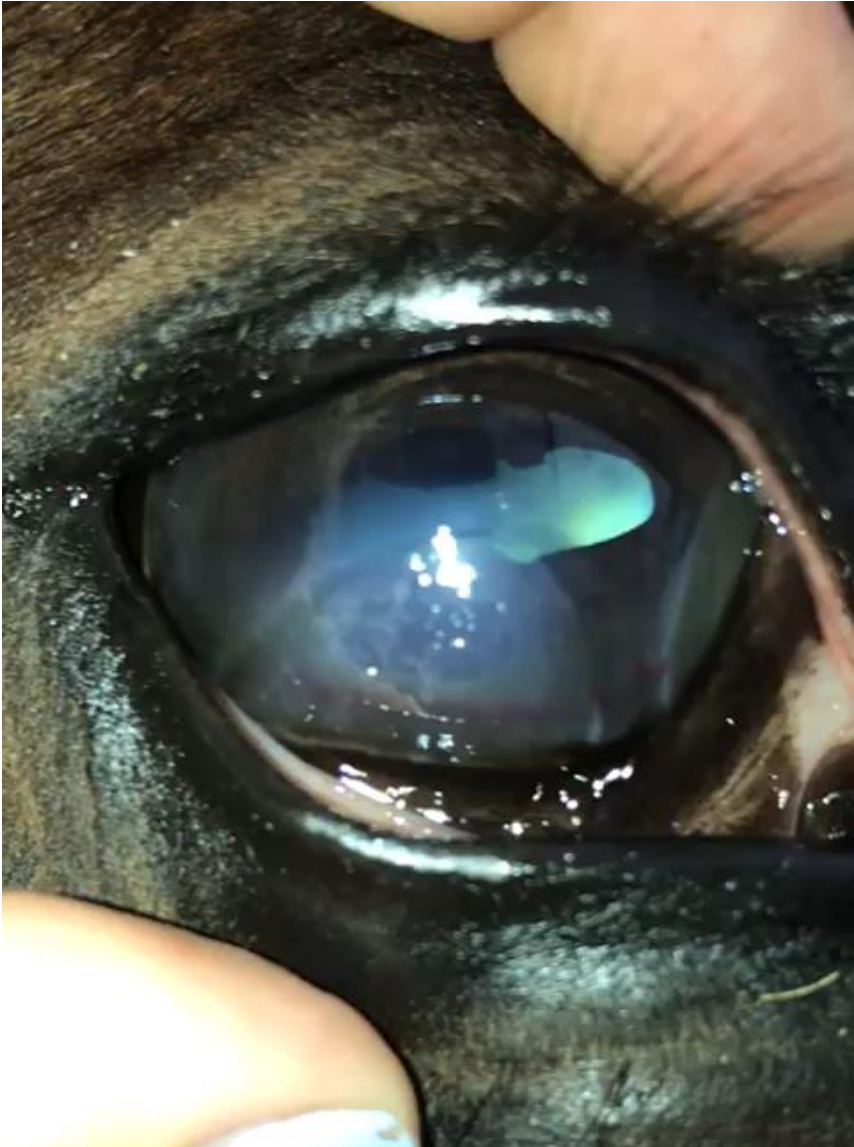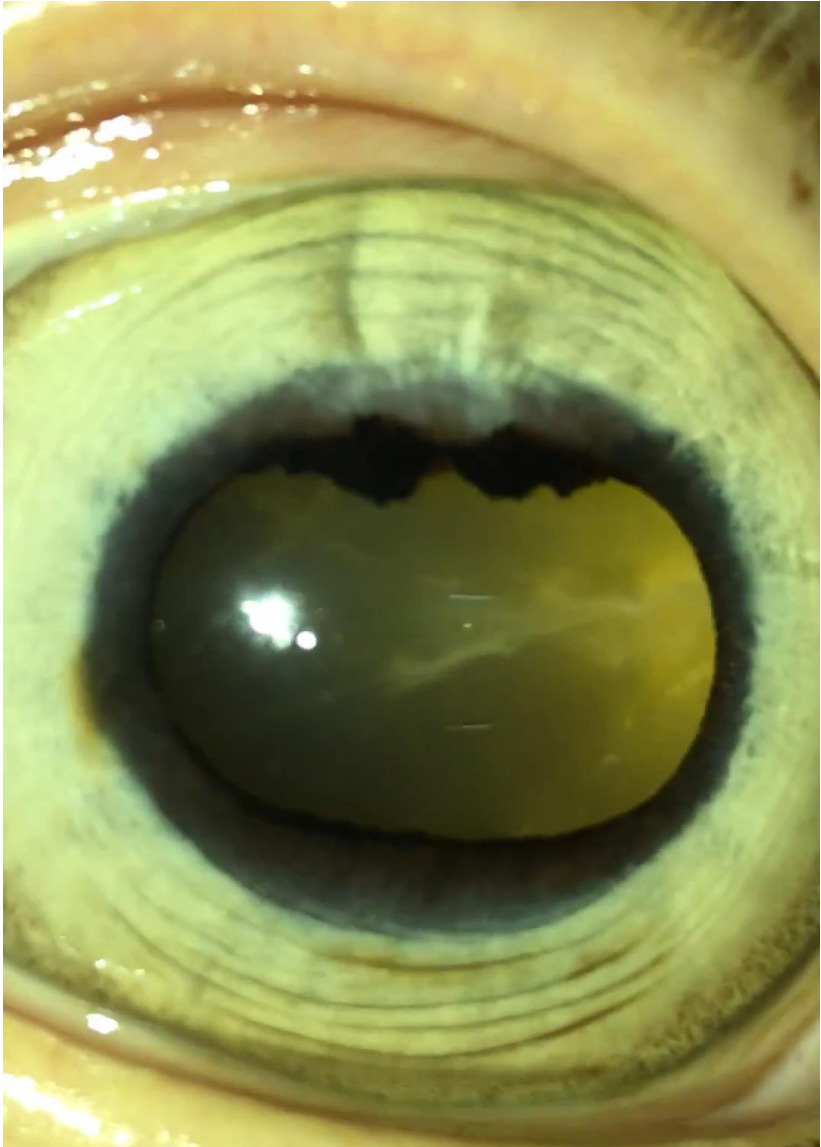


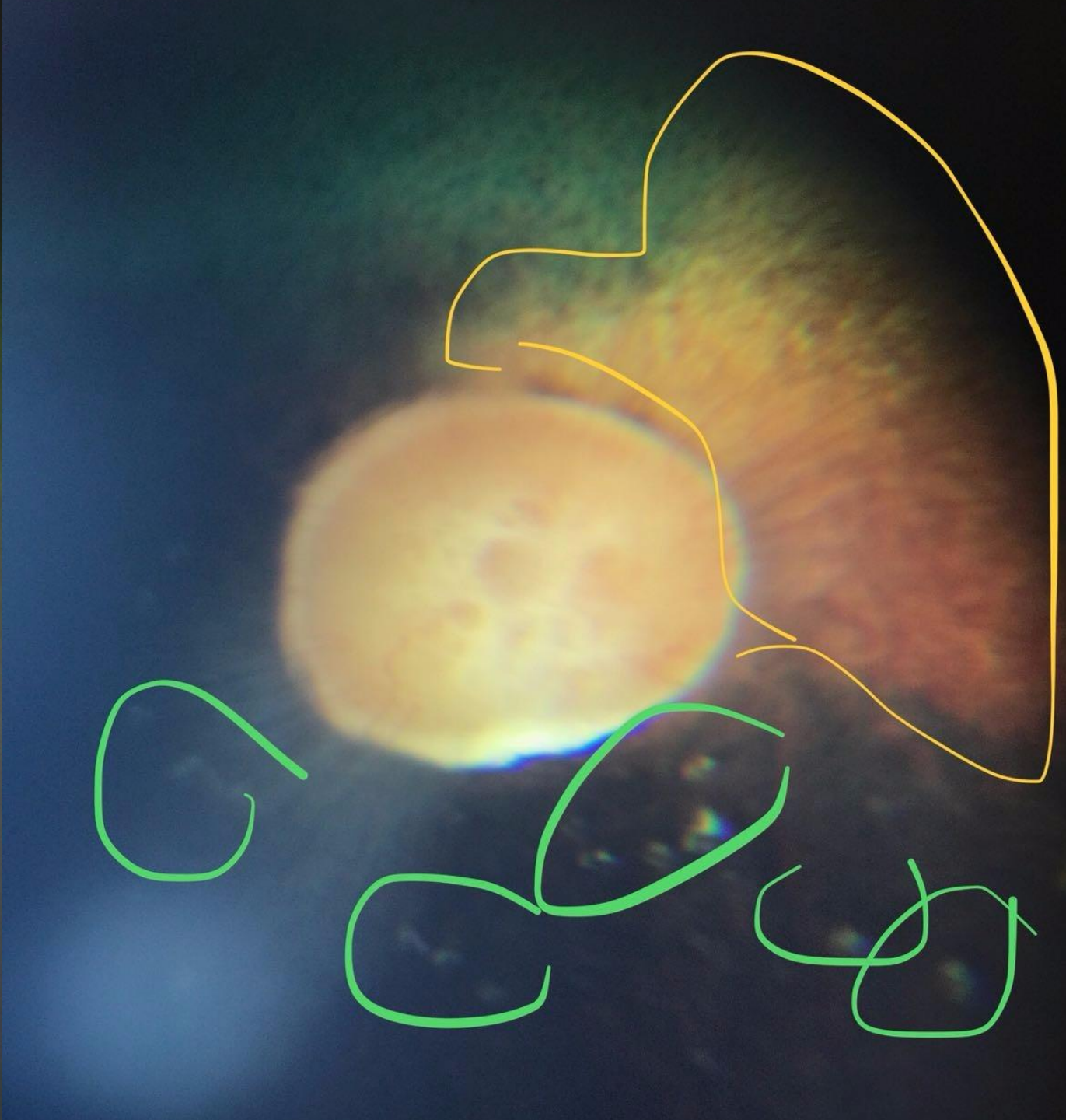
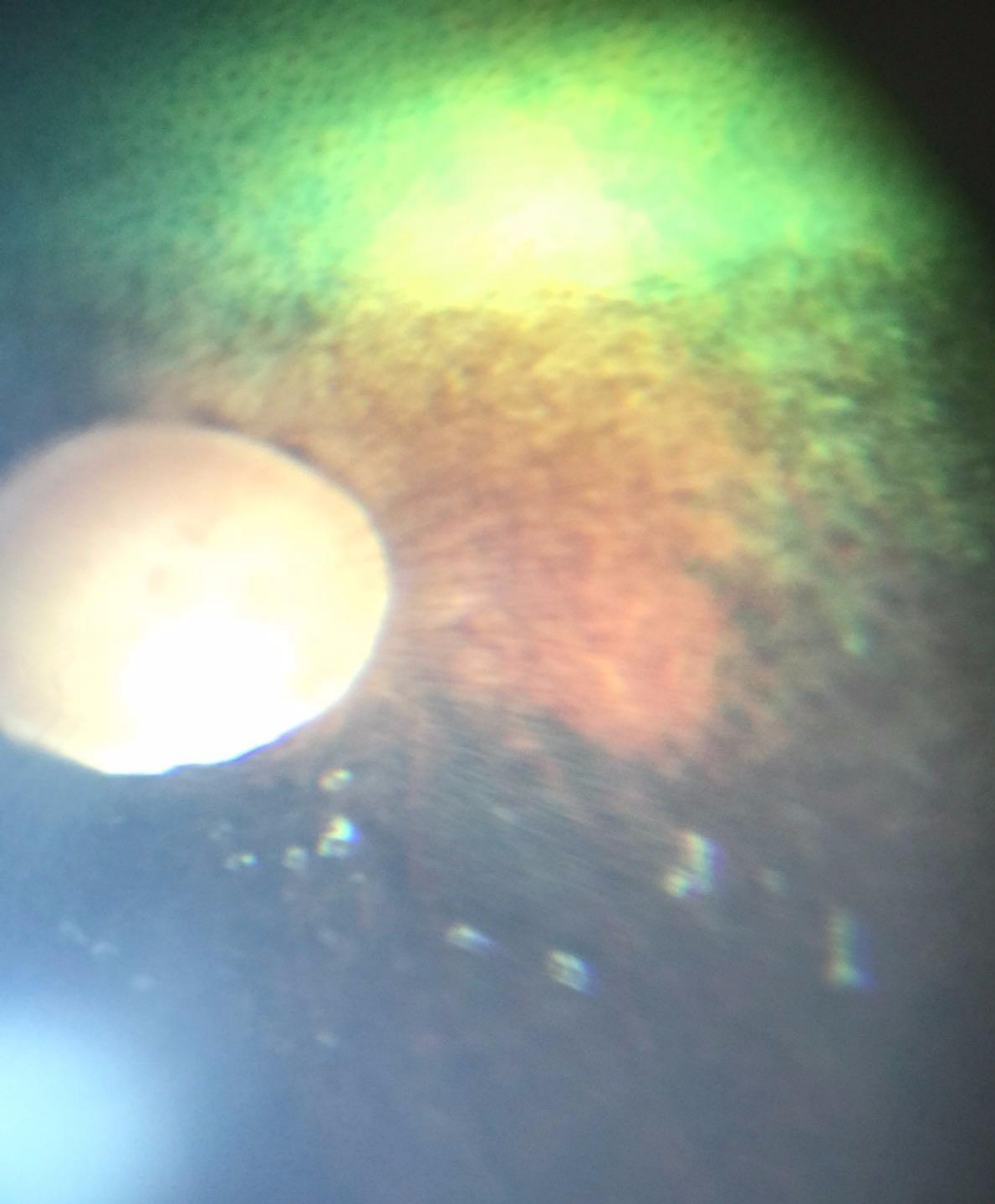


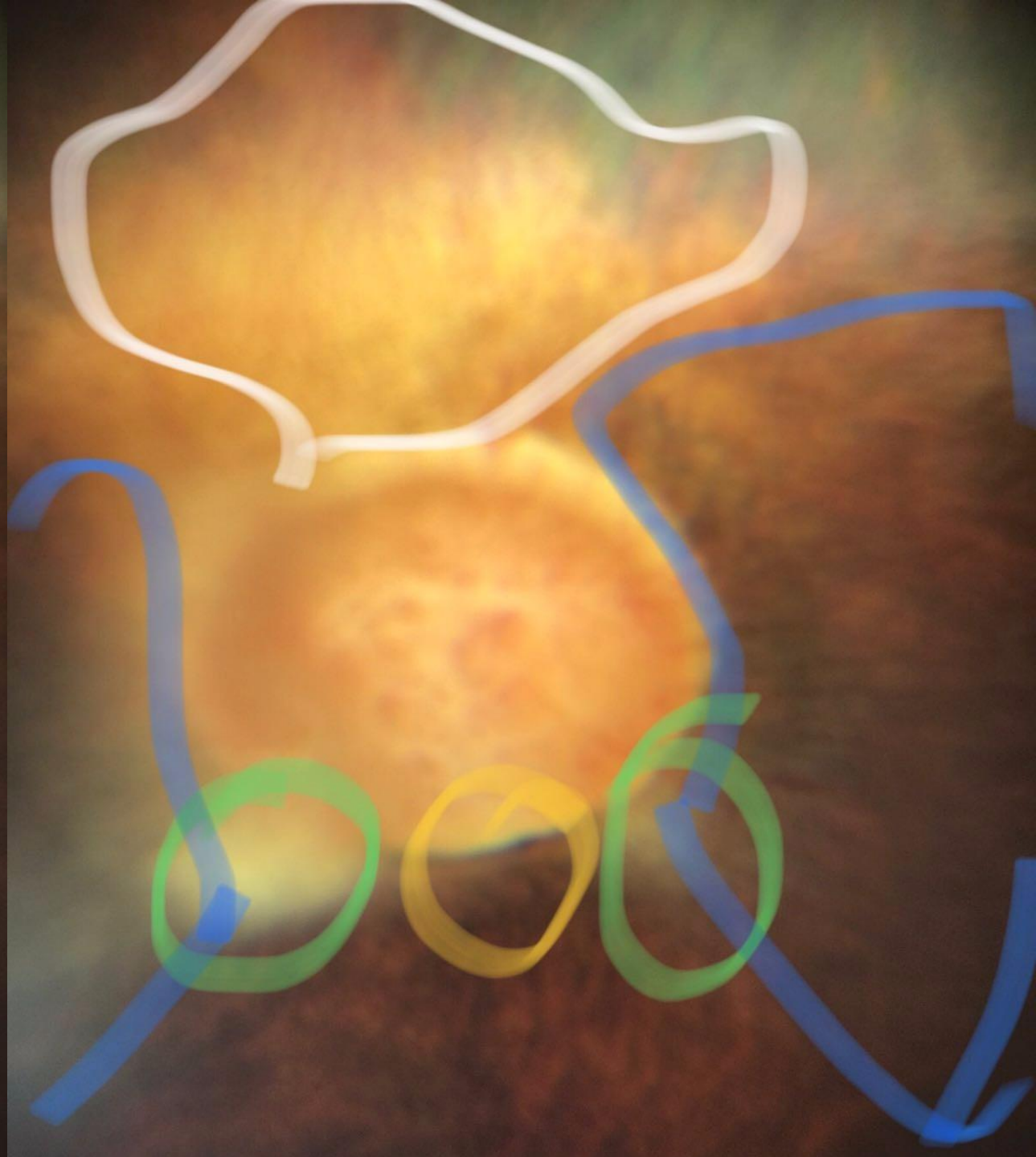
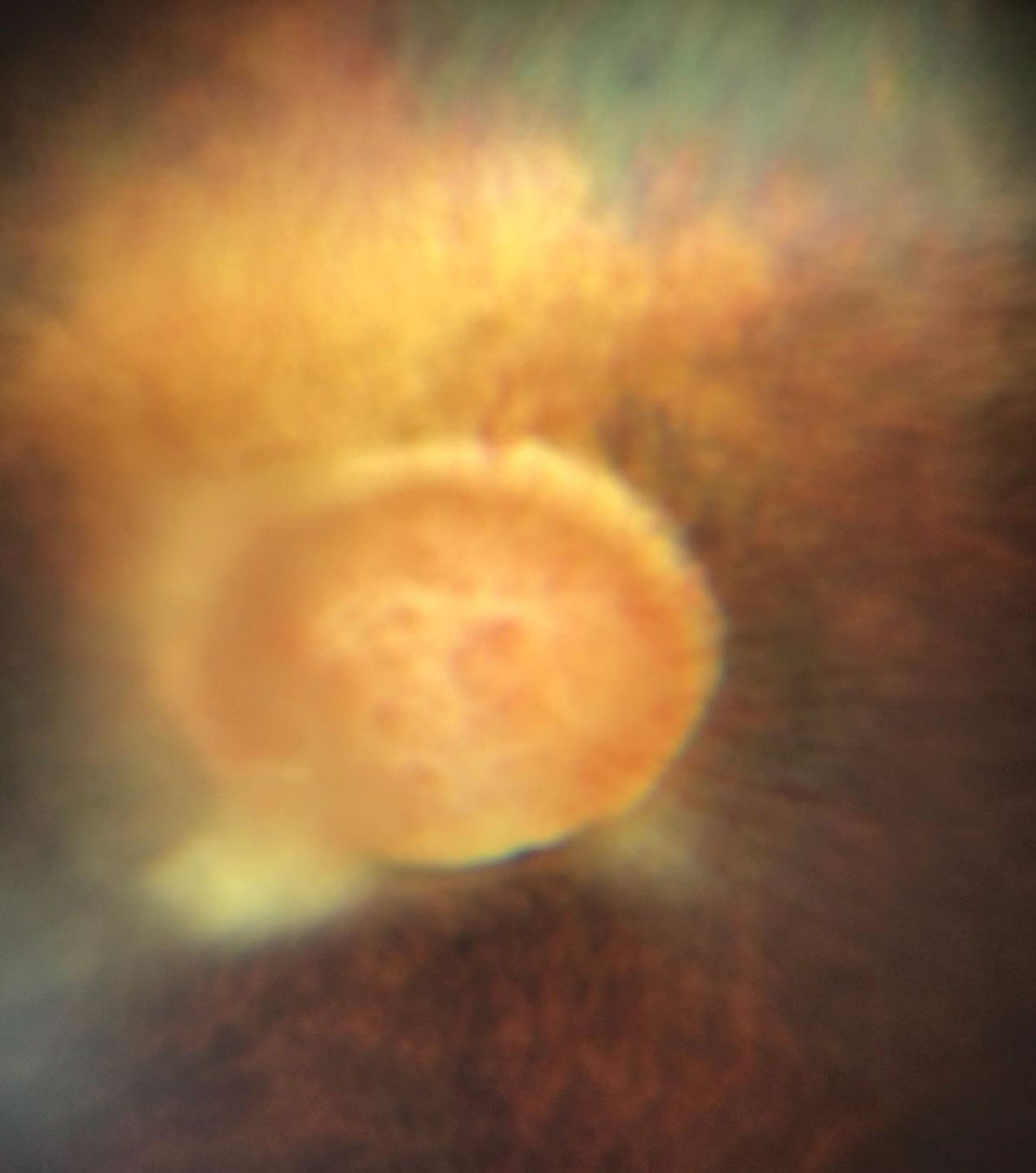




Telemedicine: try videos








Equipment-“must haves”

- Direct ophthalmoscope
- Smart phone
 - With an app to allow easier ocular examination
 - “Phone a friend” number
- Head torch
 - Ideally with a rheostat e.g. LedLenser HR7
- Cotton buds, bacteriology swabs & slides
- Magnification
 - Smart phone macro lens
 - Loupes – “optivisor”
 - Reading glasses
- Small needles, tropicamide, local & fluroscein



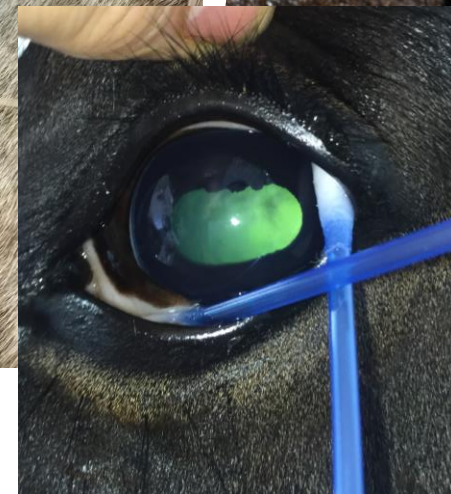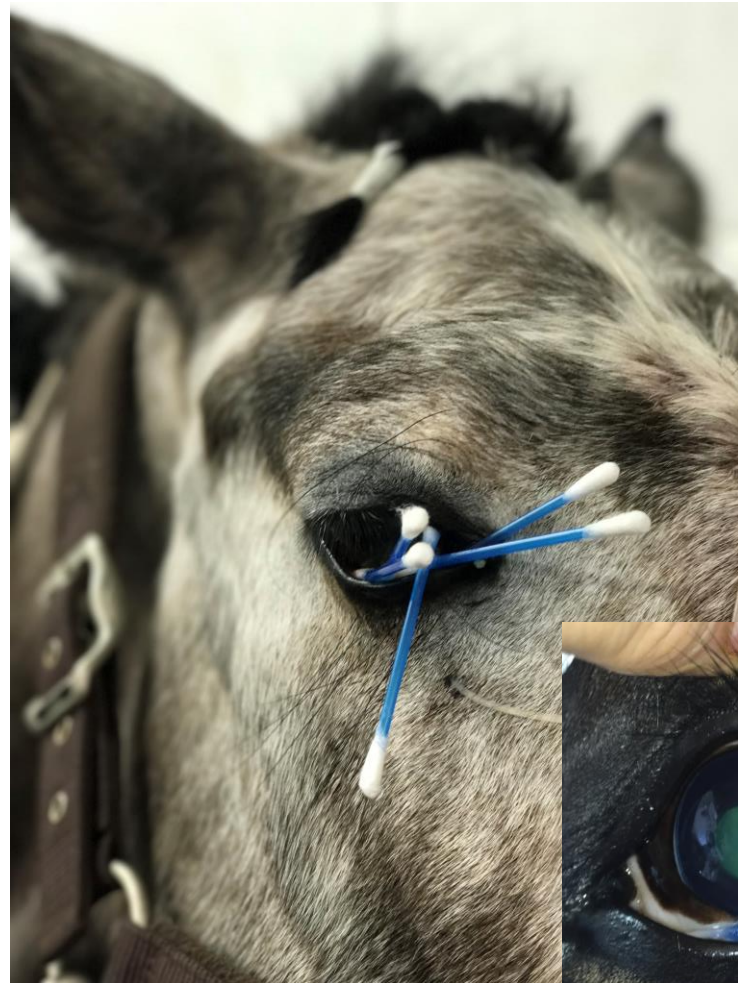Cotton buds – your third pair of hands

- (& bacteriology swabs)
- Corneal sensation
- Intraocular pressure estimation
- Exploration
 - Conjunctival fornices
 - Eye lid margins
 - Eversion of third eye lid
- Targeted local anaesthesia
- Removal of foreign bodies
- Epithelial debridement



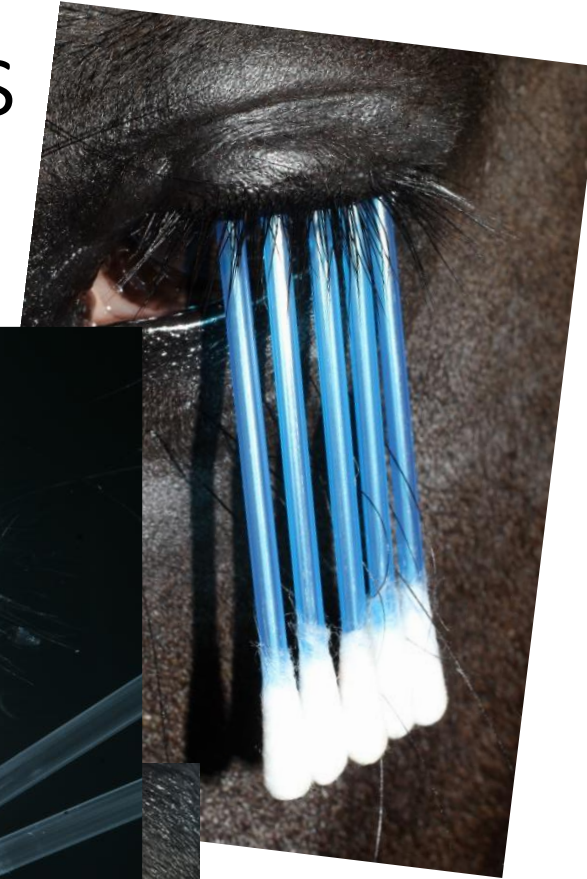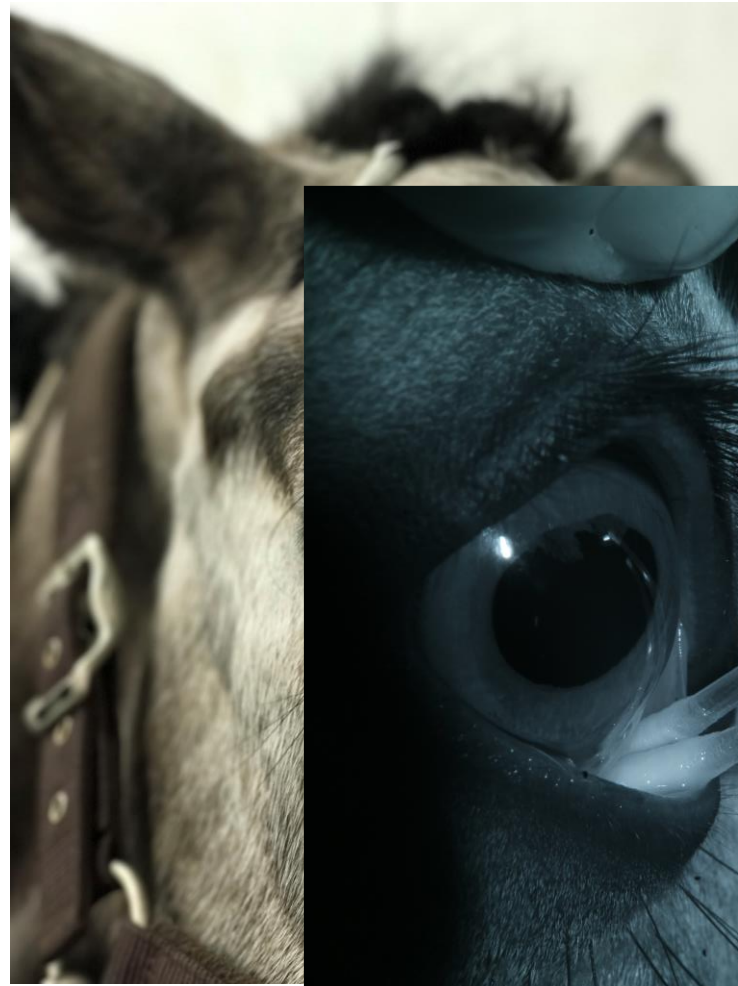
Cotton buds – your third pair of hands

- (& bacteriology swabs)
- Corneal sensation
- Intraocular pressure estimation
- Exploration
 - Conjunctival fornices
 - Eye lid margins
 - Eversion of third eye lid
- Targeted local anaesthesia
- Removal of foreign bodies
- Epithelial debridement



Cotton buds – your third pair of hands

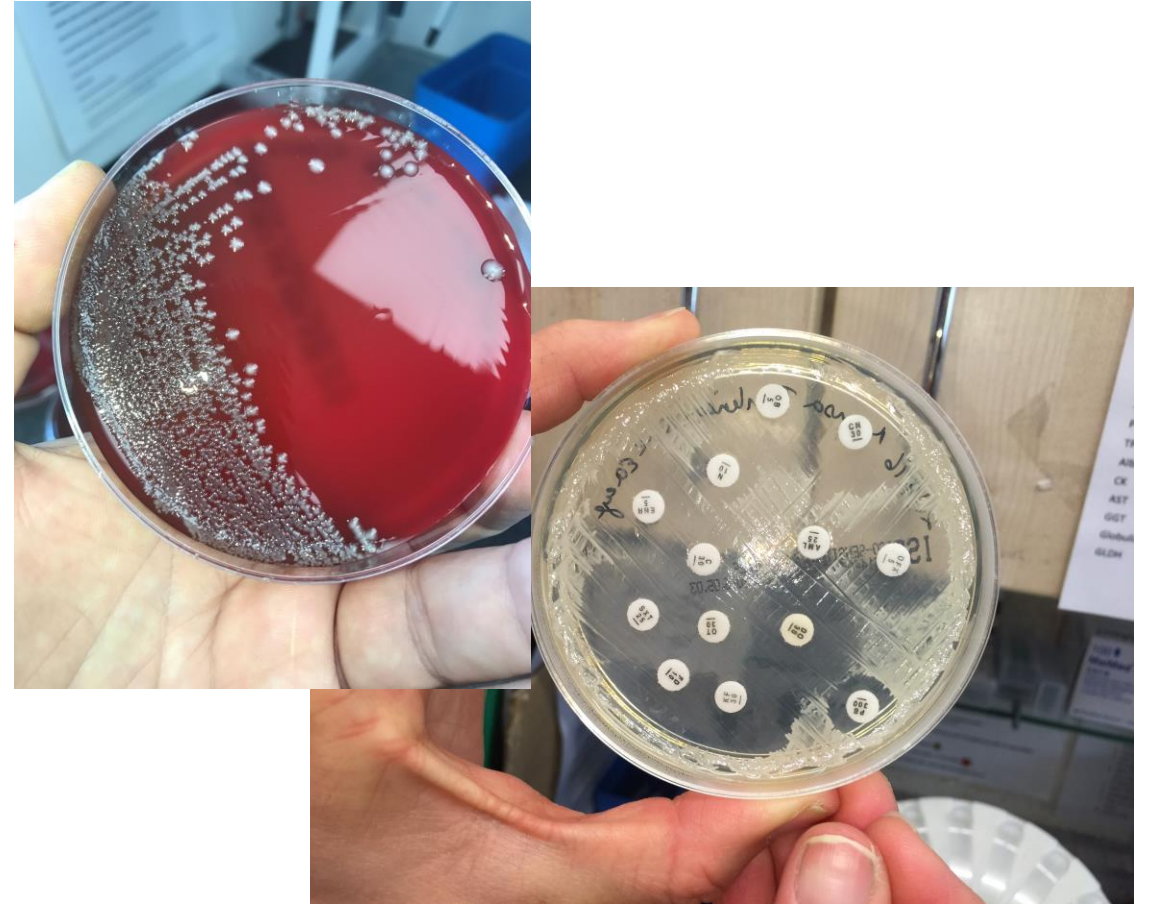
- (& bacteriology swabs)
- Corneal sensation
- Intraocular pressure estimation
- Exploration
 - Conjunctival fornices
 - Eye lid margins
 - Eversion of third eye lid
- Targeted local anaesthesia
- Removal of foreign bodies
- Epithelial debridement





Cotton buds – your third pair of hands

- (& bacteriology swabs)
- Corneal sensation
- Intraocular pressure estimation
- Exploration
 - Conjunctival fornices
 - Eye lid margins
 - Eversion of third eye lid
- Targeted local anaesthesia
- Removal of foreign bodies
- Epithelial debridement



Equipment-“must haves”

- Direct ophthalmoscope
- Smart phone
 - With an app to allow easier ocular examination
 - “Phone a friend” number
- Head torch
 - Ideally with a rheostat e.g. LedLenser HR7
- Cotton buds, bacteriology swabs & slides
- Magnification
 - Smart phone macro lens
 - Loupes – “optivisor”
 - Reading glasses
- Small needles, tropicamide, local & fluroscein

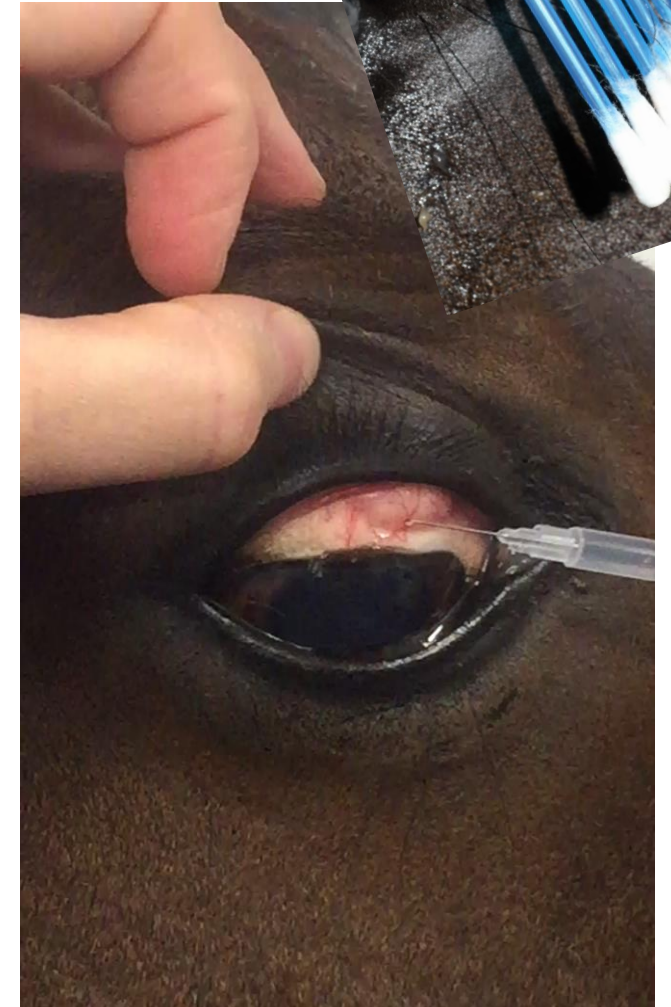
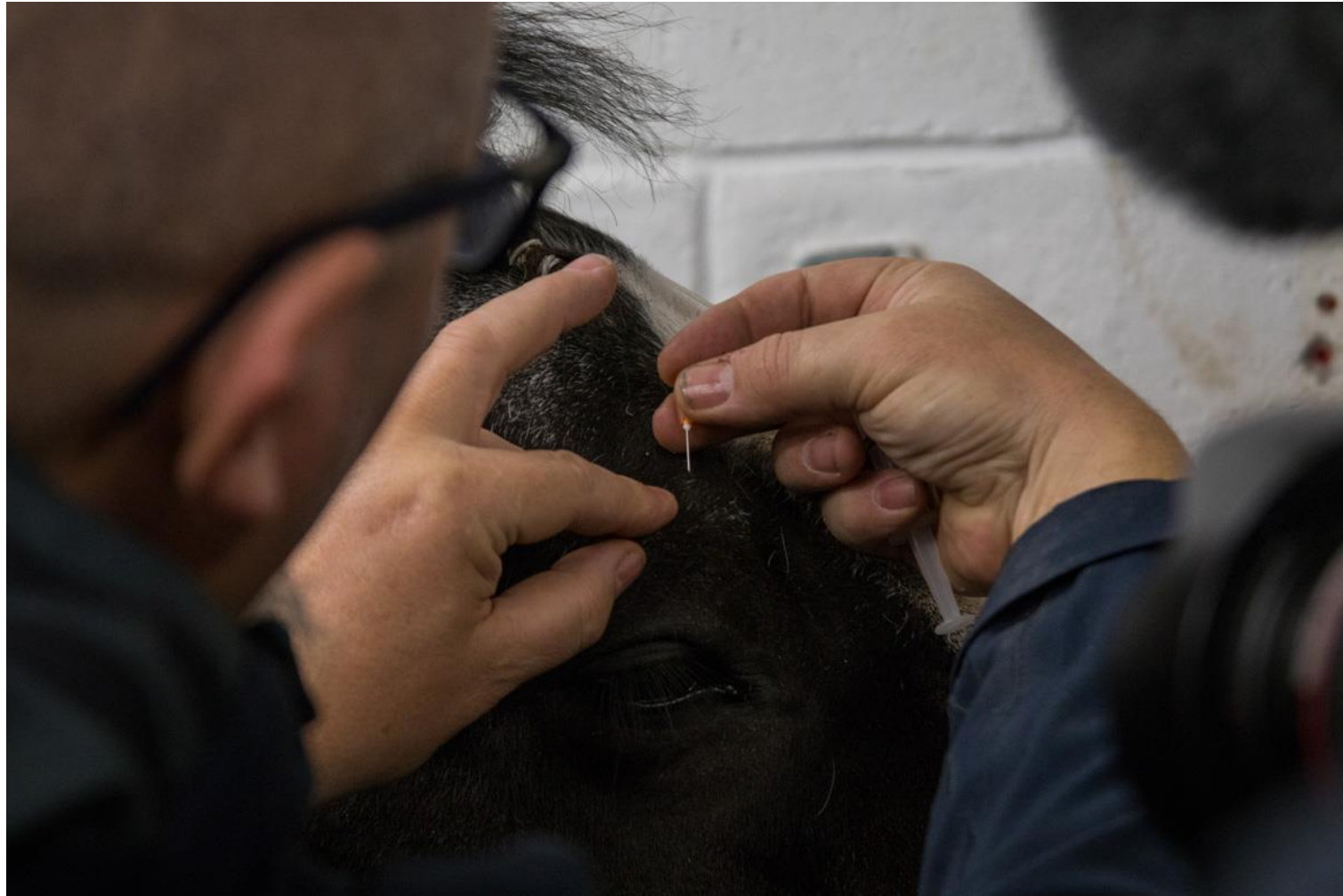

Equipment-“must haves”

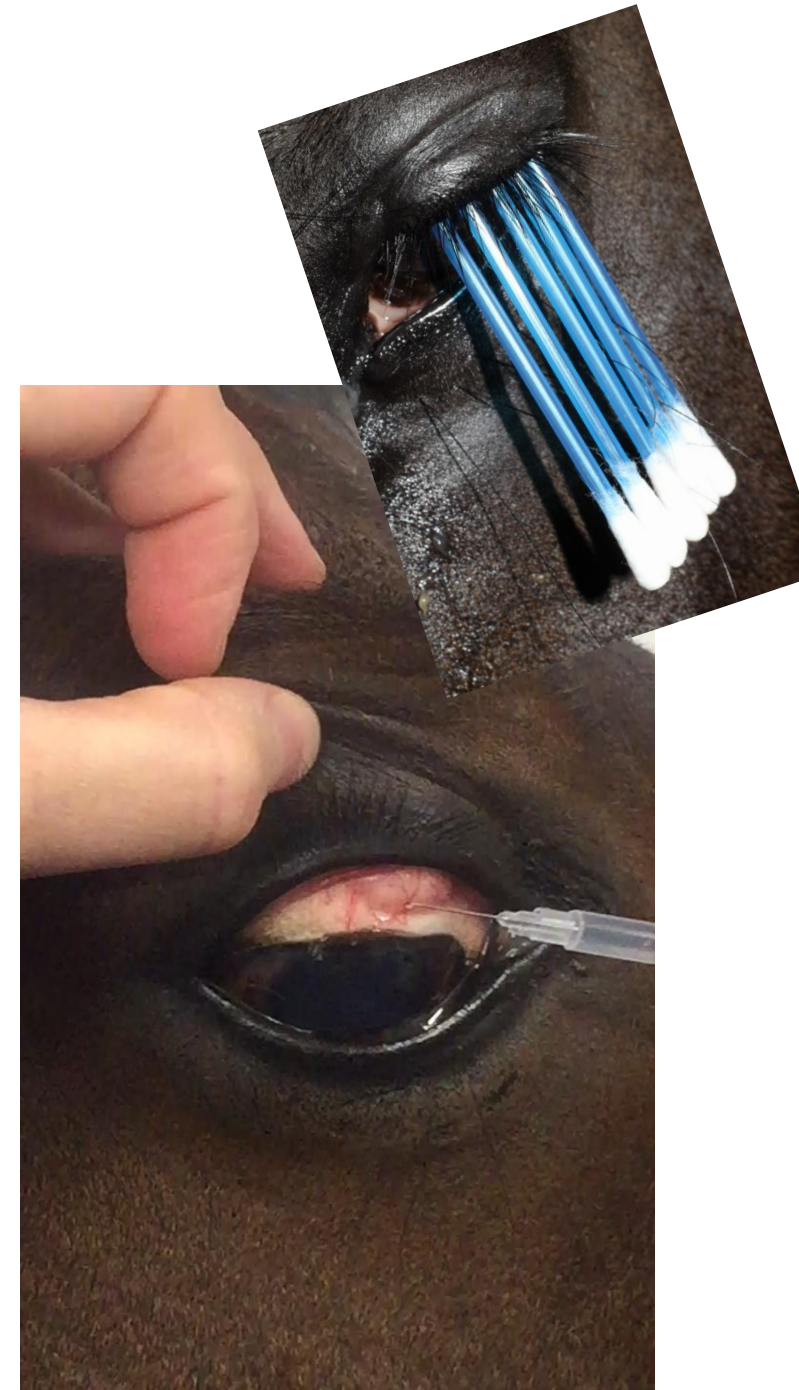
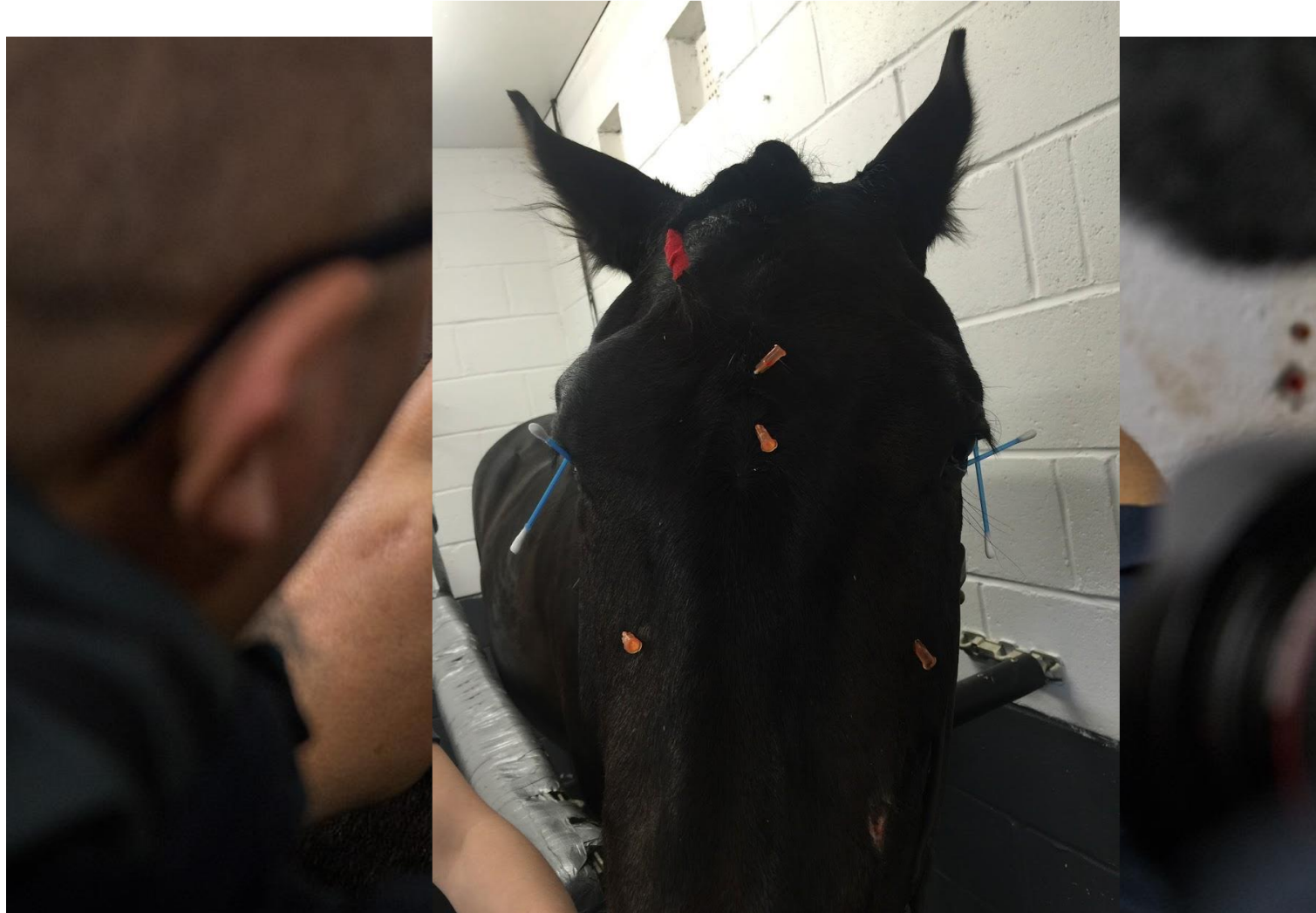
- Direct ophthalmoscope
- Smart phone
 - With an app to allow easier ocular examination
 - “Phone a friend” number
- Head torch
 - Ideally with a rheostat e.g. LedLenser HR7
- Cotton buds, bacteriology swabs & slides
- Magnification
 - Smart phone macro lens
 - Loupes – “optivisor”
 - Reading glasses
- Small needles, tropicamide, local & fluroscein



Little needles: “how to...” @ www.Equineeyeclinic.co.uk



Little needles: "how to..." @ www.Equineeyeclinic.co.uk



Equipment “nice to haves”

Equipment – “nice to haves”

- Slit lamp
 - Monocular (£300-900)
 - Binocular (£800-3,000)
- Cytobrush
- Schirmer tear test papers
- Tonometer
 - Tonovet > tonopen
- Ultrasound
 - High fq linear probe



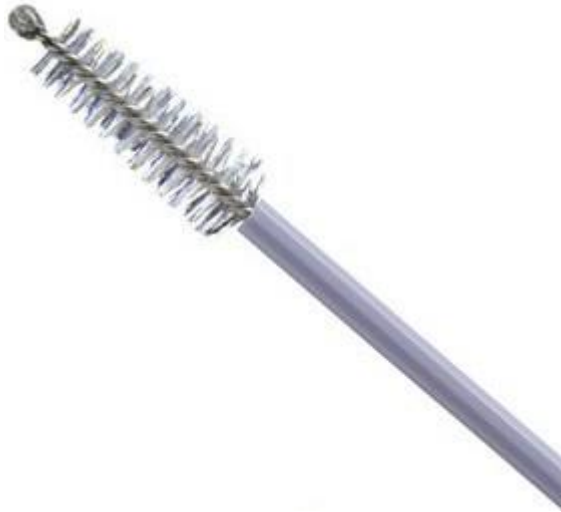

Diagnostic equipment – nice to haves

- Slit lamp
 - Monocular (£300-900)
 - Binocular (£800-3,000)
- Cytobrush
- Schirmer tear test papers
- Tonometer
 - Tonovet > tonopen
- Ultrasound
 - High fq linear probe



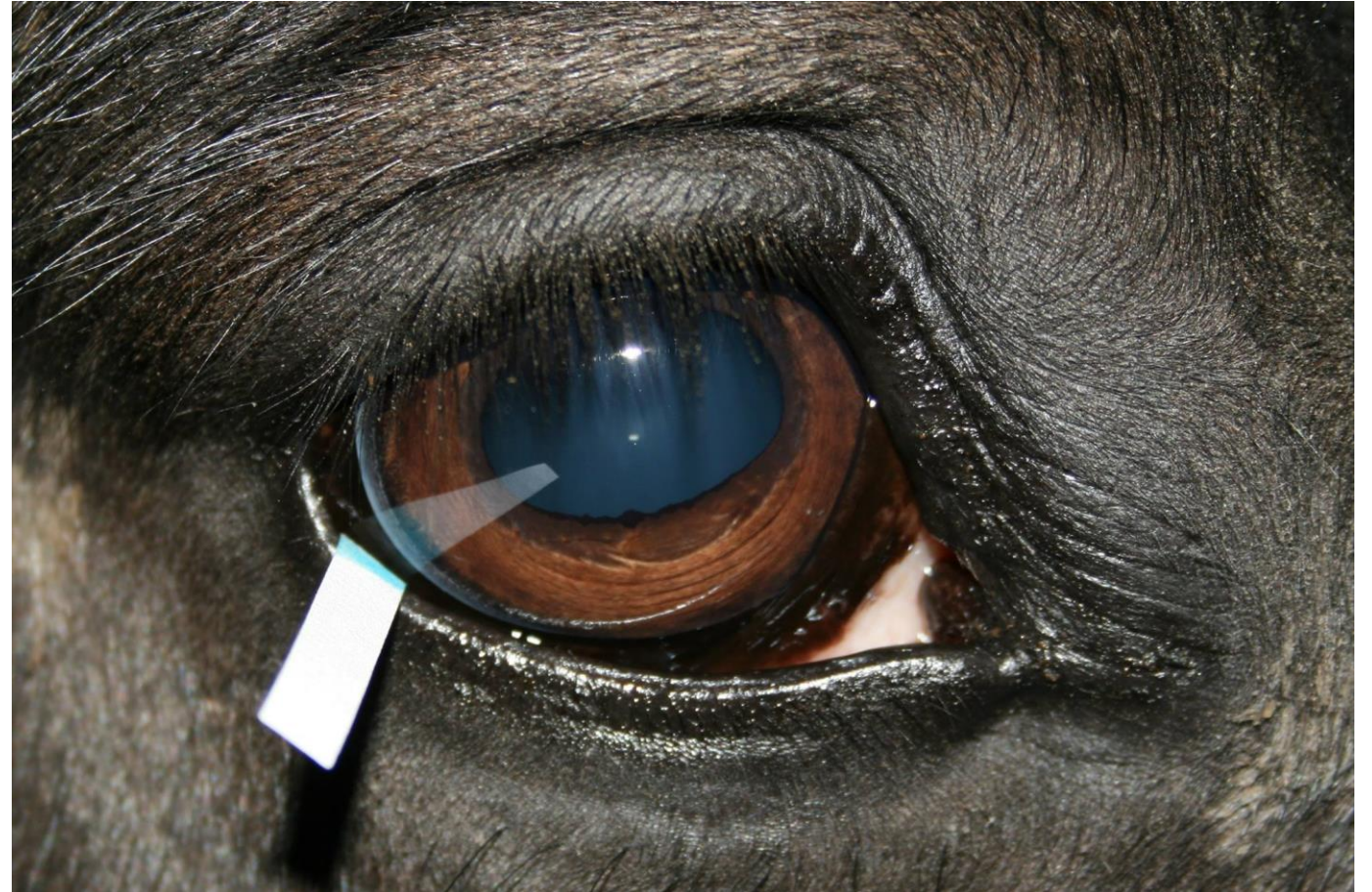Cytobrush/micro-brushes



- **Medscand Cytobrush Plus GT Endocervical Sampler – Cooper Surgical**
- **Disposable micro brushes (cosmetic application and dental treatment) – amazon/IMS/ebay**


Diagnostic equipment – nice to haves

- Slit lamp
 - Monocular (£300-900)
 - Binocular (£800-3,000)
- Cytobrush
- Schirmer tear test papers
- Tonometer
 - Tonovet > tonopen
- Ultrasound
 - High fq linear probe



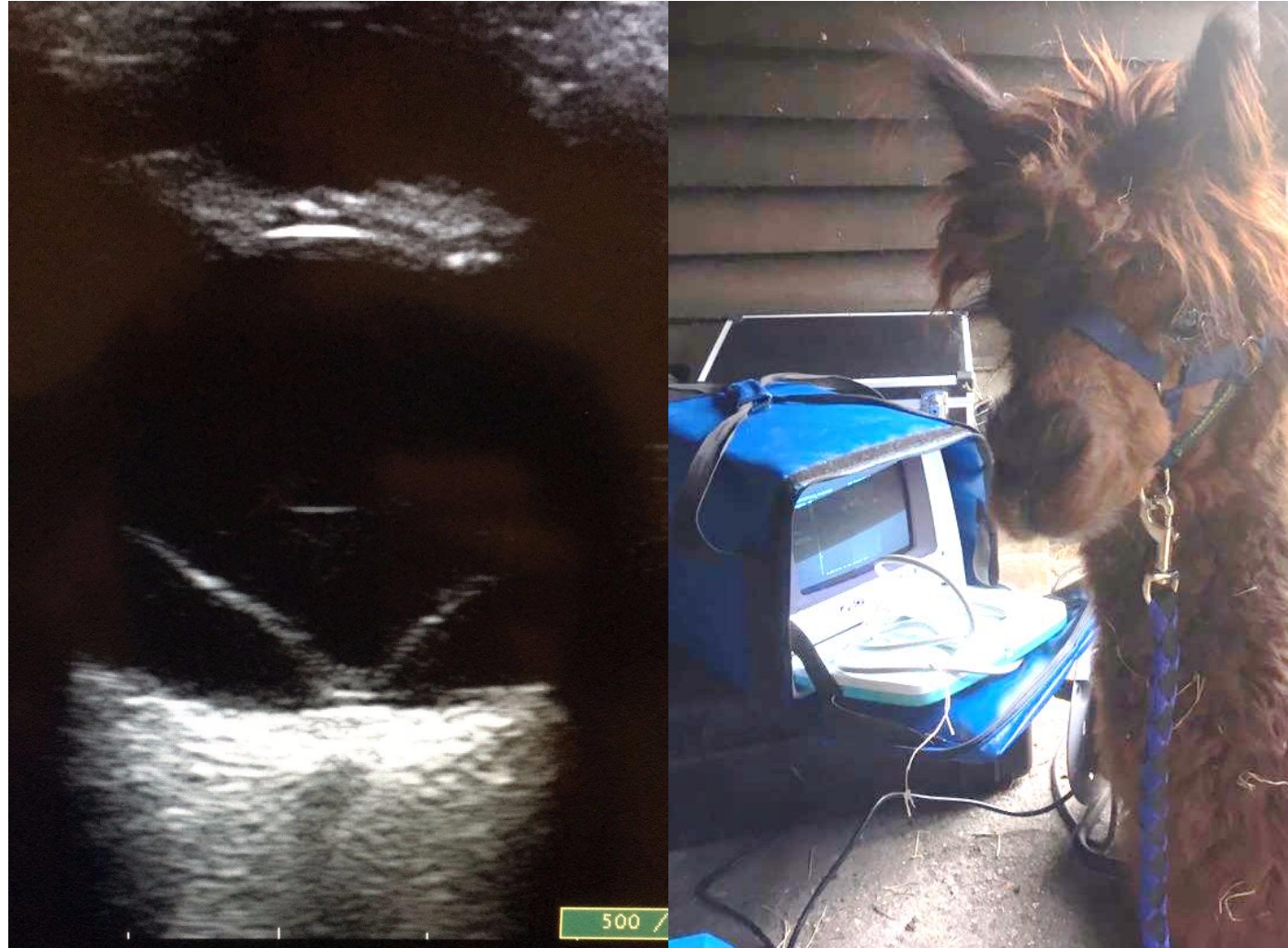
Diagnostic equipment – nice to haves

- Slit lamp
 - Monocular (£300-900)
 - Binocular (£800-3,000)
- Cytobrush
- Schirmer tear test papers
- **Tonometer**
 - Tonovet > tonopen
- Ultrasound
 - High fq linear probe

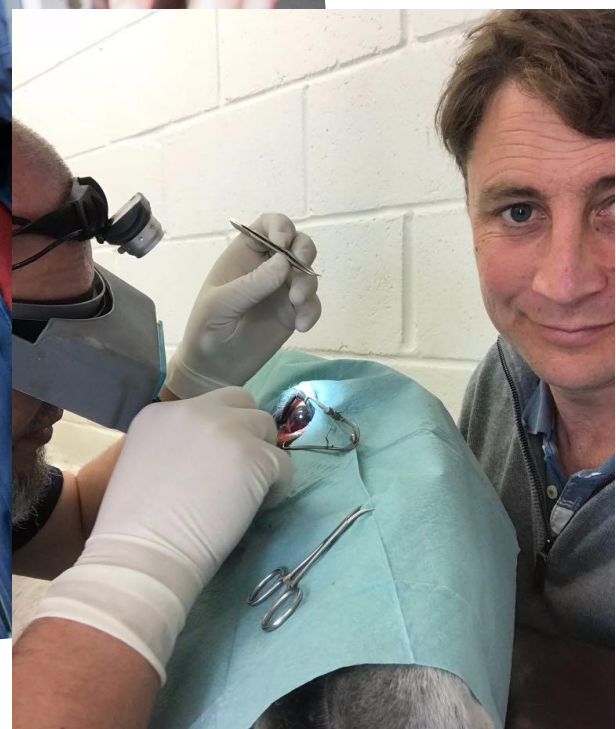


Diagnostic equipment – nice to haves

- Slit lamp
 - Monocular (£300-900)
 - Binocular (£800-3,000)
- Cytobrush
- Schirmer tear test papers
- Tonometer
 - Tonovet > tonopen
- **Ultrasound**
 - High fq linear probe



Thanks for listening



[Home](#)[Locate a Member](#)[Membership](#)[Resources](#)[Education](#)[Research](#)

Edinburgh, Scotland, EU - 2023



2023 IEOC Equine Ophthalmology Symposium Edinburgh, Scotland

June 1-3, 2023



Quick Links

- [Home](#)
- [Forums](#)
- [Forum & Profile Help](#)
- [Industry News](#)
- [Resources](#)
- [Locate a Member](#)
- [What's Your Diagnosis?](#)
- [Member Publications](#)
- [Clinical Articles](#)
- [Glossary](#)