

# Ophthalmic Smartphone Photography Masterclass.

Tim Knott, The Equine Eye Clinic and Rowe Referrals, UK  
+44 778 2219868 timknott@equineeyeclinic.co.uk

## Program

Introduction to smartphone photography & distant direct photography	<i>Page 2</i>
Practical session 1: getting the basics sorted	<i>Page 11</i>
Anterior segment photography Part 1: The cornea	<i>Page 13</i>
Practical session 2: Corneal photography	<i>Page 21</i>
Anterior segment photography Part 2: Iris & lens	<i>Page 23</i>
Practical session 3: Iris & lens photography	<i>Page 25</i>
Posterior segment photography	<i>Page 27</i>
Practical session 4: Posterior segment photography	<i>Page 34</i>

# 1: Introduction to smartphone photography

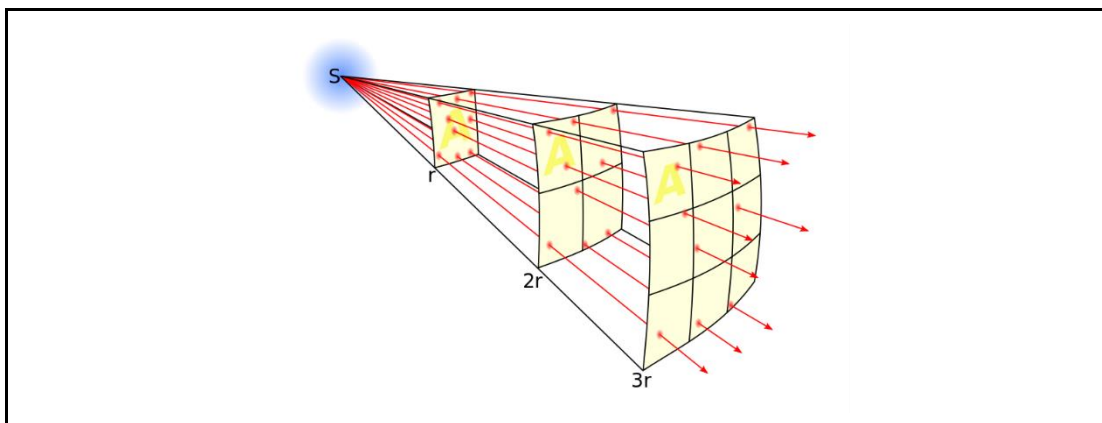
## Introduction and beginners guide to photography

### Basic principles:

**“Focus first”**: The importance of focus cannot be overstated, where there is too little or too much light, post processing of the image can usually obtain useful information, but a poorly focussed image is rarely salvageable. A good camera app will allow you to focus automatically, tap the screen to focus at a specific point and to set the focus manually. Learning how to do this well is the single most important skill to learn.

**“More light means more information... but you can get too much of a good thing so avoid overexposure.”**: In general, the more light we can get to the cameras sensor the more information we can record. Thus, the brighter the LED and the more dilated the pupil the more information we can usually get from a fundic image. Underexposed images will often hold hidden information, especially when using RAW or DNG format images which can be found in post processing. In contrast overexposed images will contain very little information thus if struggling with exposure, *always aim for under rather than over exposure*. This is particularly important with the fundus where the contrast between the tapetal and non-tapetal fundus can be striking. The use of HDR (high dynamic range) or the newer, and quicker, DRO (dynamic range optimisation) technologies built in to many camera apps and cameras help with images with a wide range of exposure such as the fundus, experiment with these settings when imaging your eyes.

**“Remember the inverse square law”**. Light intensity drops off rapidly as the distance from the light source to the object imaged increases, the decrease is proportional to the square of the distance thus small differences in distance have a very significant effect on light intensity.



*Light intensity reduces inversely to the square of the distance from source. Thus small changes in distance between phone camera and patient can make large differences to the shutter speed, and thus camera shake, and ISO, and thus image “grain”. Closer the better but remember to reduce exposure settings if at risk of over exposure as you will lose information in the highlights.*

[https://en.wikipedia.org/wiki/Inverse-square\\_law](https://en.wikipedia.org/wiki/Inverse-square_law)

**“Understand depth of field (DOF) and how to manipulate it”**. DOF is a familiar concept if you are used to using a slit lamp or surgical magnification. DOF is inversely proportional to magnification which can become problematic when using a high magnification macro lens on the smartphone. DOF

can be increased by decreasing aperture however most smartphones have a fixed, wide open aperture which maximises the light hitting the sensor whilst reducing DOF. DOF can also be increased by using a wider angle camera (e.g. on the dual, and now triple, camera smartphones).

**“Image quality - its all about physics”.** However good smartphone cameras are, the bigger the sensor, the larger the lens and the smaller the aperture the better the image. This becomes obvious when you zoom in to a smartphone image as the image rapidly deteriorates. The physics of small lenses and small sensors means that truly sharp high resolution cropped images are difficult for smartphones to produce however the powerful computer processing now available in most devices allows amazing images to be optimised to give the best image for the smartphone screen *when not cropped*.

Thus the best images are usually obtained if you aim for your image to be composed to fill the screen and not rely on cropping images. For the very best images, which will allow you to crop and still get excellent images or display or print at large scale, the large sensor and a variable aperture of a digital camera are still preferred.

## Why use your smartphone to image the eye?

The “best camera” is the one you have with you and the one you know how to use. Whilst images of higher resolution, better depth of field and sharper focus can no doubt be obtained with “proper” digital cameras they can be cumbersome, fragile, expensive, require images to be transferred off them and often require specialist batteries, lenses and flash equipment to get the best images. While the smartphone can be used for documenting the whole eye exam it really comes into its own when we have pathology to document. The small smartphone lens allows us to obtain amazing magnification with cheap macro lenses and, when combined with either a pen torch or the phones LED, to obtain images of the subtle cornea, lens and vitreal lesions I really struggle to image with my DSLR.

***However, the smart phone’s unique advantage is that it allows us to image the retina and lens lesions without the use of any additional lenses or devices making it an essential tool for the equine ophthalmologist.***

## How many photos to take, where to put them and how to find them?

Whilst a single image may well capture all you need most cases benefit from multiple images being taken using different magnifications, light intensities and direction. I would routinely obtain 20-30 images per case which can make storage and retrieval challenging. I use an intelligent cloud-based storage system (google photos, <https://photos.google.com>) which makes this process automatic.

Benefits of google photos:

- It’s free (but image size reduced to 16MP, as all iPhones take 12MP images this means they are uploaded at maximum resolution)
- Paid version allows full resolution image upload.
- Images accessible from any web browser
- Images can be synchronised with your home computer using the google drive app.
- Easy to insert images in to reports written with google docs
- Android and iOS app available which auto upload images for you
- Search by location (ensure geotagging turned on in the camera app when take image)
- Search by date and time

- Search by species
- Search by colour
- Search by keywords placed in image description (tagging)
- Automatic animation generation \*
- Automatic image optimisation\*
- Automatic movie creation\*

\*using google assistant

Other cloud based storage systems which include tagging include Onedrive and Flickr

## What photos to take?

In the same way we might take a routine series of survey orthopaedic radiographs for sale I aim to take a set series of routine ophthalmic photographs, especially for pre purchase examination cases. My preference is to take my survey images with my DSLR, 50mm prime lens and extension tubes and with the smart phone to image the visual axis and the fundus. They are however often all taken with my smartphone (either because my SD card is full, the camera batteries are flat or I've left it in the car). These are taken at the start of the examination so if I get excited by pathology in one eye I know I have a record of the other eye should I forget what I saw in the normal eye.

## Aim to take standard views for all patients

1. Video recordings of visual assessment (obstacle course, menace, tracking etc)
2. Whole patient (and identity document)
3. Head, front aim to get both tapetal reflections
4. Face, laterals
5. Whole eye. Three views, caudal, cranial (aim to skyline corneal curvature and anterior chamber) and lateral.
6. Eyelids; everted superior and inferior margins, TE (prolapsed) and medial canthus/caruncle
7. Distant direct view; lateral, caudal, cranial and inferior pre-dilation to record visual axis
8. "sneak peek" at retinas pre dilation to ID gross retinal and vitreal pathology

During the ophthalmic examination specific images are taken as pathology or interesting anatomy is identified. Each lesion type has its own photographic challenge to overcome and may need multiple images with different photographic modalities and lighting to document fully. This can mean some cases will have many dozens of images taken.

Images of the whole head and horse are usually straightforward although care should be taken to accurately record symmetry.

An understanding of multiple photographic technique can however allow you to maximise the clinical information recorded from your cases with the side effect of obtaining some breath-taking images.

Techniques to explore and master include:

- Life size photography
- Macro photography
- Tangential lighting
- Retro-illumination
- "Distant direct" photography
- Retinal photography
- Slit lamp photography
- Microscope photography

## But first, understand the limitations & advantages of your camera

**Camera lens position:** iPhone cameras are all located in the upper left corner, this makes close positioning of the camera to the eye much easier than many android phones where the lens is often positioned in the middle of the phone.

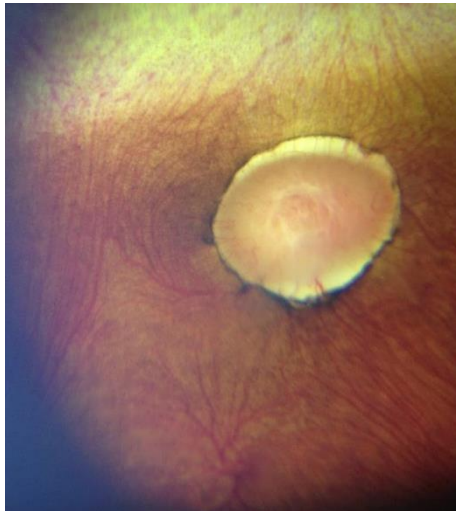
**Multiple cameras:** Where more than one camera is present on your smartphone (e.g. the iPhone X series and the Huawei pro) this can complicate ocular photography but also bring great advantages.  
Pros:

- Lenses of different focal lengths will have different MFD. The wider the lens the closer you can usually get.
- Telephoto cameras often allow greater magnification when coupled with a macro lens and can be very useful for examining retinal vasculature

Cons:

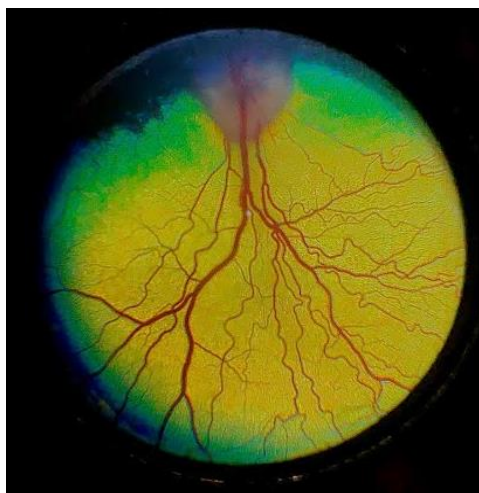
- Camera apps which don't allow you to force a particular camera lens to be used can be difficult to use.
- The LLD will vary depending on which camera lens used, understanding which camera lens is wide and which is telephoto is important to help get the most of your photography.

**LED position:** For fundus photography the smaller the Lens to LED distance (LLD) the better. The LLD distance directly determines the pupil size you can visualise the fundus using the direct "phoneoscopic" technique (mimicking direct ophthalmoscopy) which is my preferred technique for imaging the equine fundus. The horizontal equine pupil allows an undilated view of the fundus even when the LLD is large as long as the LED is oriented so that light can directly pass through the pupil.



*"direct phoneoscopic" view, sub-albinotic equine fundus. Uncropped image, iPhone 6plus*

When an indirect fundic image is obtained using a diagnostic condensing lens the phone's LLD becomes much less critical. This "indirect phoneoscopic" technique (mimicking indirect fundoscopy) is very helpful in small animal fundus photography especially with small pupils, when opacities are present in the ocular media and when the LLD of the camera used is larger than the pupil size. Indirect "phoneoscopy" is more technically challenging and as photography of the indirect image usually requires the use of digital zoom to fill the screen the resolution of indirect images is often less than images obtained with direct phoneoscopy.



*"indirect phoneoscopic" view, normal canine fundus, cropped image. iPhoneXS max & Volk panretinal 2.2 lens*

For macro lens assisted smartphone photography a large light to lens distance (LLD) such as the iPhone 7 plus and 8 plus can be a great advantage as it allows the option of using the camera's LED to directly illuminate the subject without the use of a modelling light.



*Comparison of the iPhone 7plus, left and the iPhone X, right.*

- 1. The large lens to light distance of the outer, wide angle, lens of the iPhone 7plus allows the LED to be used at the same time as a macro lens but makes imaging the fundus more challenging. In contrast the iPhoneX's LED is placed very close and between the wide angle and telephoto lens allowing direct imaging of the fundus through small pupils (6mm +) but precludes the use of the phone's LED when using a macro lens.*
- 2. The horizontally orientated iPhone 7plus lenses mean the phone can be held upright to image through the pupil whilst the vertically orientated iPhoneX's lens system means this phone needs to be held horizontally to image through the pupil.*

**Minimum focal distance (MFD):** Understanding how close you can get your camera to a subject and still obtain a focussed image (the MFD) is a key skill. The MFD for each camera on your phone is best estimated using a visual target with sharp lines such as provided in the practical session 1 notes below.

## Using your smartphone as a digital ophthalmoscope - video is your easiest way to start

The camera app which comes with most phones will not allow you to use the LED whilst taking pictures. Learning how to turn the light on whilst imaging the eye is what turns your smartphone into your very own digital ophthalmoscope and is key to entering the magical world of phoneoscopy. The simplest and quickest way to start obtaining ophthalmoscope like images with your smartphone is to use the video camera app and turn the light on. This technique allows rapid acquisition of lots of images which can be obtained by "grabbing" screenshots from paused video. Video also allows easy acquisition of images from multiple angles which can aid in the localisation of lesions in the visual pathway. This technique is very useful for owners to learn which can be an invaluable aid to managing patients away from your clinics.

For the very best images a camera app which allows continuous LED illumination (or "torch mode") and manual focus and exposure settings should be used to take still, or where available live, images.

# Setting up your smartphone for ophthalmic photography

**Step 1: Remove your smartphone case.** Your macro lens will fit more flush to the phone back and you will be able to get that little bit closer to the patient to give you the best fundic images, and the maximum usable illumination from the phone's LED.

**Step 2: Modify LED intensity.** Ideally this is done by the app however, currently, this is only possible with ProCamera on iOS devices. Alternatively, pieces of white label or micropore should be used to cover the LED, this will act as both a diffuser to reduce corneal light artefacts and to reduce light intensity allowing more comfortable visual axis and fundic imaging with less pupil constriction.

**Step 3: Install and set up an appropriate app.** See below.

## What's the best camera app for imaging the eye?

This changes regularly, I try to keep my favourites listed on the web site [www.theeyephone.com](http://www.theeyephone.com) however my current top apps are:

### Android:

1. **OpenCamera\*** (Free, Mark Harman, [www.opencamera.org](http://www.opencamera.org)) Stand out best!
2. Camera MX (free)
3. Camera FV-5 lite (free)
4. "A better camera" (free)

### iOS

1. **Procamera\*** -adjustable LED intensity coupled with manual focus and exposure and an excellent focus assist mode make this app the best app I've found so far
2. Camera+2 - the updated version of the original – even better now can adjust LED intensity although more expensive than ProCamera if upgrade to the Pro version which is required to access all functions.
3. Camera+ legacy - an old favourite, still the easiest app to use but as cannot adjust the LED brightness diffusing the LED with tape or paper is required.

\*preferred

## Understand your app

Learn how to :

### Control the LED

- turn on continuously using the "torch mode" also labelled as continuous flash mode in the open camera app.
- adjust intensity (either with app or using diffusers such as micropore tape or medicine labels, 3 layers of either is usually perfect)

### Focus

- control it (manual vs tap to focus vs autofocus)
- force the minimum focal distance, - this helps with "distant direct photography " of lens and corneal lesions and usually can be selected using the "macro" setting indicated by a flower icon
- force focussing at infinity - this helps with fundus photography and is usually indicated either by a mountain or an infinity icon ( $\infty$ )
- adjust and lock focus manually - this helps with difficult image lesions such as KPs, small cataracts etc

### **Measure and alter sensitivity to light & amount of light entering camera**

As most smartphone cameras have a fixed aperture (or *f* stop) they can only alter exposure by changing shutter speed and/or altering the sensors sensitivity to light (ISO). Forcing your camera app to display both shutter speed and ISO will help you to get the very best images by helping you understanding why an image is suboptimal. High ISO settings will allow image capture in low light conditions e.g. when imaging a slit beam with your macro lens but will add grain and loss of fine detail. Low shutter speeds will lead to camera shake affecting your all-important focus.

In general aim for:

- the lowest possible ISO (usually 25) and try and avoid using ISO >400.
- a shutter speed of 1/50th second or faster

### **Optimise App settings.**

Available customisation settings vary between apps however the following are useful to consider:

- File format - JPG (100%) and RAW or DNG if available
- Set maximum image capture resolution
- Save location - save to camera roll and not to app
- Manual focus - turn on, this will allow you to set your focus at infinity(for fundus) or at the MFD (for distant direct cornea and lens photography). This setting will stop the camera “hunting” for the right focal point.
- “touch/tap to focus” and “touch/tap to set exposure” - turn on
- “Volume snap” –turn on, this allows you to press the volume buttons to take images.
- “live exposure” – turn on, this will display your ISO and shutter speed and help you decide if your LED illumination needs to be altered
- Focus peaking - turn on
- Geotagging - turn on, always remember where you were when you took the image – a real help when trying to locate images if you work at different locations
- EXIF and social tags - turn on and put your name / clinic
- Shutter sound - turn off

## **Hints and tips for successful smartphone photography**

1. Keep your phone warm (in your pocket) if using outside – if not the lens will steam up when you get close to the eye (and the battery won’t last as long).
2. Buy a power pack to stop your phone going flat just when you need it.
3. Use a cloud storage service and install the app on your phone, select auto-upload in the cloud app – this way you’ll never lose that vital image even if you lose or break your phone.
4. Practice fundus photography on anaesthetised or euthanized patients
5. and anterior segment photography on your friends and family.

## **Taking your first Smartphone pictures: “whole eye” and “macro” photography.**

There is often a temptation to try and obtain a single image of the whole of the eye hoping to give us all the information we wish from a case. Whilst this may offer a good overview the addition of macro images allows us to look at anatomy and pathology in greater detail. Both types of image are thus complementary and I expect to take both. With small animal funduscopy we are used to this concept using the indirect ophthalmoscope to get an overview of the fundus and the direct ophthalmoscope to allow detailed examination, think of it the same way.

Smart phones have increasingly impressive camera technologies however despite these improvements they are near universally poor at obtaining images of the small animal eye which fill the frame and macro images (displayed image magnified larger than life size).

## Smartphone “whole eye” photography.

We can often obtain sufficiently close up images of the large equine eye to obtain near maximal clinical information especially when examined using the relative magnification of a computer monitor.

Where phones struggle to take an image close enough and large enough for the equine eye to fill the screen I will routinely use one of two approaches to obtain life-size images of the equine eye.

Option 1: Digital zoom - easy, allows near coaxial illumination with your phones LED but loses information as not using whole of sensor.

Option 2: Low power macro lenses - easy, may not allow near coaxial illumination as a lens required (adding the 0.67 wide angle lens to the macro lens in your pack will often be sufficient) but will allow full use of sensor without digital zoom, maximising clinical info.

## “Distant direct phoneoscopy (DDP)”- when it starts to get exciting

Smartphone photography as a clinical tool starts to become exciting when we start using the continuous near coaxial illumination which only a direct or indirect ophthalmoscope or fundus camera usually allows us.

Equipment:

1. Smartphone with a built in LED light
2. An app which allows light to be on whilst acquiring an image

Skills:

1. Understand the concept of the visual axis
2. Know the minimum focal distance of your smartphone
3. Know how to alter illumination intensity
4. Know how to alter exposure on your app.

Step 1: Light on

Step 2: Phone at arm's length from eye to obtain tapetal reflection

Step 3: Assess (and record) PLR by moving light away from pupil

Step 4: Use digital zoom to get pupil to fill your screen.

Step 5: Change angle of view to assess tapetal reflection outside of the visual axis (superior, inferior, nasal and temporal)

Step 4: Move Phone close to eye, aim to position so the phone is as close to the cornea as it can get and still focus (fixing the focus at the MFD using either the “macro” setting or manually will make this easier). Ensure not using digital zoom at this stage.

Step 5: Move phone slowly forward moving the focal point through the visual axis.

Step 6: Repeat step 5 assessing tapetal reflection outside the visual axis

Step 7: If identify lesions - use digital zoom to enlarge, examine and ensure correct focus before record.

# Practical session 1: “getting the basics right”

<b>Key skills</b>
<ul style="list-style-type: none"><li>• Learn how to alter focus</li><li>• Learn how close your camera can focus (MFD)</li><li>• Learn how to turn your phone light on whilst taking images</li><li>• Experiment with “distant direct phoneoscopy”</li></ul>
<b>Equipment needed</b>
<ul style="list-style-type: none"><li>• Smart phone</li><li>• Camera app which allows light to be in “torch mode” whilst capturing images</li><li>• Eye model set up in “anterior segment” mode. (1) lid able to hold slides (2) retinal image in slot at bottom of model.</li></ul>

**NOTE:** if struggling with your camera app try using your phone’s pre-installed video app - turning the light on and off is usually straightforward, some apps will allow “tap to focus” and some will also allow you to take still images whilst recording. However... you will get better images using a camera app.

## Task 1: Learn how to focus

Focus on table , focus on furthest point in room.

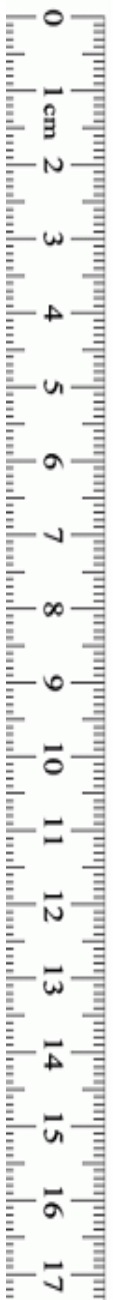
Tips:


Autofocus by tapping on the screen

Manual focus (where available) - select macro  for closest focus point and infinity (mountains) for furthest focal point.

## Task 2: Identify your smart phones minimum focal distance (MFD)

Using the focus chart below work out the closest distance you can clearly focus and using your hand as a measure record it on the ruler. **Remember your MFD it’s the key to successful images.**





### Task 3: Task Whole head photography - your first step to using distant direct phoneoscopy

With a partner take 2 images of their face from the front one with no flash and one with the phone in “torch mode” (the LED turned on continuously).

Tips:

- focus on eyes
- “patient” looking towards you

Look for:

- Asymmetry
- Corneal reflection (on the unlit image)
- Red reflex (anisocoria, opacities in visual axis on the illuminated image)

### Task 4: “Whole eye” photography

Using first your model eye and then your partner’s eye, record an image of the eye which fills the screen (use digital zoom), with and without the light turned on continuously.

Tips:

- focus on lateral canthus of your partner and on the model lid if struggling to get focus
- try forcing your phone to focus at its MFD (using the macro setting of available or manual focus)
- ensure partner directs gaze at you
- ensure perpendicular to the cornea of your model
- to reduce miosis and increase the size of your red reflex hold phone at arm’s length and use digital zoom.

Look for:

- Asymmetry
- Corneal reflection (in the unlit images particularly)
- Red reflex (anisocoria, opacities in visual axis)

## 2: Anterior segment photography

### Imaging the anterior segment, approach, equipment and skills needed

My approach to imaging all parts of the eye is to try and tell the story of my examination. This is particularly relevant for anterior segment photography. Your examination should always ask a number of questions and your photography should document the answers. Different techniques may be required to answer each question and I expect to obtain multiple images of the same lesion taken in different ways.

### Equipment needed

- Smartphone:
  - Phones with larger light to lens distances allow option to use the phone's LED which can be really helpful for posterior lens lesions
  - App which allows manual focus or macro setting (which sets focus to the minimum focal distance)
- third party macro lens.
  - "10-12 x" magnification sufficient
  - glass, coated lenses preferable.
  - Better quality lens give less spherical aberration.
- Modelling light e.g. pen torch. Needs to be:
  - small enough to hold in non-dominant hand whilst supporting the phone
  - able to give a variably focussed light beam
  - variable intensity ideal e.g. LED lenser head torch (model H3.2 or similar)

### Skills required

1. Distant direct phoneoscopy (see earlier)
2. Smartphone Macro Photography
3. Slit lamp photography

### Macrophotography - "using your smartphone like a digital slit lamp biomicroscope"

Using clip on macro lenses and a hand held light source you can readily mimic the oblique broad beam slit lamp view whilst taking high resolution images and video.

Tissue topography is often best examined and recorded with the aid of a slit beam however it still often be documented using multiple angles. With the addition of a handheld slit beam (e.g. a monocular slit lamp, pen torch slit beam adaptor or a colleague to use a binocular slit lamp) then many of the slit lamp examination techniques can also be simulated.

Learning to manipulate a small modelling light, smartphone and macro lens simultaneously takes a little practice. Spectacular images are however possible to acquire which would be difficult to obtain without a table mounted slit lamp camera.

## Buying a macro lens

Phone macro lenses are usually simple high dioptr (30-50 dioptr) biconvex lenses which therefore require a close working distance (the focal length of the macro lens). The close working distance can be an advantage however as allows the camera to be supported against either the patient's periorbita or the nondominant hand resting on the face. Complex multi lens macro lenses are available (e.g. Ollocip lenses), some with larger working distances however they are generally bulkier and more difficult to rest against the patient which, in my hands, make them less useful for the fine movements required for focussing in ocular macro photography.

When buying a smartphone macro lenses look for:

- Small size (single lens macro lenses best)
- Consider macro lenses which attach directly to special phone cases, these can be much easier to use as there is no clip to get in the way allowing easier manipulation of the camera and more flexibility with angle of image.
- Ensure lens surround and clip or case are black to reduce corneal reflections (spray them black if not).
- Coated optical quality glass lenses (a green/pink tinge to the glass in oblique lighting usually denotes anti-reflection coatings).

The close working distance (20-30mm) and shallow depth field of simple macro lenses means that stabilizing the smartphone is very important to obtain focussed images. Resting your non dominant hand on the adnexa is a useful technique as it allows you to rest one end of the phone on this hand bridging the gap from phone to patient and allowing precise "micromovement" of the lens to focus on different lesions. This technique should be familiar to you if you use a slit lamp biomicroscope.

## Slit lamp photography

I routinely two different methods to obtain slit lamp images in the field, macrophotography of the slit beam or a slit lamp eye piece "digiscoping" adaptor:

### A: Macrophotography of the slit beam illuminated lesion:

#### **Technique:**

Step 1: Slit beam focussed on lesion

Step 2: Phone and macro lens positioned to image slit beam.

Step 3: Exposure adjusted to maximise image quality (use maximum slit beam illumination, reduce shutter speed to lowest can manage without camera shake, increase ISO if needed but try not to exceed 400)

Tips:

- Video often more useful than stills as the lower resolution of video comes with greater light sensitivity. Still frames can subsequently be grabbed from the video.
- If taking still images then consider using the "live image", "time skip" or "burst mode" options which allow a series of full resolution images to be taken either before or after the image is taken.


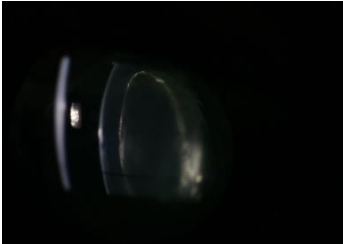
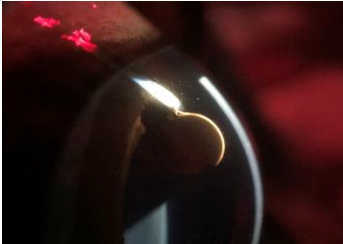
pros:

- full resolution magnified images of the slit beam

- can alter angle of view independently of the slit beam
- can use without a slit lamp by using slit beams produced by direct ophthalmoscope or pen torch with a slit adaptor

cons:

- requires two people or ingenious handling of two instruments

		
<i>Macrophoto, pen torch slit beam adapter, iPhone XS Max and 10x macro lens</i>	<i>Macrophoto, fine beam, KOWA SL17, canon 760D, 50mm f 1.8 and extension tubes</i>	<i>Macrophoto, fine beam, Kowa SL17, iPhone 7plus and 10x macro lens</i>

## B: Slit lamp (“digiscoping”) adaptors:

A quick search for “digiscoping” will reveal a wide range of adaptors which can be used to attach a smart phone to the eyepiece of a slit lamp (or microscope). These allow recording of the slit lamp image direct from the eye piece.

### Technique:

Step 1: Attach digiscoping adaptor to eye piece ensuring phone is hanging down before tightening (otherwise it will rotate the eyepiece changing the eyepiece dioptric power)

Step 2: Check image centred on phone



Step 3: Check image focussed identically on screen and on second eye piece (ideally use your slit lamp focussing rod to ensure both focussed at the focal position of your slit beam)

Step 4: Focus slit beam on lesion either by looking at the screen or using the remaining eye piece with one eye.

Step 5: record image (you may need help with this)

### Tips:

- Use digital zoom to fill the screen with the slit image, this is important to check focus.
- A second person to take the image is helpful
- If not available, take video recordings
- Voice activated camera apps e.g. “Hey camera”\*, “VAPP 2” or “voice enabled camera” allow you to use voice commands to take images (\*and video).
- “tap to snap” option useful - where available, this allows touching the screen anywhere to take an image, useful if you’re having to use your nose to take the image!



	
<p><i>Example of a universal cell phone adapter mount for digiscoping (Amazon.co.uk)</i></p>	<p><i>Example of a Phone specific digiscoping eyepiece adaptor (Carson.com)</i></p>

pros:

- can do with one person
- does not require macro lens
- uses the excellent slit lamp optics

cons:

- large phones make slit lamp unwieldy (I use an ipod touch or an iPhone SE when using this technique).
- you may struggle to find a digiscoping adapter for large phones
- less than full resolution images of the slit beam (usually around 25-40% of maximum available pixels used)
- cannot alter angle of view independently of the slit beam
- taking the image can be fiddly needing either voice activated image capture, a second person or your nose to tap the screen

	
<p><i>Corneal vascularisation, "digiscope" image grabbed from video. Kowa SL17 and universal phone mount, iPhone SE, Dr James Rushton</i></p>	<p><i>Infected stromal ulcer, cropped "digiscope" image. Kowa SL17 and universal phone mount, iPhone SE, Dr James Rushton</i></p>

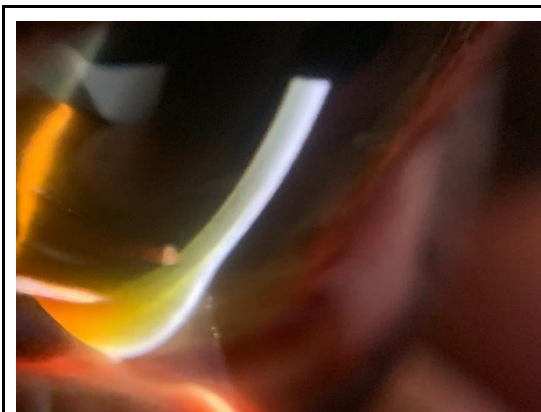# Photographing the cornea.

## Clinical questions

**“Is the cornea reflective ?”** Assessing reflectivity allows a simple non-invasive assessment of the precorneal tear film (PCTF) quality and anterior epithelial health. Normal corneal reflectivity requires a healthy tear film with mature healthy corneal epithelial cells with intact microvilli.

**“Is the lipid layer of the PCTF visible and normal?”** The lipid layer of the healthy PCTF should be easily seen in oblique lighting and with magnification as a rainbow mobile reflection on its surface.

**“Is the PCTF mobile and clear of debris?”** The healthy PCTF takes on a gel like structure between blinks. This gel can be visualised best under magnification by moving the lids across the cornea backwards and forwards over a few mm. The PCTF gel will be seen to move backwards and forwards as the lid is moved and will look a little like waves in sea of molasses. This is seen most readily some 2-3 mm in front of where the lower lid margin touches the PCTF forming the lacrimal lake. In the normal eye this effect can also be seen where the upper lid margin touches the cornea. The distance between the lid margin and a visible PCTF movement is directly related to the volume of the PCTF i.e. with poor tear film volume the movement will be seen closer to the lid margin. This effect is commonly noted following auriculo-palpebral block as reduced blink rate fails to refresh PCTF volume and it thins. Examining this phenomenon can be used as a non-invasive tear break up time assessment technique especially if assessed adjacent to the upper lid. Please note that it is difficult to standardise as AP block is required which in and of itself will reduce tear break up time.



*Limbal corneal oedema with lacrimal lake visible. 10xmacro lens, iPhoneXS, Kowa SL17 slitlamp.*

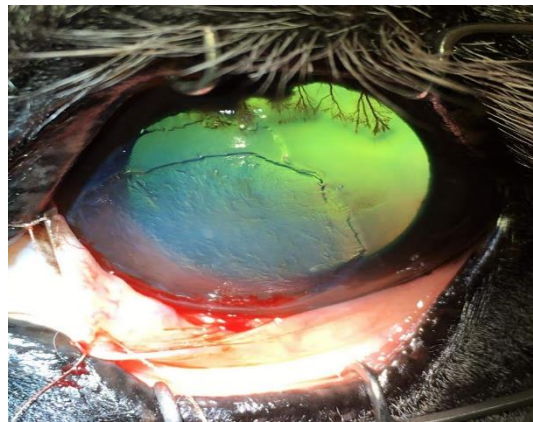
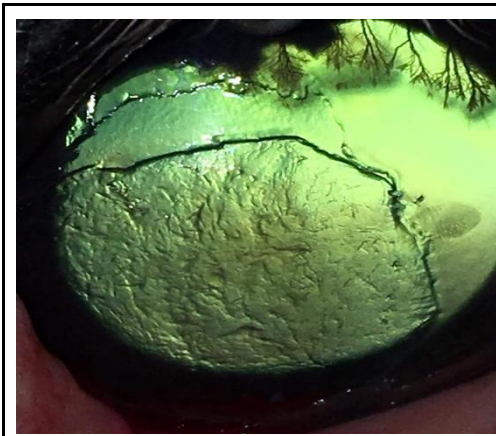


*Lacrimal lake highlighted by fluorescein. Distant direct image (DDP), iPhone XS.*

**“Is the cornea transparent?”** Corneal transparency requires a) a relatively acellular stroma b) regular arrangement of epithelial cells c) regular arrangement of stromal lamellae and d) an avascular stroma. Derangement of the normal corneal anatomy results in loss of transparency. Examples include corneal oedema, corneal infiltrate, keratic precipitates and corneal foreign bodies.

**“Are focal corneal refractive changes present?”** Changes in epithelial, stromal and endothelial thickness will affect the degree to which light is refracted as it passes through these structures. When this is focal light will be seen to refract at the edges of the lesion highlighting the change. This phenomenon can be observed best when near coaxial illumination is used such as in distant direct ophthalmoscopy or distant direct “phoneoscopy”. These changes are readily visible but *will become less obvious as the light intensity is increased*. This helps to differentiate from changes in opacity (where light passage is blocked through the affected area and thus will generally appear

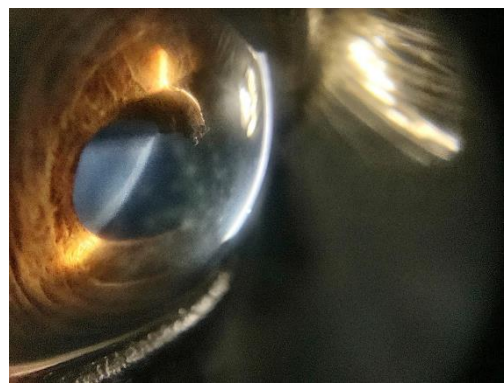
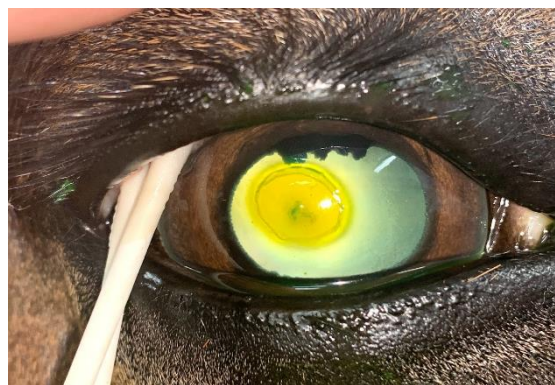dark) which should not change with incident light intensity. Examples of pathology which cause focal changes in corneal refraction include superficial corneal ulcers, corneal facets and focal thinning of Descemet's membrane (linear keratopathy).



*Post Superficial keratectomy: Refractive changes can be noted at the edge of the keratectomy, edge of the epithelium and at the exposed stromal wound. Differentiation from the corneal opacities caused by the dorsal vascular ingrowth requires changes in incident light. iPhoneSE, Dr James Rushton*

*Post Superficial keratectomy: Distant direct technique has been supplemented with an oblique modelling light which highlights subtle stromal opacities but also makes the refractive changes less obvious. iPhoneSE, Dr James Rushton*

**“Corneal opacities present?”** Corneal pathology which blocks (rather than bends) the passage of light include corneal foreign bodies, large corneal vessels and cellular infiltrate. Dynamically adjusting incident illumination (using the rhoestat on your direct ophthalmoscope or altering the smartphone to eye distance) will help to assess the optical transparency of lesions. Please note that very thin or very small corneal opacities may allow light to pass around them with high illumination intensities and may require complex lighting to photograph.


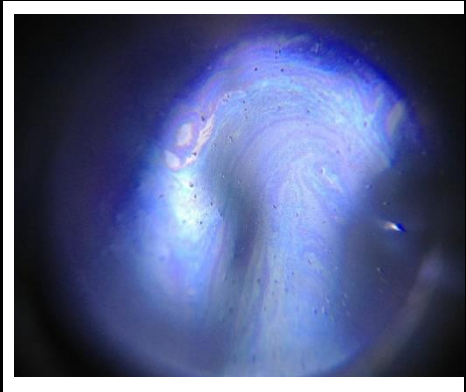



*Cellular infiltrate (dark) associated with axial corneal perforation with superficial ulcer (refractive change noted at edge). Distant direct (DDP) image, iPhoneXS Max.*

*Mid stromal multifocal discoid opacities, these are only obvious when viewed with oblique retroillumination from the iris. Macro lens x10, iPhone XS Max, Kowa SL17. Image lightened to reveal detail.*

## Using photography to assess the cornea:

- 1) **Corneal reflectance:**
  - a) Ambient light alone should cause corneal reflections which are best assessed using no additional light, often taken outside of the stable in daylight.
  - b) Flash photography will give focal corneal reflections and are useful to assess in telemedicine images however their location is difficult to control
  - c) Modelling lights used at an acute angle to the cornea will cause an image of the bulb to be formed. This can be moved across the cornea allowing focal assessment of corneal reflection. If using a ring flash then the large circular reflection is excellent for assessing such changes.
- 2) **Assessing PCTF:**
  - a) Lacrimal lake can be assessed with macro lens and oblique lighting, fluorescein allows it to be seen more readily without magnification. Macro photography of the lake illuminated with fine slit beam usually requires one person to position the slit lamp and a second to photograph. NB attaching the phone to the slit lamp eyepiece allows a single person to image.
  - b) PCTF mobility can be challenging to photo document. Macro lens and video with oblique lighting usually best. (It's much easier to see with the operating microscope)
  - c) "Super macro photography" - using smartphone microscope (x60-x100) attachments with built in light sources can give magnification ratios an order of magnitude more than your simple macro lens. This can image the PCTF and exposed epithelial cells in remarkable detail. The depth of field becomes very narrow making these devices challenging to use.
- 3) **Corneal transparency:** Near co-axial or co-axial lighting is required.
  - a) Smartphone with light turned on continuously (i.e. distant direct phoneoscopy, or video distant direct phoneoscopy)
  - b) DSLR or Compact at arm's length to allow the greater lens to light distance to subtend an angle as close to 90 degrees to the cornea as possible.
- 4) **Focal refractile changes:** Distant direct phoneoscopy with variable illumination intensity required. Altering illumination intensity is best achieved by changing the phone to eye distance and adjusting the image using digital zoom.
- 5) **Corneal opacities:**
  - a) Distant direct imaging allows documentation of lesion density
  - b) broad tangential modelling lighting and macro lens photography allows details of structure, texture and colour. Multiple angles should be taken as this will help to approximate depth of lesion.
  - c) Slit lamp photography usually required to assess depth accurately.
- 6) **Assess subtle corneal lesions:**
  - a) broad tangential modelling lighting
  - b) "sclerotic scattering" - aim a bright focussed light beam obliquely to the limbus adjacent to the lesion. Total internal reflection of the light beam within the cornea can be obtained with careful adjustment of the angle of illumination which will illuminate the stroma closest to the light. Changes may be subtle so image without flash or LED illumination, increase ISO and if needed and possible increase aperture (reduce  $f$  number).

		
<p><i>Corneal facet, lacrimal lake and lipid layer of PCFT, iPhone XS Max, 10x macro lens, oblique lighting.</i></p>	<p><i>Equine PCTF lipid layer, corneal smartphone microscopy, 60x microscope attachment. iPhone4S.</i></p>	<p><i>Microscope attachment in use, note the close working distance required but the remarkable magnification achievable.</i></p>

## Photographing the drainage angle (“grey line”)

The irido-corneal drainage angle of the horse is visible without gonioscopy lenses in the nasal and temporal quadrant. This beautiful part of the anterior segment allows us a direct view of the external part of the aqueous drainage system of the equine eye. Examination of the grey line can be rewarding in the diagnosis of glaucoma, the progression of ERU and the associated risk of secondary glaucoma as well as being a common site for damage following blunt trauma. Pectinate ligament morphology can be examined through the cornea whilst a glimpse of the deeper drainage angle can be obtained by examining the corneal insertion of the pectinates (the grey line).

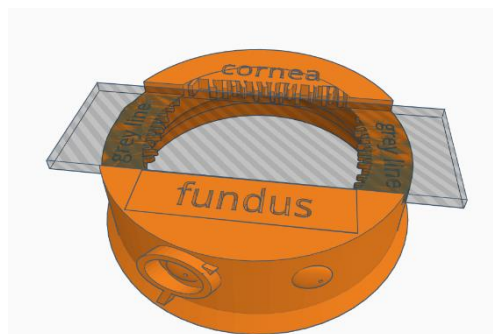
### Clinical questions:

- Is the grey line normal?
- Are the pectinates normal?
- is the iris base normal?

### Using photography to assess the grey line

1. Grey line assessment:
  - a. whole eye image should allow an overview of the whole grey line which should taper gently superiorly and inferiorly but retain a homogenous grey appearance
  - b. macrophotography using oblique illumination aimed directly towards the grey line allows assessment of the pectinate insertions.
2. Pectinate ligament assessment:
  - a. macrophotography using oblique illumination aimed directly towards the base of the iris allows assessment of the pectinate insertions
3. Iris base assessment:
  - a. whole eye image should allow an overview of the iris colour, blunt trauma often leads to stretching of the iris base which may present as white anterior iris stromal opacities parallel to the iridal insertion of the pectinates
  - b. macrophotography using oblique illumination aimed directly towards the base of the iris allows assessment of the pectinate insertions

## Practical session 2: Corneal photography



### Key skills

- Use DD to identify opacities and focal refractive corneal lesions
- Use Macro lens to obtain magnified view of lesions
- Use direct (oblique broad beam) and indirect (retro illumination and “sclerotic” scatter) lighting techniques to document corneal opacities

### Equipment needed

- Smart phone.
- Camera app which allows light to be in “torch mode” whilst capturing images.
- Pen torch +/- slit lamp adaptor.
- Macro lens -make sure unscrew the top lens labelled 0.67 wide angle leaving only the lens labelled “macro”.
- Eye model set up in “cornea mode”. (1) lid able to hold slides (2) retinal image in slot at bottom of model so have a tapetal reflection.
- Corneal simulacrum (painted microscope slide) placed in slide holder.

**NOTE:** you can still use your video app but you get more out of still images so try and use the camera app.

### Task 1: Use Distant direct to identify & image opacities and refractive errors


Step 1: App on, light on, image pupil and obtain a tapetal reflection

Step 2: move phone closer until reach MFD

Step 3: Use digital zoom to fill the screen with the cornea

Step 4: Alter angle of image until tapetal reflection changes and photograph lesions against each different coloured reflection.

Tips:

Use manual focus (where available) to fix focus at MFD or select macro  (where available) which will also fix focus at MFD.

## Task 2: Use macro lens to image corneal opacities

Step 1: attach clip on lens to phone lens ensuring it is centred properly

Step 2: Fix focus at MFD (or select macro)

Step 3: Support phone and lens above model cornea

Step 4: Image opacities

Tips:

- Focus best performed by manually moving the phone with a fixed focus, the autofocus won't like the shallow depth of field the macro lens gives.
- Practice imaging text with the macro lens first.
- Practice supporting the camera and lens above the paper by resting it on your non-dominant hand which in turn rests on the paper.
- Use the same technique for the cornea.
- Practice focusing on first the cornea and then "eye lid margin"

## Task 3: Use oblique lighting to image the corneal lesions

Step 1: Illuminate cornea with pen torch at 45 degrees to cornea surface, held in non-dominant hand

Step 2: Rest phone on edge of non-dominant hand to help steady

Step 3: Move phone up and down to focus and capture lesions

## Task 4: Use retro illumination to image the corneal lesions

Step 1: Direct torch beam through the pupil to produce a visible, bright tapetal reflection

Step 2: Use the macro lens to image the corneal lesions

## Task 5: Simulate "sclerotic scatter like" technique to illuminate and image corneal lesions.

This can be simulated by placing the pen torch directly to the edge of the slide. In the real patient place tip of light source as close to limbus and as obliquely as able aiming for light to enter the cornea peripherally and become totally internally refracted.

Step 1: Place pen torch against edge of short edge of slide

Step 2: Image corneal lesions with macro lens

# Anterior segment photography: Iris & lens

## Photographing the iris & anterior lens capsule

### Using photography to assess the iris and anterior lens capsule.

- 1) **Is the iris too thin?** Distant direct phoneoscopy (DDP) will allow transillumination of areas of thin or absent iris
- 2) **Is the lens capsule transparent?** DDP allows documentation of capsular opacities.
- 3) **Is the iris architecture normal?** One of the cardinal changes of chronic and recurrent uveitis is loss of normal iris architecture. The folds and creases of the anterior iridal stroma and the rim of posterior pigmented iris epithelium visible as the pupillary ruff are best examined with oblique lighting and macrophotography as the shadows produced will illustrate the 3 dimensional structure. Iris masses and nevi can be grossly differentiated, and photo documented with this technique. PIFM's can also be visualised in this way with special attention paid to the pupillary ruff which may be lost or everted and the anterior iris stroma anatomy which can become obscured by PIFM formation.
- 4) **Are the granular iridica normal?** Another cardinal sign of previous or ongoing anterior uveitis is loss of the normally complex surface texture of the granular iridica. This can often be seen as a "smoothing" of the surface as well as gross shrinkage.
- 5) **Are iris rests present?** DDP will identify these within the pupil, dilation should be performed to assess fully. Macrophotography with oblique lighting and retro illumination allows documentation and differentiation from other lesions such as PPM remnants, fibrin and other acute inflammatory debris and capsular and subcapsular cataract.
- 6) **Is that opacity capsular or subcapsular?** Macrophotography can often give enough magnification to decide however slit lamp photography may be needed.

---

## Photographing the lens:

Mydriasis is required to fully assess the lens.

Distant direct phoneoscopy excellent at photographing subtle lesions.

DSLR and compact can mimic by taking from a distance and zooming in .

### Using photography to assess the lens.


**Is fundus examination possible through the lens?** Assessing vision is a complex and subjective process in the horse however a good starting point is to document if the fundus can be imaged clearly. Close direct phoneoscopic examination of the fundus should be attempted and recorded.

**Are there opacities in the lens, if so where?** DDP will document opacities. Video DDP will help to show the position of opacities as will static DDP images taken from multiple angles. Macrophotography of both slit beam illuminated and oblique broad beam illumination will document the nature of the lesions.

**Are there refractive changes in the lens, if so where and are they normal?** Oblique DDP is very helpful for documenting nuclear sclerosis and those odd crinkly epi-nuclear changes we sometimes see

**Is the metabolically active equatorial lens normal? will this cataract progress?** Oblique DDP used to image the equatorial lens allows photo documentation of equatorial lens vacuoles in a way I have yet to reliably imitate with my DSLR.

## Practical session 3: Anterior segment and lens



### Key skills

- Use DD to identify lens opacities
- Use DD to localise lesions using parallax
- Use Macro lens to obtain magnified view of iris face and anterior lens lesions using both direct (oblique broad beam) and indirect (retro illumination) lighting techniques to document lens opacities
- Use slit beam adaptor on pen torch, localise lens opacities using slit beam and image with and without the macro lens

### Equipment needed

- Smart phone.
- Camera app which allows light to be in “torch mode” whilst capturing images.
- Pen torch +/- slit lamp adaptor.
- Macro lens
- Eye model set up in “anterior segment” mode. (1) simple lid (2) retinal image (3) top planoconvex lens with no opacities (4) paper iris (5) bottom planoconvex lens with painted anterior and posterior “lens” opacities.

**NOTE:** make sure you use your video app as well this time as short video clips of distant direct lens views are very helpful for localization.

### Task 1: Use Distant direct to identify & image lens opacities using eye model


Step 1: App on, light on, image pupil and obtain a tapetal reflection

Step 2: focus on the edge of the “eye lids”, move phone closer until reach MFD then move phone so tapetal reflection is in the centre of the screen

Step 3: Use digital zoom to fill the screen with the tapetal reflection

Step 4: Alter angle of image systematically, point towards 12, 3, 6 and 9 o'clock and records lens opacities at each angle. This will aid in lens lesion localisation

Tips:

Use manual focus (where available) to fix focus at MFD or select macro  (where available) which will also fix focus at MFD.

## Task 2: Use macro lens to image iris and anterior lens opacity using eye model

Step 1: Illuminate lens opacities at 45 degrees, hold in non-dominant hand

Step 2: Fix focus at MFD (or select macro)

Step 3: Support phone and lens above model. Move up and down to fine focus.

Step 4: Image opacities

Tips:

- make sure rest camera on your non-dominant hand which in turn rests on the paper.
- if struggling to focus on iris or anterior lens try focusing on the "limbus", locking focus and then moving across face of the iris .

## Task 3: Use retroillumination to image the lens lesions

Step 1: Direct torch beam through the pupil to produce a visible, bright tapetal reflection

Step 2: Use the macro lens to image the anterior lens lesion

Step 3: Remove the lens, ensure LED turned off, use the Distant direct technique to image the retro illuminated lens lesions. NB you may have to increase your ISO.

## Task 4: Simulate slit beam illumination technique to localise and image lens lesions

If available, place the slit beam adaptor on the end of the pen torch, this will give a slit beam which focuses 5-10mm in front of the tip. This can be used to simulate a slit beam lens examination and can be useful for documenting lens lesion position.

Step 1: Place pen torch against edge of short edge of slide

Step 2: Image slit beam as it hits the surface of the first lens, the iris, the anterior lens and the posterior lens surface. Use Distant Direct technique with no LED illumination as you did for retro-illuminated lens lesions.

Step 3: Try using the macro lens to image the anterior lens and iris slit beam reflections.

## Task 5: Use your newfound macro lens skills to image your partners anterior chamber

This is a great way to practice using your macro lens and modelling light.

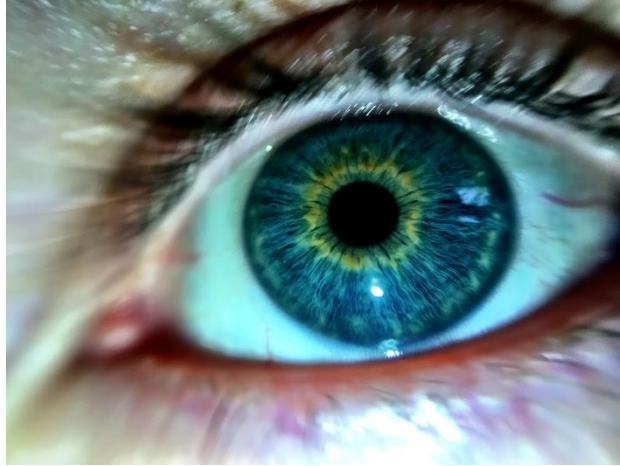
Step 1: Rest you non dominant hand gently beside your partners eye,

Step 2: holding the pen torch in the same hand. Angle the light across the face of the iris.

Step 3: Use your macro lens to image the anterior chamber, make sure you rest the phone on your non dominant hand. Using small movements focus you on first the eye lashes, then the cornea and finally the iris face/pupil.

Step 4: Take lots of images and have fun !

Step 5: Experiment with HDR imaging, and try editing images after wards to highlight the striking colours found even in the simplest iris.



*Oblique illumination, 10x macro lens, iPhone 7plus. Post processed with HDR type filter (Camera +, "Clarity filter")*

# Imaging the posterior segment.

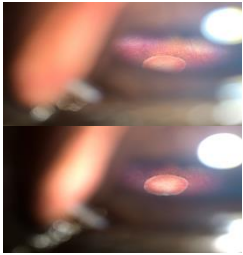
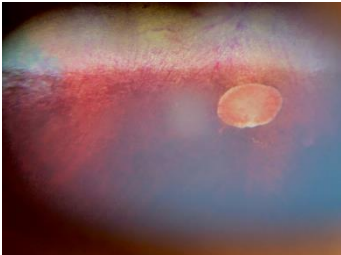

## Imaging the posterior segment, approach, equipment and skills needed

In equine patients I routinely use my iPhone to image the posterior segment without the use of additional lenses or ophthalmoscopes however when the pupil is too small to allow direct imaging of the retina or there are significant visual axis opacities with the iPhone I use a diagnostic lens (Volk pan retinal 2.2) to mimic the indirect technique.

A “sneak peek” of the fundus is usually possible with an unsedated, undilated horse however to obtain the best images a sedated patient, an auriculopalpebral block and a dilated pupil are advised. Note that regular applications of a tear film supplement after AP block are required to refresh the PCTF, corneal drying rapidly reduces visibility of the posterior segment with direct visualisation methods (such as direct ophthalmoscopy and direct phoneoscopy).

Your images should reflect the steps of the ophthalmic examination and should document:

- assessment of the tapetal reflection (colour and brightness)
- abnormalities of the visual axis (cornea, aqueous, axial lens, vitreous, retina)
- abnormalities outside of the visual axis (cornea, peripheral lens, posterior chamber, zonules, ciliary processes, peripheral anterior vitreous, peripheral retina.
- vitreal abnormalities
- optic nerve size shape colour and vascularity
- superficial retinal vasculature
- peri-papillary nerve fibre layer
- non-tapetal fundus
- tapetal fundus

		
<p><i>“Sneak peek” of fundus using direct phoneoscopy, cropped image, iPhoneXS MAX</i></p>	<p><i>Fundus image following mydriasis, uncropped image, iPhoneXS MAX.</i></p>	<p><i>Cropped indirect image, canon IXUS and acrylic 20D diagnostic lens.</i></p>

## Equipment needed

- Smartphone:
  - Phones with smaller light to lens distances allow fundic examination through smaller pupils however with a dilated pupil almost any smartphone can obtain fundic images.
  - Phones with the lens in the corner of the phone are significantly easier to use as it is easier to get the lens close to the cornea.

- App which allows manual focus or “infinity” setting (which sets focus to the maximum focal distance) will stop the autofocus hunting for focus and will also help to estimate emetropia as the fundus should be clearly in focus when the camera is focussed at infinity in the emetropic eye.
- indirect lens\*:
  - \*I almost never use one in large animal smartphone fundoscopic imaging.
  - Anti-reflective coatings will reduce reflection artefacts from the LED

## What’s the best smartphone for imaging the equine fundus?

This changes regularly and I try to assess new iPhones as they come out on the web site ([www.TheEyePhone.com](http://www.TheEyePhone.com)). This said most of the modern iPhones and many android phones allow direct fundic examination in large animals, and small animals with dilated pupils. I currently prefer the iPhone X series phones as their LED is positioned very close to a dual lens camera system allowing optical zoom through a small pupil. This, coupled with greater light sensitivity and image stabilisation, means that I need less light to image the retina and can image more and more through the undilated pupil. NB The larger iPhoneX series phones are fiddly to use with digiscoping attachments due to their size.

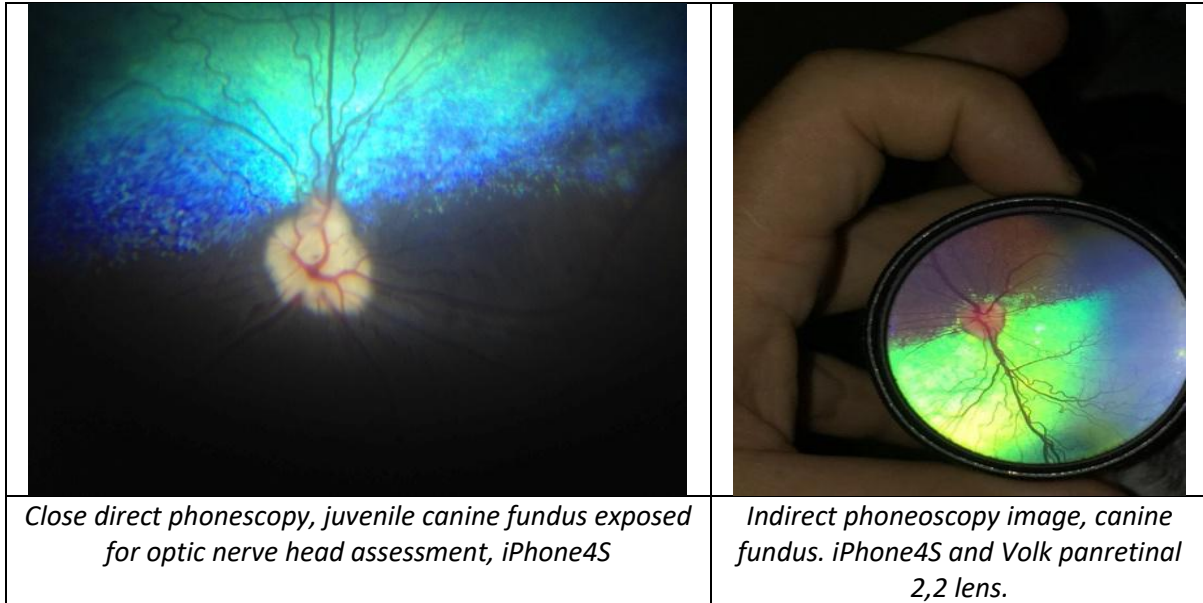
In small animals, particularly if undilated, the light to lens distance of the phone becomes critical. In these patients the iPhone 4,4s,5,5s, SE, 6, 6s, 7, 8 and X series perform better. The tiny 5.5 mm Light to Lens distance of the X series iPhones means that most patient’s fundi can be imaged undilated. This is only nearly matched, to my knowledge, by the iPhone 4s and the Archos diamond gamma with a 6mm light to lens distance.

Budget options to consider if your normal phone isn’t ideal and you wish to buy a smartphone specifically for funduscopy include:

- iPhoneSE. One of the best “modern” iPhones for all types of ocular photography, it’s LED position is only bested by the iPhone4s and the iPhone X ranges for small animal fundus examination and it is perfect for the equine pupil.
- iPhone 4s: Still one of the best phones for direct phoneoscopy to date. Available second-hand and new for <£100. NB will struggle to run recent apps.
- iPod touch. Affordable, light and its lens position will allow direct fundus imaging through moderate sized pupils and all equine pupils.
- All the above are small and light enough to make perfect digiscoping phones for your slit lamp.

## Skills required

1. Distant direct phoneoscopy (see earlier)
2. Close direct phoneoscopy
3. Indirect phoneoscopy (rarely required in large animals)



## Close direct phoneoscopy:

The technique of direct visualization of the retina using close direct ophthalmoscopy with a conventional direct ophthalmoscope can be readily mimicked using certain smart phones with the correct camera application. This technique I refer to as "close direct phoneoscopy".

Using a phone camera with a wide angle lens allows us to directly image a wider retinal area than is achievable using a conventional direct ophthalmoscope. In many cases a direct view of the retina comparable to that previously only obtained using indirect ophthalmoscopy is possible.

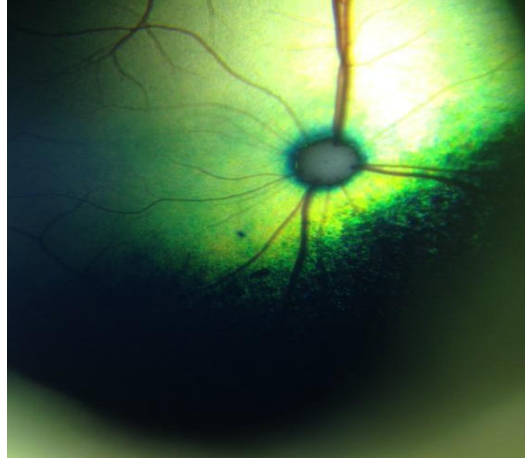
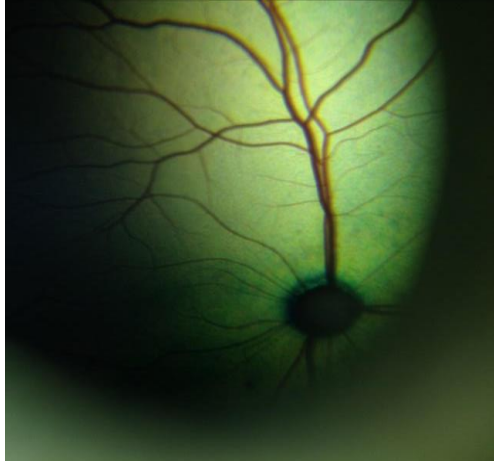
The ideal camera phone for direct phoneoscopy will have:

- 1) a small Light to Lens (LL) distance
- 2) the lens positioned near the corner of the phone.
- 3) a light whose illumination can be varied
- 4) a lens with a wide angle.

## Direct phoneoscopy – a step by step guide:

1. Mydriasis is helpful but not always essential especially if using a phone with a short Light to lens distance and reduced LED illumination.
2. Open camera app – see the "Which App" section at [www.TheEyePhone.com](http://www.TheEyePhone.com) if you don't already have a suitable app installed
3. Turn the LED on continuously – if you do not have a suitable app installed use your embedded video app and turn the light on.
4. Reduce the LED illumination – if this cannot be done within the app then apply multiple (3-6) layers of micropore tape, medicine labels or similar over the LED.

5. Image the tapetal reflection from arm's length- the distant direct ophthalmoscopy technique can be mimicked in this fashion. Zoom in until the tapetal reflection fills the screen.
6. Zoom out again prior to imaging the retina.
7. Move the camera towards the eye – when the eye is closer than the camera's minimum focal distance the retina will start to be imaged.
8. Locking the focus at infinity will stop the autofocus hunting.
9. Position the camera close to the cornea (2-5mm) in the same way you would position a direct ophthalmoscope when performing close direct ophthalmoscopy. Removing your camera case will make this easier.
10. Tap the screen to focus on the optic nerve head.
11. Focus and exposure can be split by moving the focus and the exposure reticle independently. This is very useful for hyper-reflective fundus if your app allows separate focus and exposure (e.g. Open Camera, Procamera, Camera +) then tap the tapetal fundus to avoid overexposure due to the reflective tapetum.
12. Reposition the exposure reticle on the non-tapetal fundus to image.
13. Move camera to image the peripheral fundus in 4 quadrants. You may need to rotate your phone through 180 degrees to image the superior fundus.

	
<p><i>Feline fundus, focus &amp; exposure centred on optic nerve head. Direct phoneoscopic iPhone4S.</i></p>	<p><i>Feline fundus, focus locked on optic nerve head, exposure on tapetal fundus. Direct phoneoscopic image iPhone4S.</i></p>

## Indirect phoneoscopy

This technique is much more challenging to learn than direct phoneoscopy. Similar to the monocular indirect ophthalmoscopy technique the phone light is used to produce a tapetal reflection and the diagnostic lens is then positioned to focus the indirect image in front of the lens. This projected image is recorded on the phone camera. *I rarely use this technique in large animals* but is usually the first technique I will attempt in small animals.

### pros

- Fundic image less affected by opacities in the visual axis e.g. corneal lesions and cataracts.
- Can use through a small pupil
- lens to light distance less critical than in direct fundic imaging

- can use a separate light source if needed

**cons**

- technically more difficult
- requires diagnostic lens
- requires digital zoom to obtain screen filling image with overall reduction in image resolution

## Indirect phoneoscopy– a step by step guide:

The light to lens distance has little effect in this technique making it suitable for nearly all phone cameras.

1. Mydriasis is helpful but not always essential - a dark room and reducing the LED intensity is usually sufficient to image the retina.
2. Work out your camera's minimum focal distance before you start – this will help you get the best image possible later.
3. Open camera app
4. Turn the LED on continuously – if you do not have a suitable app installed use your embedded video app and turn the light on.
5. If necessary, reduce the LED illumination – if this cannot be done within the app then apply multiple (3-6) layers of micropore tape or similar to the LED.
6. Hold diagnostic lens between thumb and forefinger, rest your little finger on the lateral orbital rim and hold the lens away from the eye.
7. Image the tapetal reflection from arm's length
8. Once the tapetal reflection is imaged move the diagnostic lens in front of the eye in the same manner as you would with indirect ophthalmoscopy – a retinal image should be visible focused 50mm in front of the lens (assuming a 20Dioptre lens is used).
9. Move the camera towards the image until the camera is positioned with its minimum focal distance positioned 50mm in front of the lens.
10. Zoom in until the retinal image fills your screen.

**Aside:**

***Imaging the fundus with DSLR & Compact cameras***

- *Fundus photographs are possible using a compact or DSLR with an indirect lens*
- *A light source can be secured to the lens of a digital SLR or to the body of a compact camera (e.g. pen torch and rubber band)*
- *Mydriasis is essential*
- *Practice and patience are required, it can be a tricky skill to master*

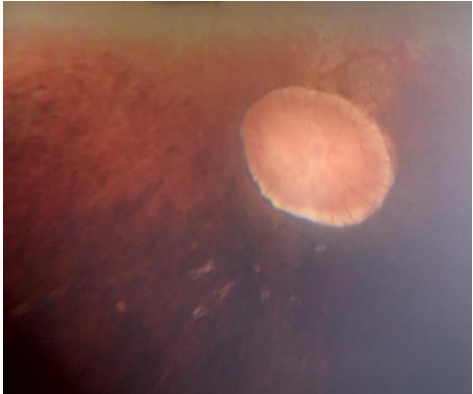
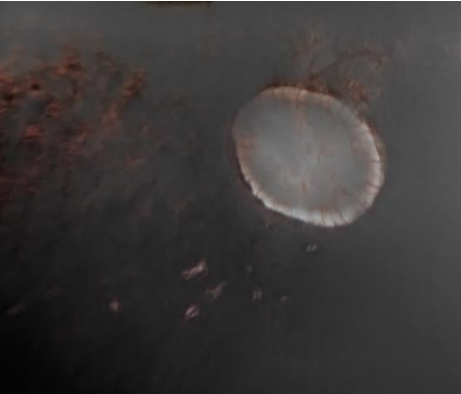
## Photographing the vitreous

Vitreous pathology is common in the equine patient and can be an important clinical finding when assessing the significance of other posterior segment pathology. Imaging the anterior vitreous can be done using slit lamp examination using techniques similar to the anterior segment although most macro lenses have too short a focal length to image a vitreal slit beam easily. A more useful technique is that of video distant direct phoneoscopy as the it best documents the mobile nature of most vitreal changes.

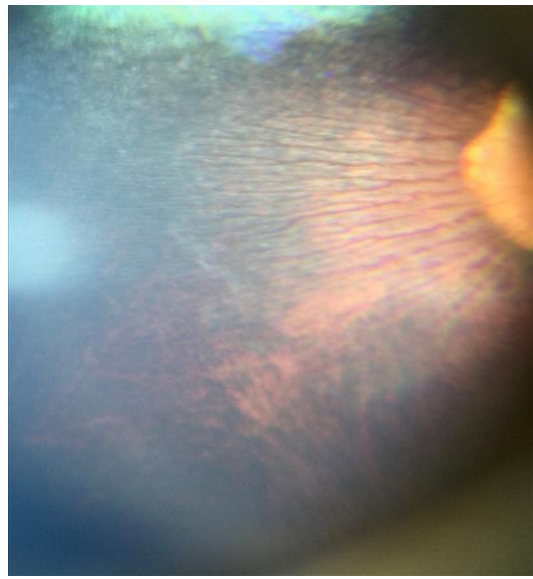
# Photographing the fundus

Using photography to answer clinical questions about the fundus:

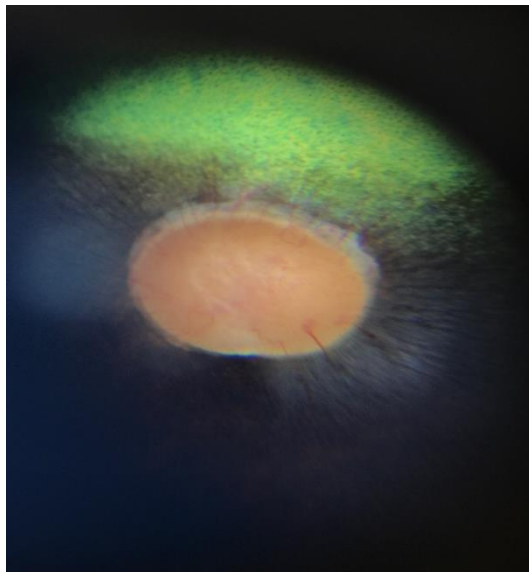
1. **Is the visual axis clear?:** Distant Direct Phoneoscopy, performed lateral to the horses head.
2. **Is tapetal reflectivity normal?** Distant Direct Phoneoscopy, performed from the front of the head so that both tapetal reflections can be seen at the same time.
3. **Is the optic nerve head normal?** Close direct phoneoscopy, use optical zoom (if available) and digital zoom to image the optic nerve head. Use focus peaking if available to ensure best focus. Reduce exposure if needed to maximize details of the cribriform plate.
4. **Is the retinal vasculature normal?** Close direct phoneoscopy, use optical zoom (if available) and digital zoom to image the optic nerve head. Use focus peaking if available to ensure best focus. Post processing of the image to increase contrast can aid assessment of the tiny superficial retinal vessels found in the horse. reducing colour saturation and increasing contrast in post processing can aid this assessment

	
<p><i>Optic nerve head, equine and small bullet lesion iPhone XS Max</i></p>	<p><i>Optic nerve head, equine and small bullet lesion post reduction colour saturation and increased contrast to highlight retinal vasculature. iPhone XS Max</i></p>

**Is the “peripapillary nerve fibre layer” normal?** A superficial retinal structure which may be the nerve fibre layer becomes visible on phoneoscopic examination in two wing shaped arcs either side of the optic nerve head mirroring the location of the superficial retinal vessels. If this is indeed the nerve fibre layer I assume that its appearance is due to myelin in the ganglion cells. This wing like appearance appears to be a feature of a healthy retina as it becomes disrupted in retina pathology in this region. This feature is not generally visible with conventional direct or indirect ophthalmoscopy which I suspect is because these techniques rely on illumination which is closer to the viewing axis than is possible with direct phoneoscopy.

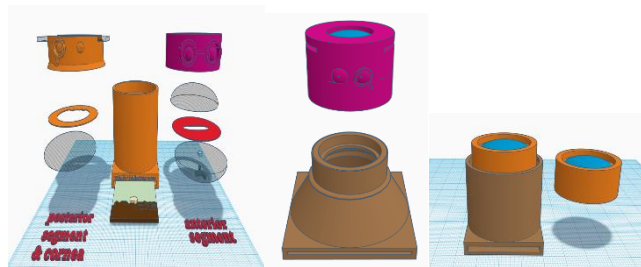


*Presumed myelination of peripapillary nerve fibre layer , iPhone4S*



*Presumed myelination of peripapillary nerve fibre layer. iPhone4S*

# Practical session 4: Posterior segment photography



## Key skills

- Use Distant direct phoneoscopy to identify and document posterior segment abnormalities
- Use Close direct phoneoscopy to image the retina

## Equipment needed

- Smart phone.
- Camera app which allows light to be in “torch mode” whilst capturing images.
- Eye model set up in “posterior segment” mode. (1) single biconvex lens\* (2) retinal image (3) +/- paper iris model to try imaging through smaller pupils
- \*Each model type has a slightly different lens,
  - the large equine training eye has a 50mm glass lens
  - the small animal training eye with a small fundus image uses a 25mm acrylic lens in a tubular holder, place lens uppermost in the top of the model
  - the small animal training eye with a larger fundus image (and a conical shaped body) has the fundus viewing lens built in to the same lid we used to hold slides for corneal imaging

**NOTE:** make sure you use your video app as well this time as short video clips of distant direct lens views are very helpful for localization.

## Task 1: Use Distant direct to identify anterior vitreal or peripheral retinal abnormalities using eye model

Small fibres of residual printing fibres are present inside the model, try and localise these, this is the same technique you would use for imaging vitreal lesions in the living eye.

Step 1: App on, light on, image pupil and obtain a tapetal reflection

Step 2: focus on the edge of the “eye lids”, move phone closer until reach MFD then move phone so tapetal reflection is in the centre of the screen

Step 3: Use digital zoom to fill the screen with the tapetal reflection

Step 4: Alter angle of image systematically, point towards 12, 3, 6 and 9 o’clock and records lens opacities at each angle. This will aid in lens lesion localisation

## Task 2: Use close direct phoneoscopy to directly image the fundus

In the live animal a dilated pupil, a quiet patient and an auriculopalpebral block make imaging the fundus simple. Imaging through a small pupil can also be rewarding and can be practiced using the paper iris models to give different pupil sizes. Start off with no iris at all to convince yourself how simple the technique really is then add small pupils to experiment with techniques to image the fundus fully.

Step 1: App on, light on, image pupil and obtain a tapetal reflection

Step 2: Fix focus to infinity

Step 3: Move phone towards eye model, notice that you start to see the fundus some distance from the eye

Step 4: Move phone as close the eye as you are able, note that the closer you are, the wider the image.

Step 5: Identify all of the target words, they are in the peripheral fundus

Step 5: Experiment with adjusting exposure for the optic nerve head, the tapetum and the non tapetal fundus

## Task 3: Use indirect phoneoscopy to photograph the fundus

In the live animal a dilated pupil, a quiet patient and an auriculopalpebral block make imaging the fundus simple. Imaging through a small pupil can also be rewarding and can be practiced using the paper iris models to give different pupil sizes. Start off with no iris at all to convince yourself how simple the technique really is then add small pupils to experiment with techniques to image the fundus fully.

Step 1: App on, light on, image pupil and obtain a tapetal reflection

Step 2: Fix focus to infinity

Step 3: Move phone towards eye model, notice that you start to see the fundus some distance from the eye

Step 4: Move phone as close the eye as you are able, note that the closer you are, the wider the image.

Step 5: Identify all of the target words, they are in the peripheral fundus

Step 5: Experiment with adjusting exposure for the optic nerve head, the tapetum and the non tapetal fundus

Appendix: Non smart phone ocular photography, online resources and understanding magnification and macro terminology.

## Which camera to buy? What other cameras do I use and some useful tips.

Modern digital cameras allow excellent quality macro photography with little practice or financial outlay. The use of flash allows critical evaluation of structures posterior to the pupil as well as the use of retro-illumination to highlight subtle corneal lesions. The high resolution now readily available allows magnified views equivalent to that obtained with high end slit lamps with the added advantage that the patient only has to stay still for the few seconds required to focus and take the image.

Almost any camera can be a useful clinical tool with a little thought and a basic understanding of photography. The best camera for the job is the one you have on you so don't worry if you don't have the latest top of the range DSLR – today is about getting the most out of whatever camera you have to hand.

As to which one to buy, there is no simple answer to this question. I use a compact, a DSLR and a camera phone on a daily basis. I routinely use a canon 760D DSLR (£500) with a 50mm prime lens (Yongnuo F1.8, £50), a series of extension tubes (£25) and the canon's on camera flash for my series of "standard" eye images. In the normal eye I use my smartphone to obtain "distant direct" images of the visual axis and "direct phoneoscopic" images of the retina. I will also always carry a small canon IXUS compact camera in my coat pocket as the close proximity of the lens to the flash allows retro illumination of corneal and lens lesions with the dilated pupil.

### Digital SLRs

#### Advantages

- Rapid focusing.
- Minimal delay between shots.
- Burst mode useful for moving patients.
- Good quality lenses improve image quality.
- Availability of dedicated macro lenses.
- Standard macro capability of most included lenses often enough.
- Crop sensor cameras will give a closer image than a full sensor camera
- NB The newer the DSLR the more light sensitive the CCD will be, it is worth upgrading.

#### Disadvantages

- Cost, size and fragility.
- Built in flashes further from cameras "visual axis" thus often require more distant position to obtain good tapetal reflex.

### Compact digital cameras

#### Advantages

- Cost, often more robust, pocket sized.
- Flash often much closer to optical axis allowing macro photography with tapetal reflection.

- Ease of use.

#### **Disadvantages**

- Slower to focus, slow to ready for next shot – however newer compacts better than ever before.
- Some noisy to focus which can reduce compliance when used at closest position
- Not all have ability to select spot focus.

## **Camera phones**

#### **Advantages**

- Always with you.
- Increasingly impressive camera technologies – especially light sensitivity.
- Allows rapid telemedicine referrals
- Flash often very close to lens and therefore allows use as a direct ophthalmoscope where able to have camera LED continuously illuminated allowing distant direct views and close direct fundic views.
- Video function often readily available
- Accessible for owners for use in monitoring where appropriate

#### **Disadvantages**

- Macro photography may be limited without use of additional lenses
- LEDs often very bright requiring adjunctive methods to reduce illumination intensity.

#### **Tips which make my photographic life easier include:**

- Always keep an SD card in your wallet
- Buy a USB camera battery charger and spare batteries, and keep them plugged in in the car
- Use wireless SD cards, or a DSLR with a wifi capability
- Use a camera with GPS tagging built in
- Buy a SDcard adapter for your phone to allow transfer to your phone and then automatic upload to your cloud based storage (e.g. Google photos).

## **General tips for taking ophthalmic photographs with a digital (non-phone) camera.**

#### **FLASH**

- Force flash always on, turn red eye reduction off

#### **FLOWER**

- Macro setting on
- Zoom off (select widest angle lens allows)

#### **FOCUS**

- Allow camera to focus lock before photograph taken, usually half depress button and wait until an audible signal or focusing grid or spot changes colour to confirm focused.
- Practice- ensure comfortable with minimum focus distance by using e.g. text
- Spot or centre focusing selected (without cameras tend to focus on the prominent equine eye lashes)

- If autofocus focuses on corneal reflection then focus at lateral canthus, obtain focus lock before moving back to axial view of the eye to obtain focus at level of iris.

### Other tips

Become familiar with your camera settings

- Shutter priority
- Aperture priority
- Programme mode
- Full manual
- Flash settings
- ISO settings
- Focus settings
- Metering settings

Increased shutter speed decreases movement blur

Increasing ISO can reduce shutter speed, but this may reduce image quality

Clean discharge and remove hairs from cornea

Avoid holding lids open if possible as will obtain corneal reflection of hand and distort lid anatomy

Avoid wearing white or red clothes as these will often cause striking corneal reflections

Take note of environmental lighting, e.g. position of ceiling lights

## Ophthalmic photography - my digital camera settings

### Macro photography

- Macro setting - for compacts
- Reversing ring - occasionally use to get more extreme magnification with a shorter lens than multiple extension tubes as allow me to use pop up flash still.
- Extension tubes = preferred, cheap, robust.
- Macro lenses = can be expensive

### Lighting

- Modelling lights - for subtle corneal and anterior lens lesions, need to increase ISO and increase aperture
- Pop up / onboard flash, predictable and easy – rotate camera to move corneal reflections if covering area of interest.
- Ring flash – ware corneal reflection as cannot change however some flashes will allow half illumination.
- Off camera flash – wireless triggers are inexpensive and allow great flexibility especially when using a small speed light e.g. Canon speedlight 90EX

○

### Compact camera settings:

- Use Macro setting
- Force spot focus
- Force flash
- ISO 100

**DSLR:**

- 50mm prime lens with extension tubes
- Manual focus – like you would with a slit lamp
- Shutter speed – 1/60, *f* 14, ISO 100.

## Online resources to improve your photography

**Digital photography school** : <http://digital-photography-school.com/> -Free online courses

**Photo net**: <http://photo.net> - Online forum for photography

**Instructables**: <http://www.instructables.com/>

Great resource for do it yourself projects of all kinds. Try searching for:

- Macro lens
- How to make a cheap and easy macro lens
- Ring flash
- DIY flash diffuser

**The Eye Phone**: <http://www.theeyephone.com/> Tim's web site celebrating the smartphone in ophthalmology

**The Ophthalmic Photographers Society**: <http://www.opsweb.org/> Home of the OPS – a group of specialist medical imagers – a great resource for anyone interested in Ophthalmic photography.

## Smartphone macro-photography, understanding magnification vs reproduction ratio:

The terminology associated with macro photography can be confusing. “Reproduction ratio” is usually used to describe the “magnifying power” of DSLR macro lenses where as “magnification” is the term usually used to describe the power of a smartphone macro lens. When magnification is used to describe macro lenses for smartphones it should be noted that it generally refers to the size of the image on the phone screen relative to the object size, as screen size varies between phone the same macro lens would give a different “magnification” on each phone although it would give the same reproduction ratio.

A macro lens sold as “10x magnification” which displays a 7mm object filling a 70mm tall screen would give a displayed image 10x larger than life size. If the sensor on this phone was 7mm tall this lens would have a reproduction ratio of 1:1 that is to say, the captured image is the same size as the sensor.

The same 10x macro lens used on a phone with the same size sensor but with a 60mm tall screen would display an image only 8.5x larger than life but would still have a reproduction ratio of 1:1.

The take home message is that the magnification factor of a smartphone macro lens should be taken as a useful guide and not an absolute indicator of it's ability to magnify objects.

True macro photography generally refers to the process of creating images which are the same size or larger than the sensor of film (i.e. having a reproduction ratio of 1:1 or greater).

With a conventional 35mm (“full frame”) DSLR or 35mm SLR film camera a 35 mm object whose image filled the sensor or film would be said to have a reproduction ratio of 1:1. An object 17.5mm high whose image on the sensor or film is 35mm tall would be said to have a reproduction ratio of 2:1. In a similar way an object 3.5mm tall whose image was 35mm tall would have a reproduction ratio of 1:100.

Most modern digital cameras do not have sensors as large as 35mm however camera lenses are still often described in terms of their performance when used with a 35mm size sensor which can lead to confusion. The size of the sensor does not affect the magnification per se but does have a significant effect of the size of the displayed image and the images effective magnification. As the sensor size reduces the same lens will produce a larger image effectively increasing the magnification of the image. This effect is called the “crop factor”.

To illustrate this point consider a 35mm diameter object, e.g. an eye, and a camera lens which produces a 35mm image of the eye at the back of the camera:

- if the sensor size is 35 mm sensor the image is captured at 1:1 and the whole eye fills the display screen.
- if the sensor size is 23.6 mm high (a Nikon DX “crop” sensor) only 67% of the image of the eye fits on the smaller sensor and is subsequently displayed on the screen. This effectively crops the image. Whilst this cropped part of the image is still captured at 1:1 when displayed it is 1.5 x larger than the same part of the image taken on a 35mm sensor giving an effective reproduction ratio of 1:1.5
- if the sensor size is 22.2 mm high (a canon APSC “crop” sensor) only 63% of the image fits on the sensor as it has been cropped by the smaller sensor. Whilst this cropped part of the image is captured at 1:1 when displayed it is 1.6 x larger than the same part of the image taken on a 35mm sensor giving an effective reproduction ratio of 1:6
- if the sensor size is 4mm high (eg a smartphone sensor) only 11% of the image can be captured, when this is displayed it will give an effective reproduction ratio of a whopping 1:9.

Thus, for the same lens, the smaller the sensor the higher effective magnification of the image you obtain. Lenses designed for macro photography are often expensive thus when we chose a camera with a smaller sensor size we can get much more “bang for your buck”. With the ultra small sensors in smartphones this crop effect means that we can use much simpler macro lenses which when coupled with the smaller sensor sizes can give us spectacular close up images on our smart phones with very cheap macro lenses.

With the small size of the sensors used in smartphones (4x7mm) true macrophotography is easily obtained with readily available cheap smart phone macro lenses advertised as having a 10x magnification factor or greater. Reproduction ratios of as high as 1:10 can be obtained using “100x magnification” smart phone attachments. Achieving the same level of magnification with a traditional DSLR would not be possible even with very specialised and very expensive “supermacro” lenses e.g. the Canon MP-E 65mm 1-5x macro lens (\$1500 +) but would require the use of lens extension systems (e.g. tubes or bellows) which quickly become too bulky to use clinically.