

Tim Knott

The Equine Eye Clinic

Advances in Equine Ophthalmic Surgery

www.TheEyePhone.com www.EquineEyeClinic.co.uk



[Home](#)[Locate a Member](#)[Membership](#)[Resources](#)[Education](#)[Research](#)

Edinburgh, Scotland, EU - 2023



2023 IEOC Equine Ophthalmology Symposium Edinburgh, Scotland

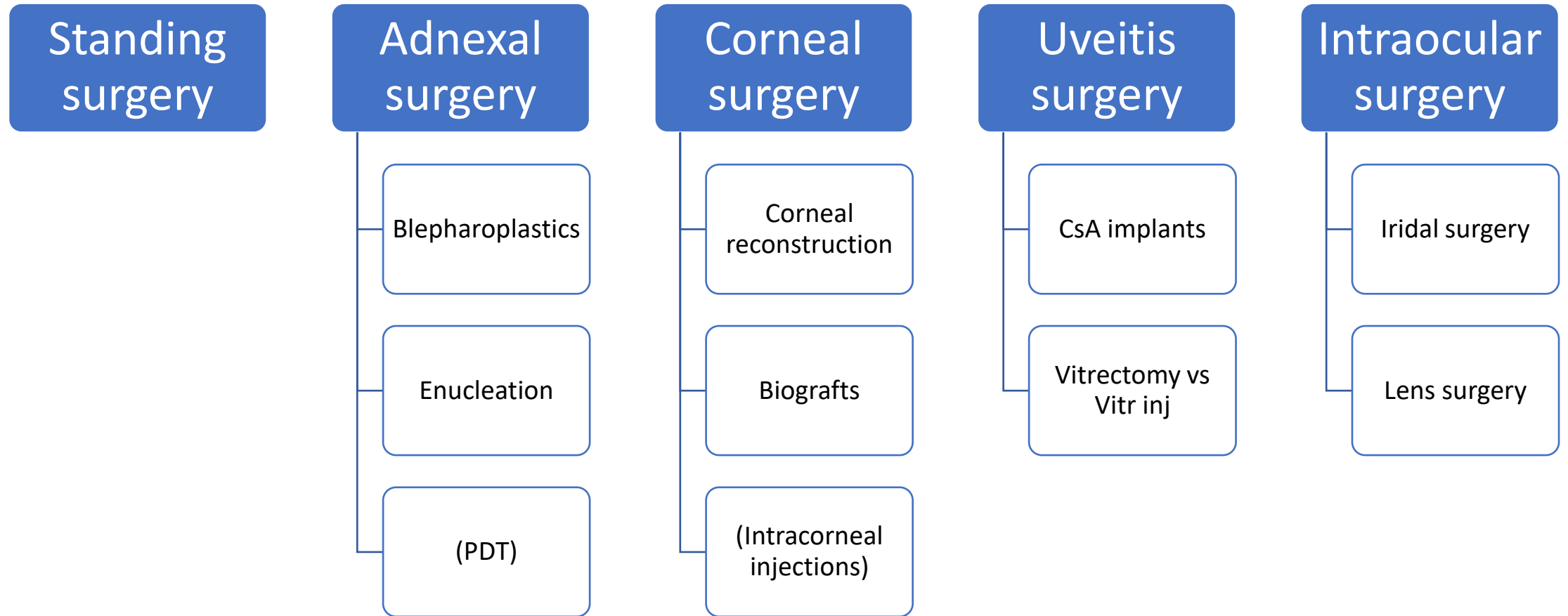
June 1-3, 2023



Quick Links

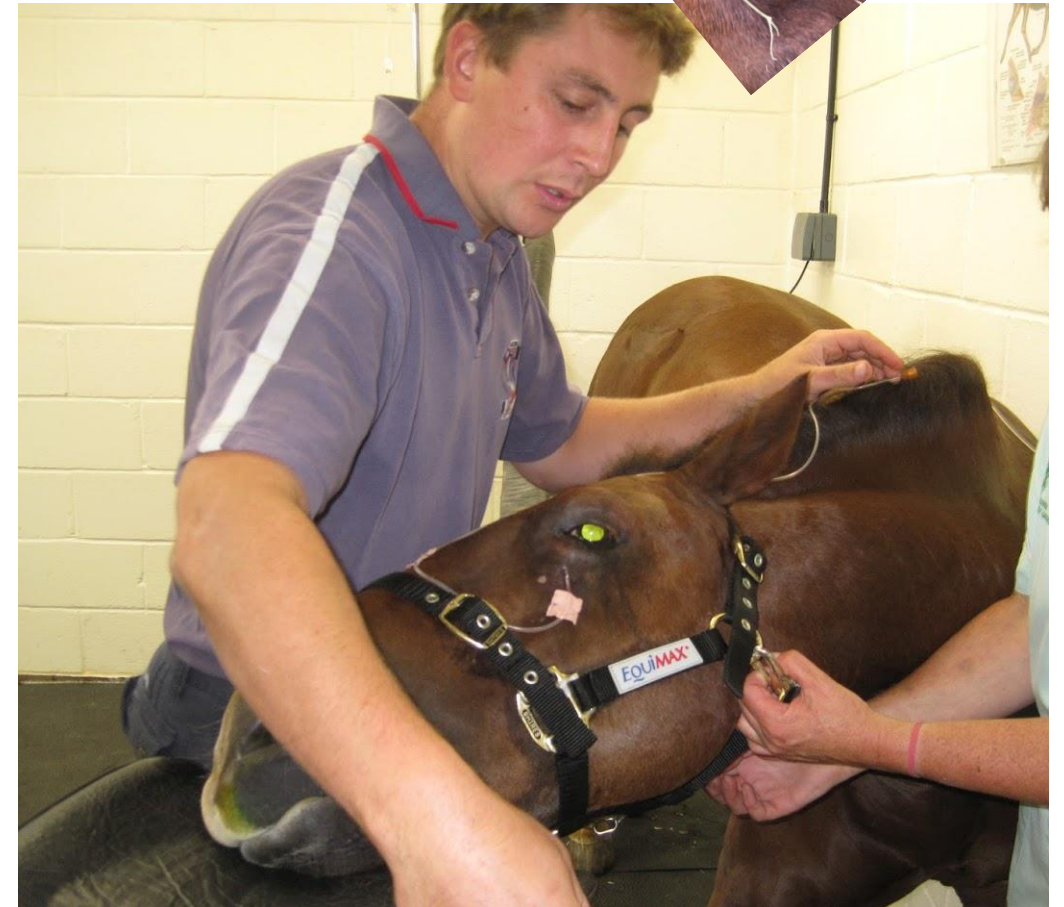
- [Home](#)
- [Forums](#)
- [Forum & Profile Help](#)
- [Industry News](#)
- [Resources](#)
- [Locate a Member](#)
- [What's Your Diagnosis?](#)
- [Member Publications](#)
- [Clinical Articles](#)
- [Glossary](#)

Advances in Equine Ophthalmic Surgery



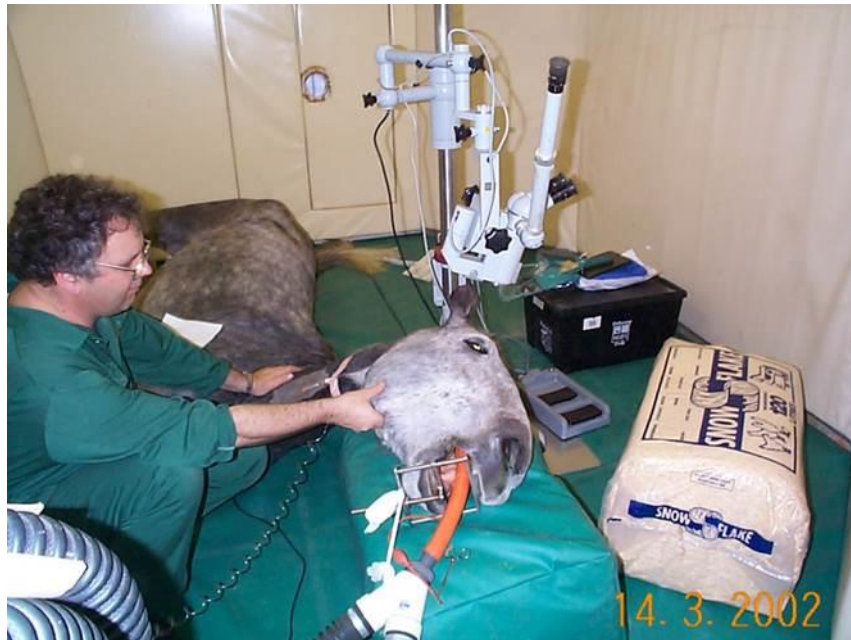What's new in Standing surgery?

- The use of head mounted operating microscopes, regional anaesthesia, multimodal sedative techniques and CRI sedative protocols allows complex ophthalmic procedures to be performed by experienced ophthalmic surgeons including complex corneal reconstruction and placement of intraocular medication devices for the treatment of recurrent uveitis.
- Appropriate blocks and sedation allow more routine surgeries to be performed standing by experienced general surgeons including enucleation, third eye lid surgeries, lid laceration repair as well as indolent ulcer treatment and superficial keratectomy



Equine Ophthalmic Microsurgery

2002



2002



Equine Ophthalmic Microsurgery

2022

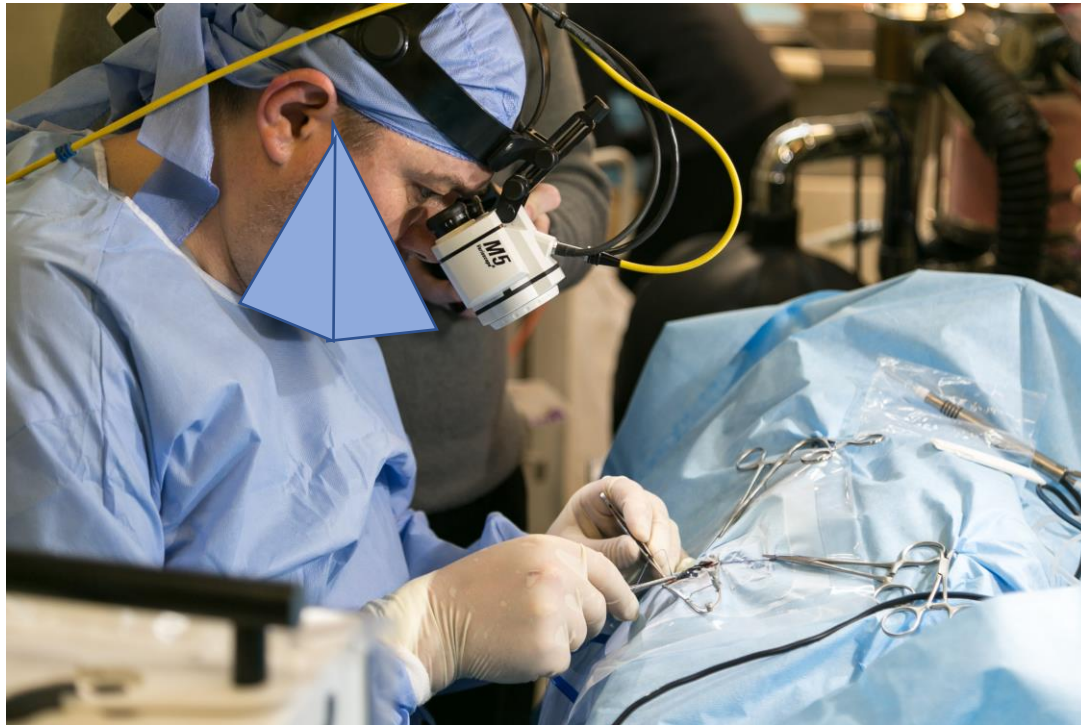


2022

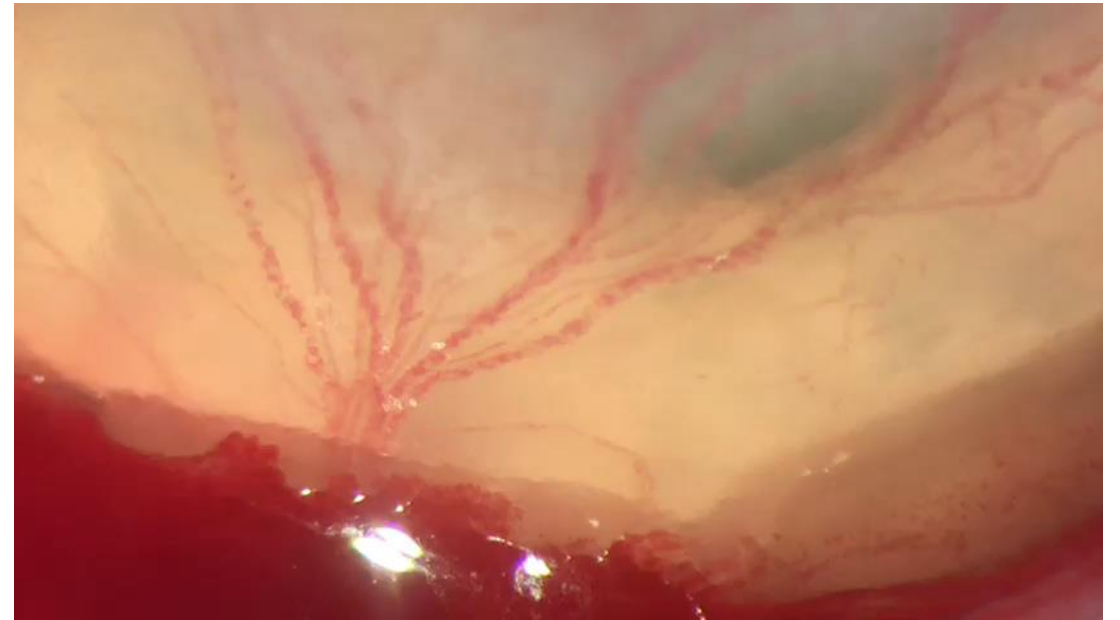


Equine Ophthalmic Microsurgery

2022

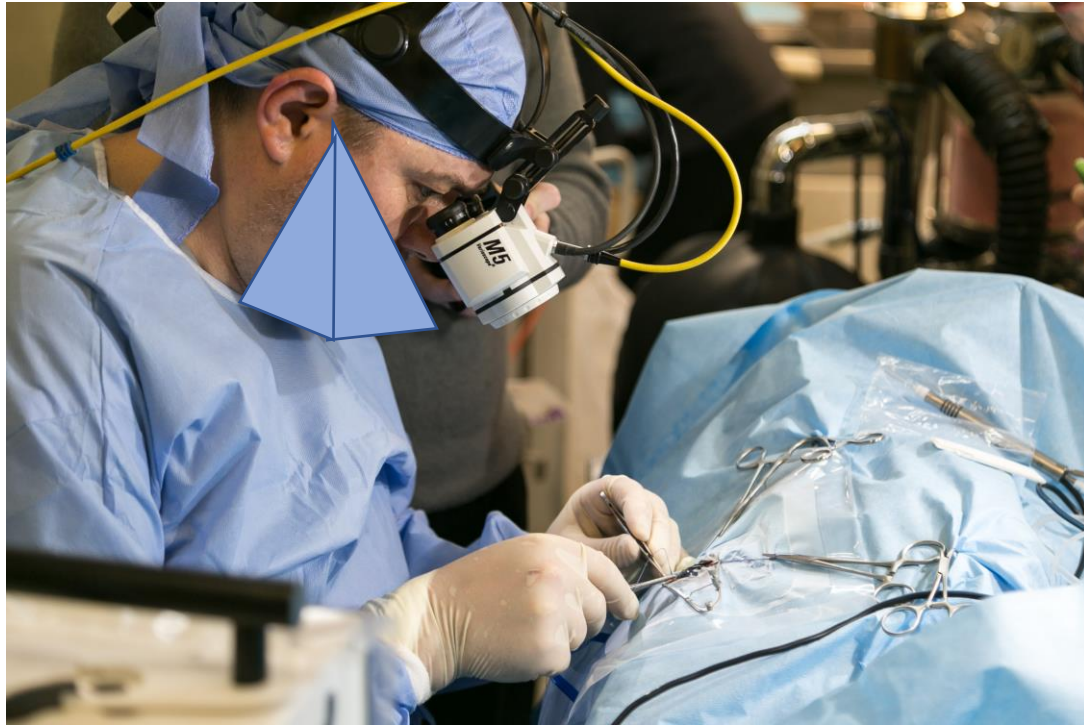


2022




Equine Ophthalmic Microsurgery

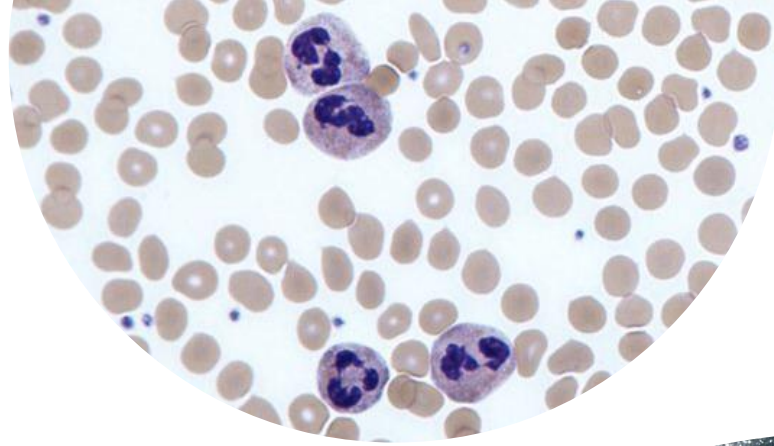
2022



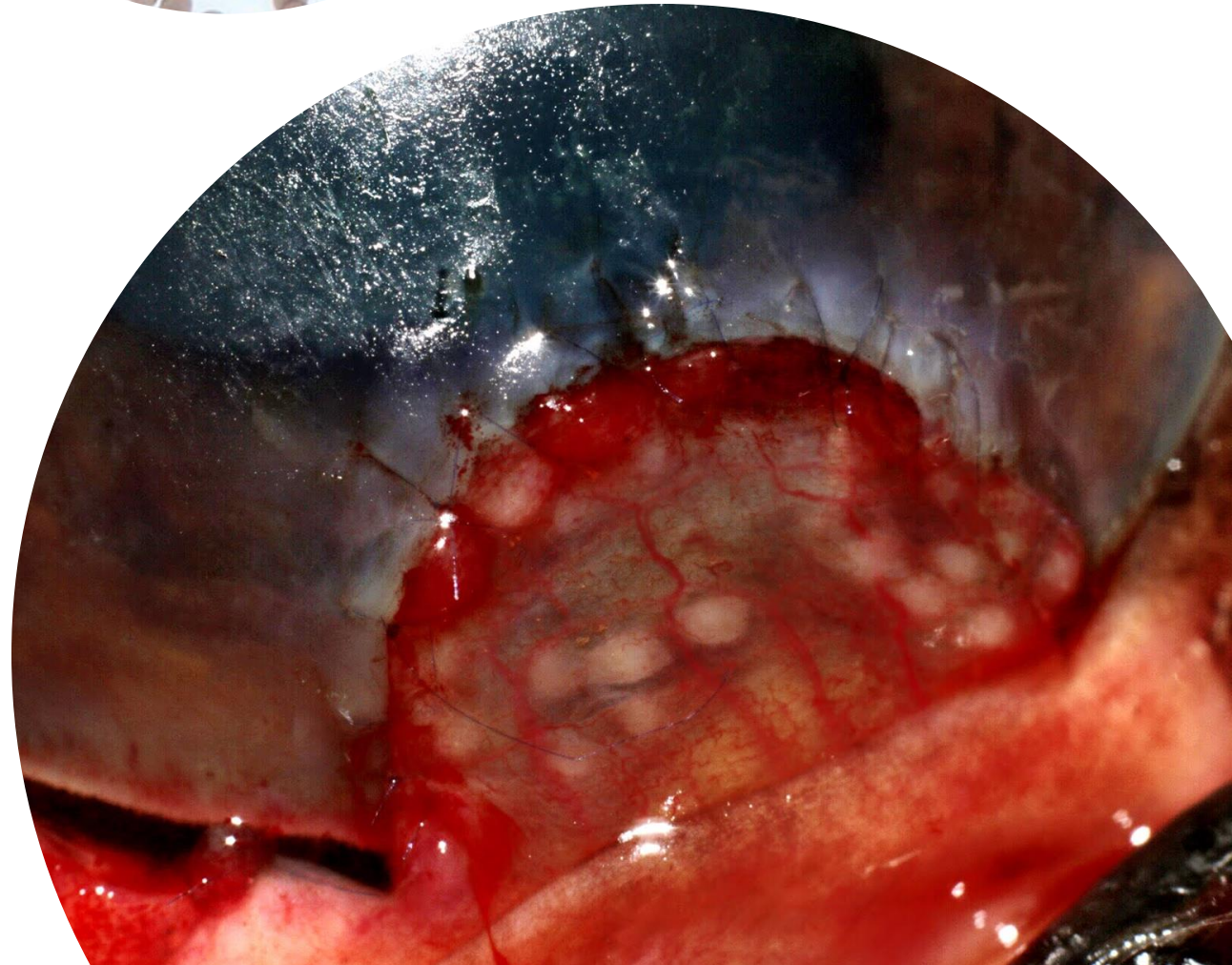
2022



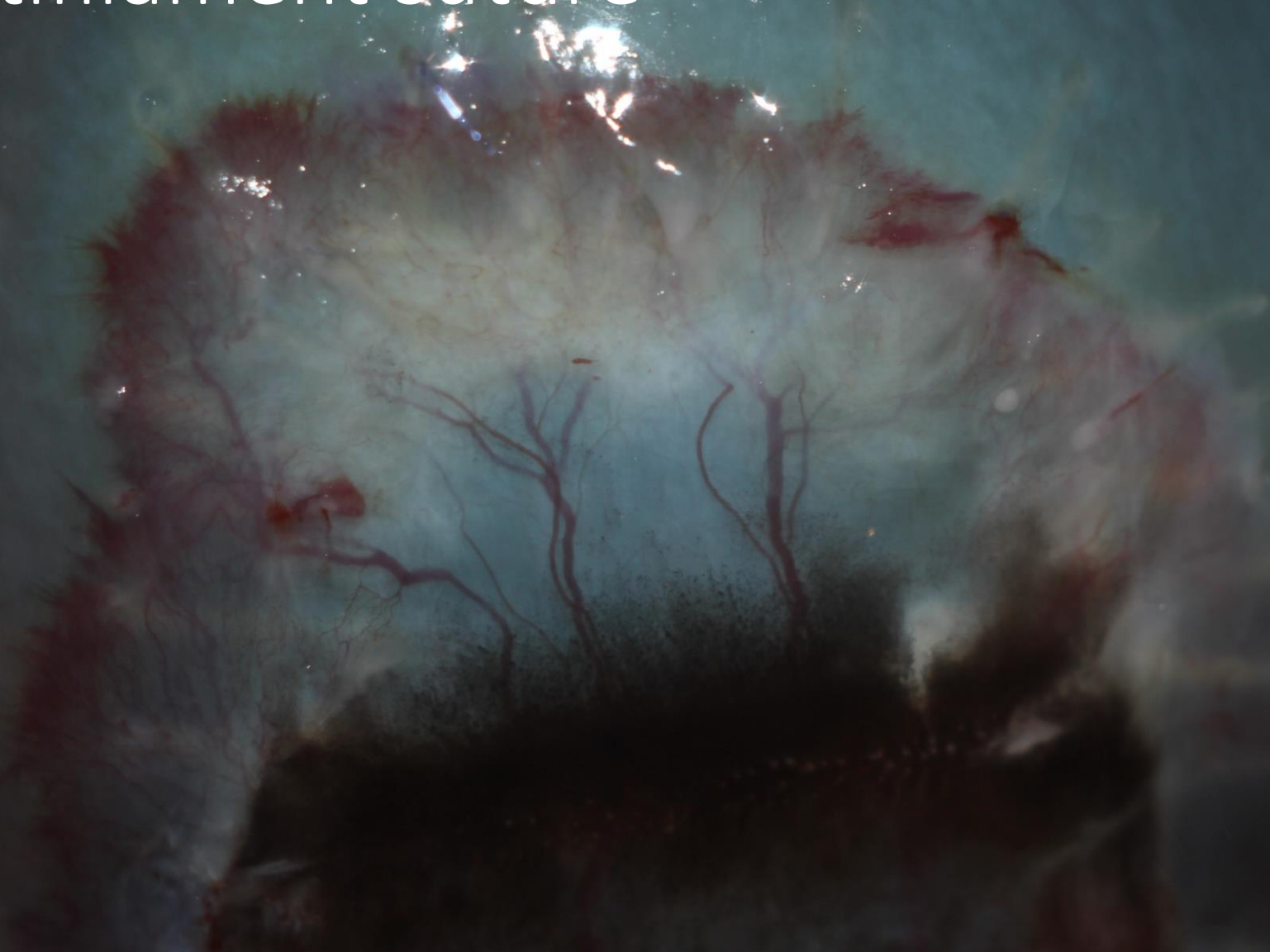
Corneal suture



- 9-0 poly glycolic acid monofilament now routinely used
- 30micron diameter (2x PMNs)
- Reduced corneal scarring
- Improved healing rates
- More complex keratoplastic procedure made possible



Corneo-conjunctival transposition: 8/0
multifilament suture






What's new in adnexal surgery?

- Tissue expanders and canthal tendon releasing techniques allow the removal and repair of larger lid lesions.
- Controversy exists in the Veterinary Ophthalmology community regarding the use of Orbital implants following enucleation. In the authors clinic combining the use of orbital implants with a modification of the trans-palpebral enucleation technique to spare the eye lashes and periocular cilia results in the post operative appearance of a closed rather than missing eye as well as improving facial sensation following removal of the globe.
- Photodynamic therapy allows a targeted chemotherapeutic option for previously untreatable ocular tumours.


Lid reconstruction in the horse: the problem



FAT GUY IN SKINNY JEANS



Lid reconstruction in the horse: the problem



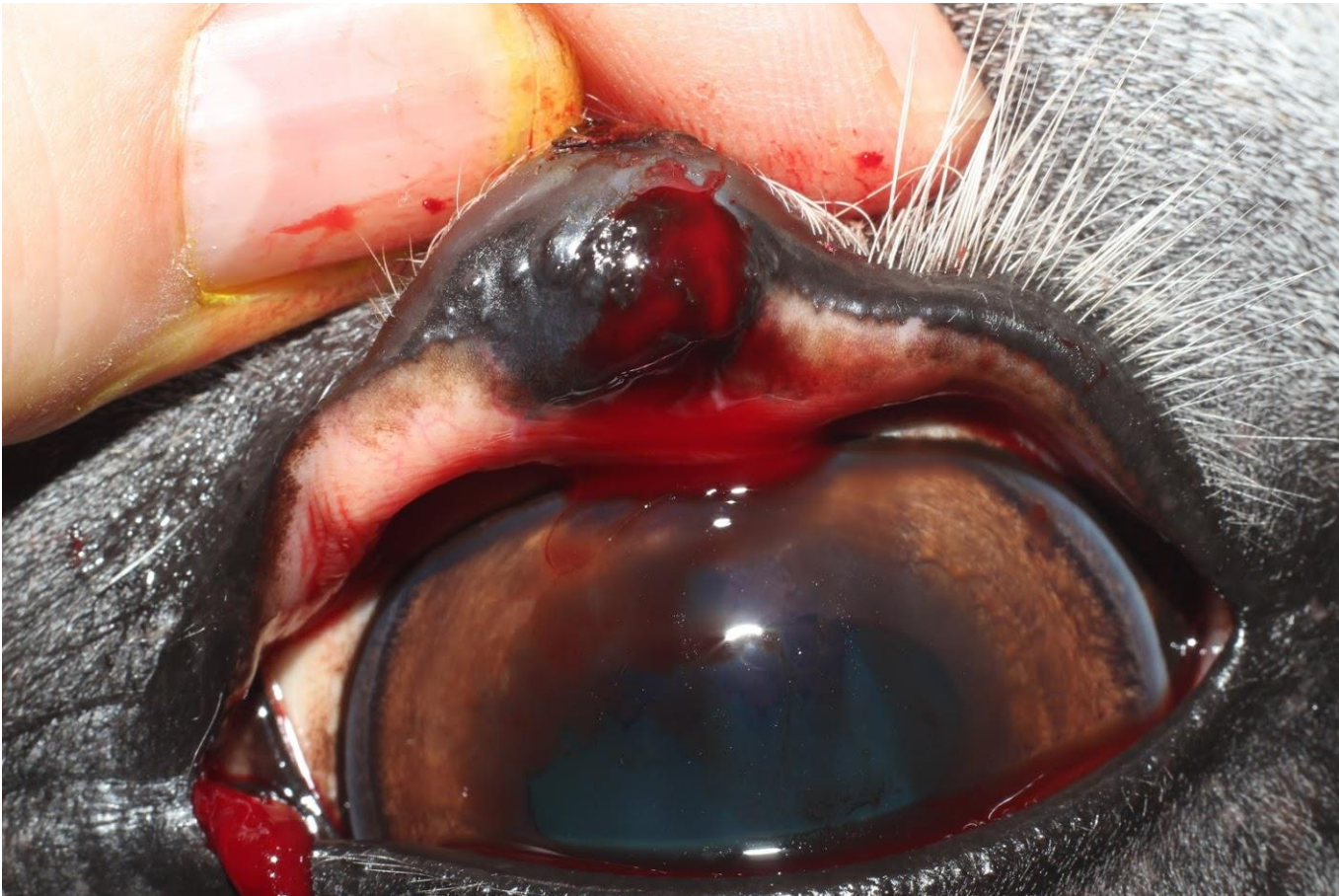FAT GUY IN SKINNY JEANS

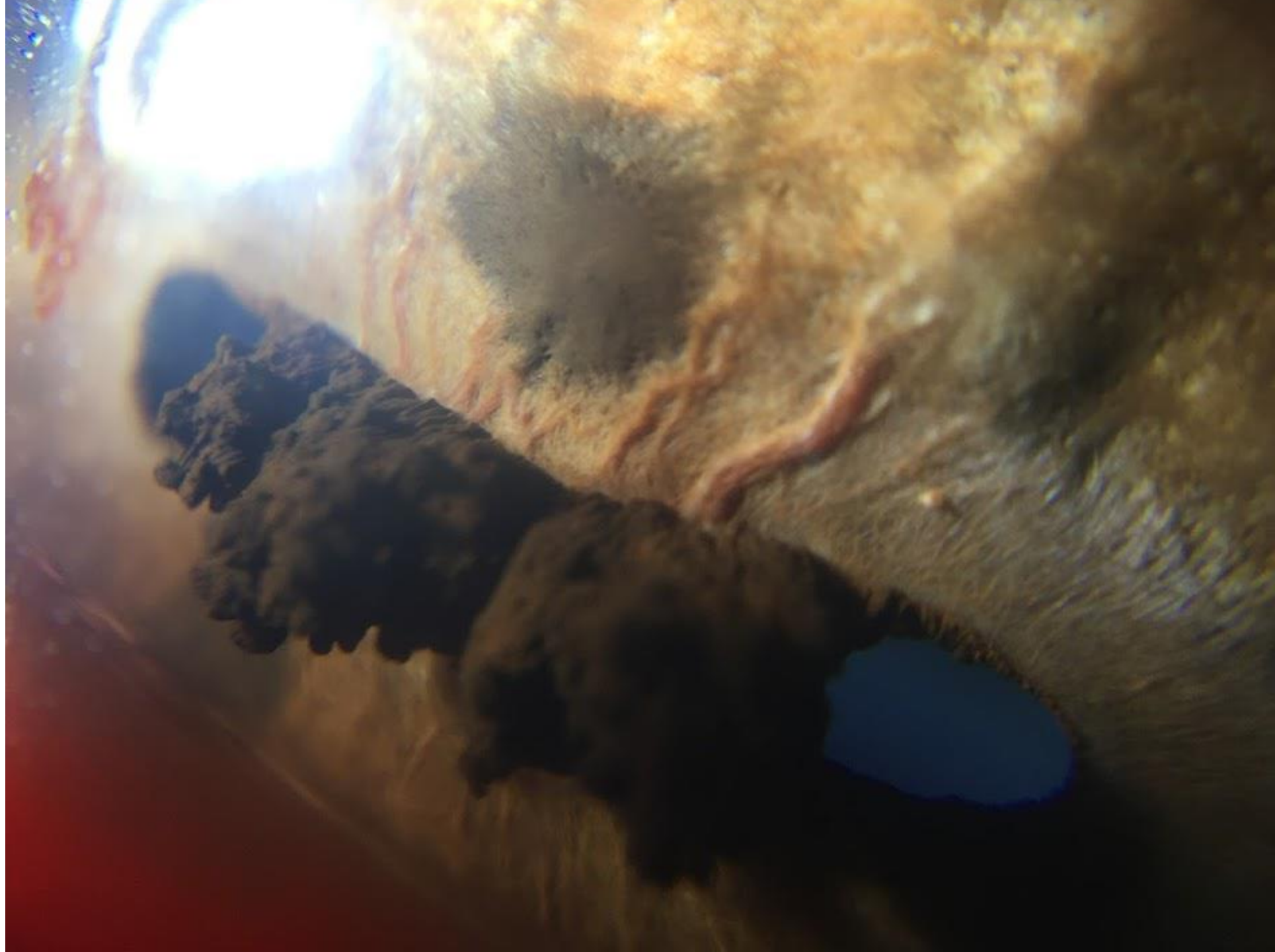

Canthal release

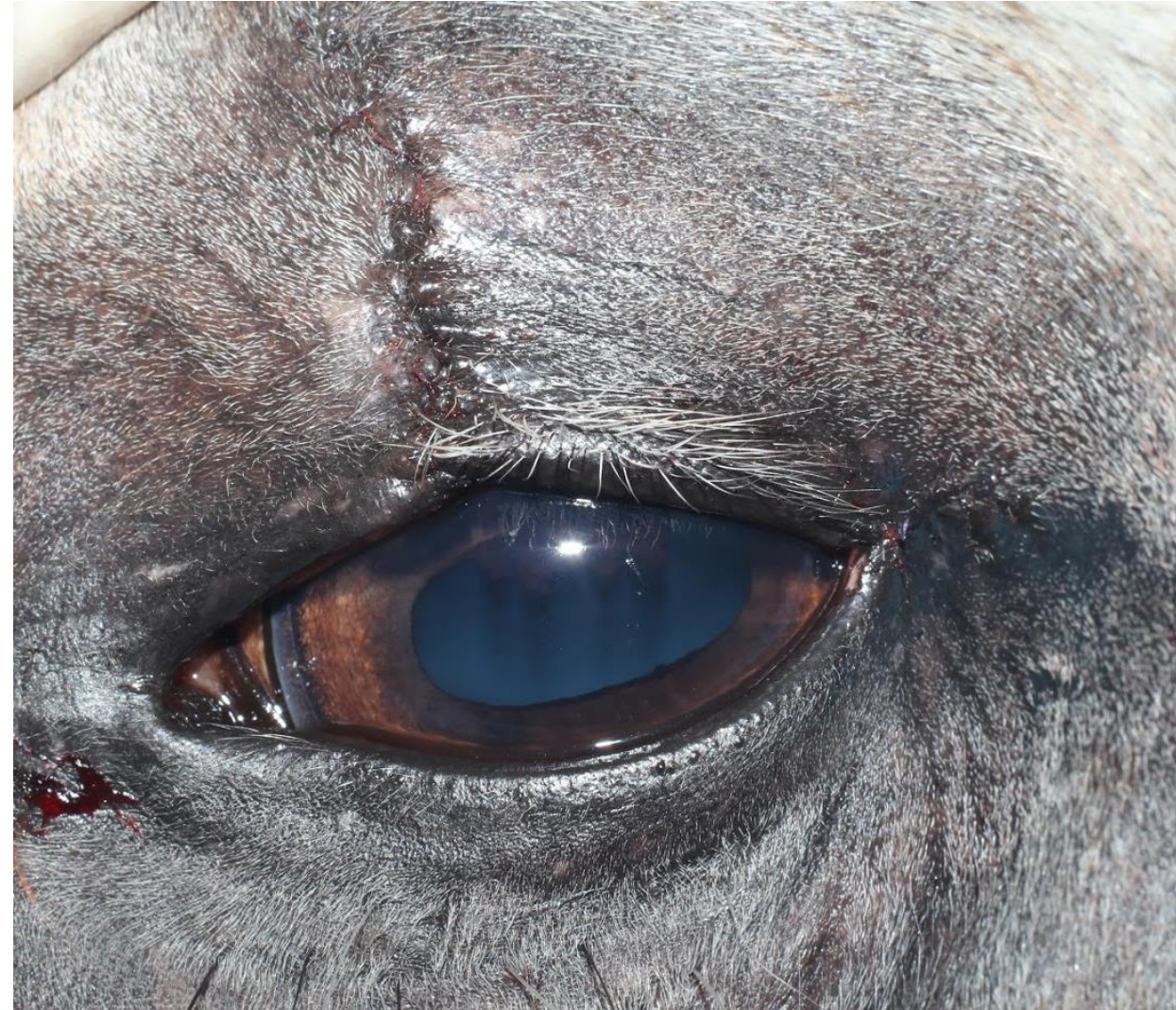
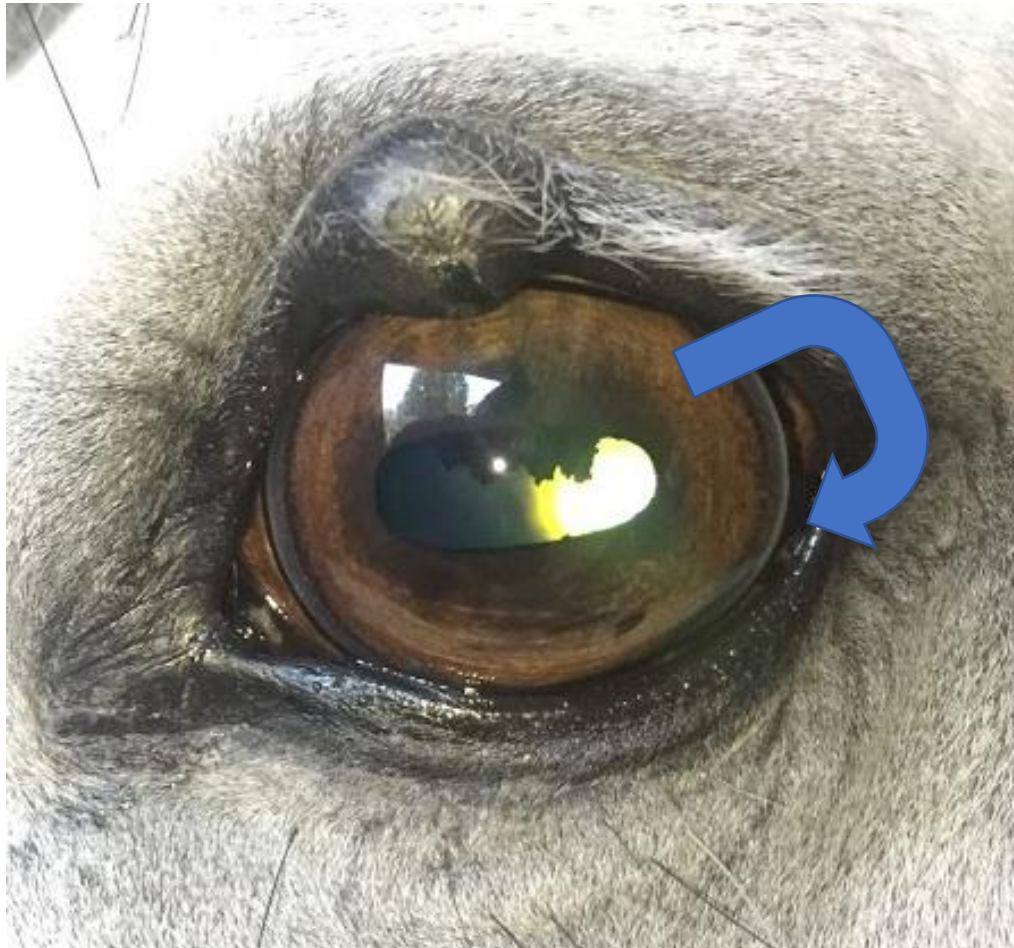
Canthal release

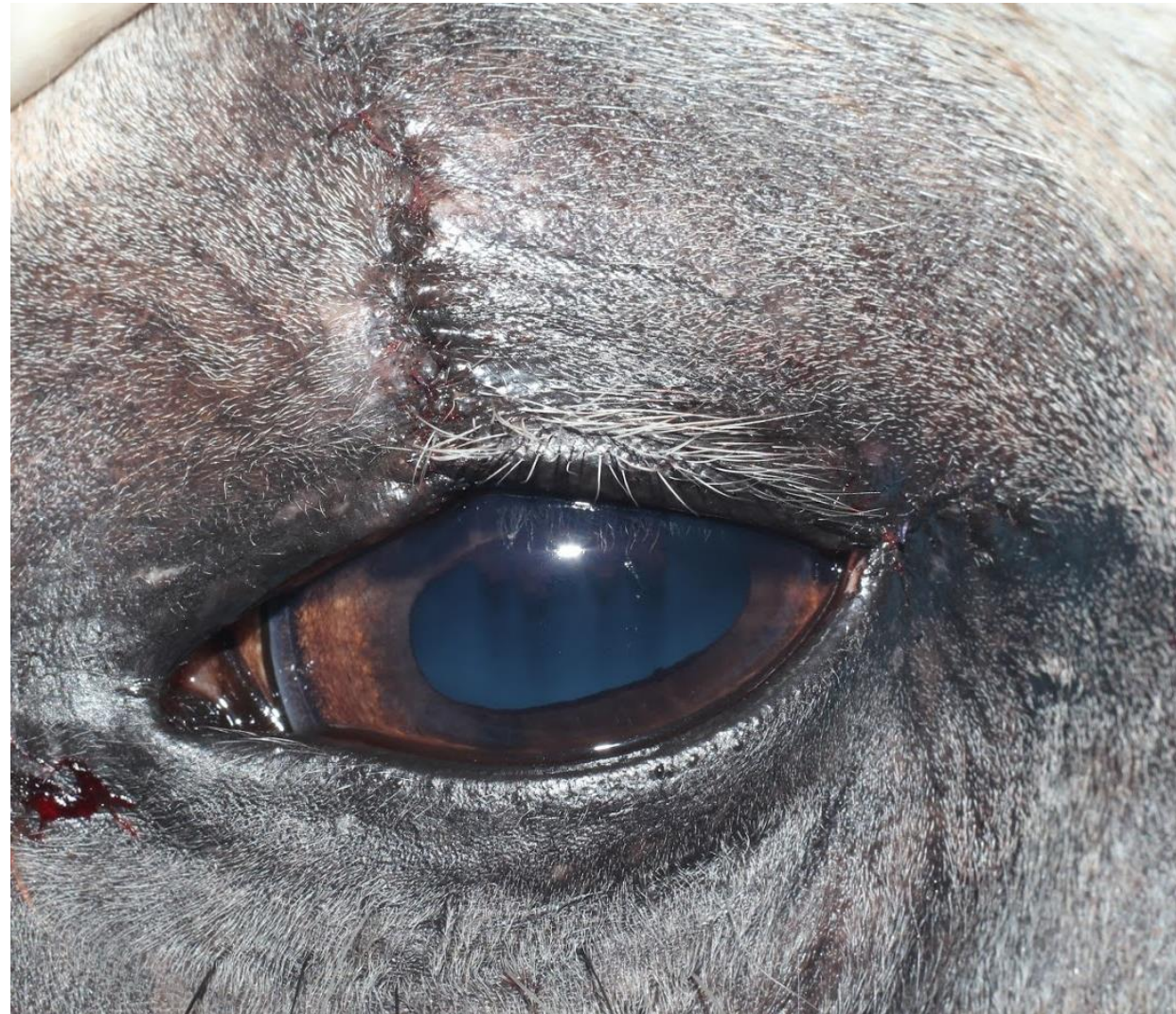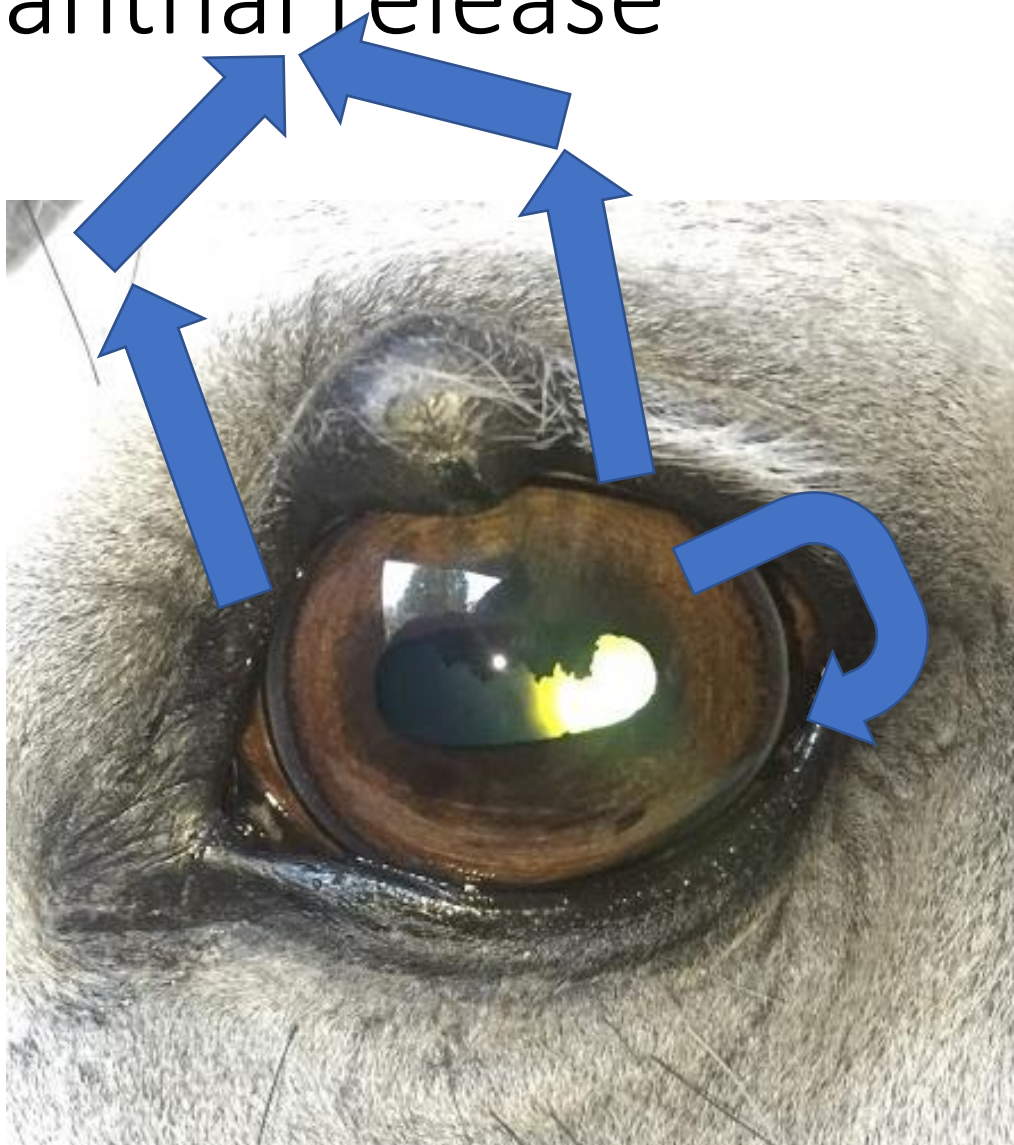



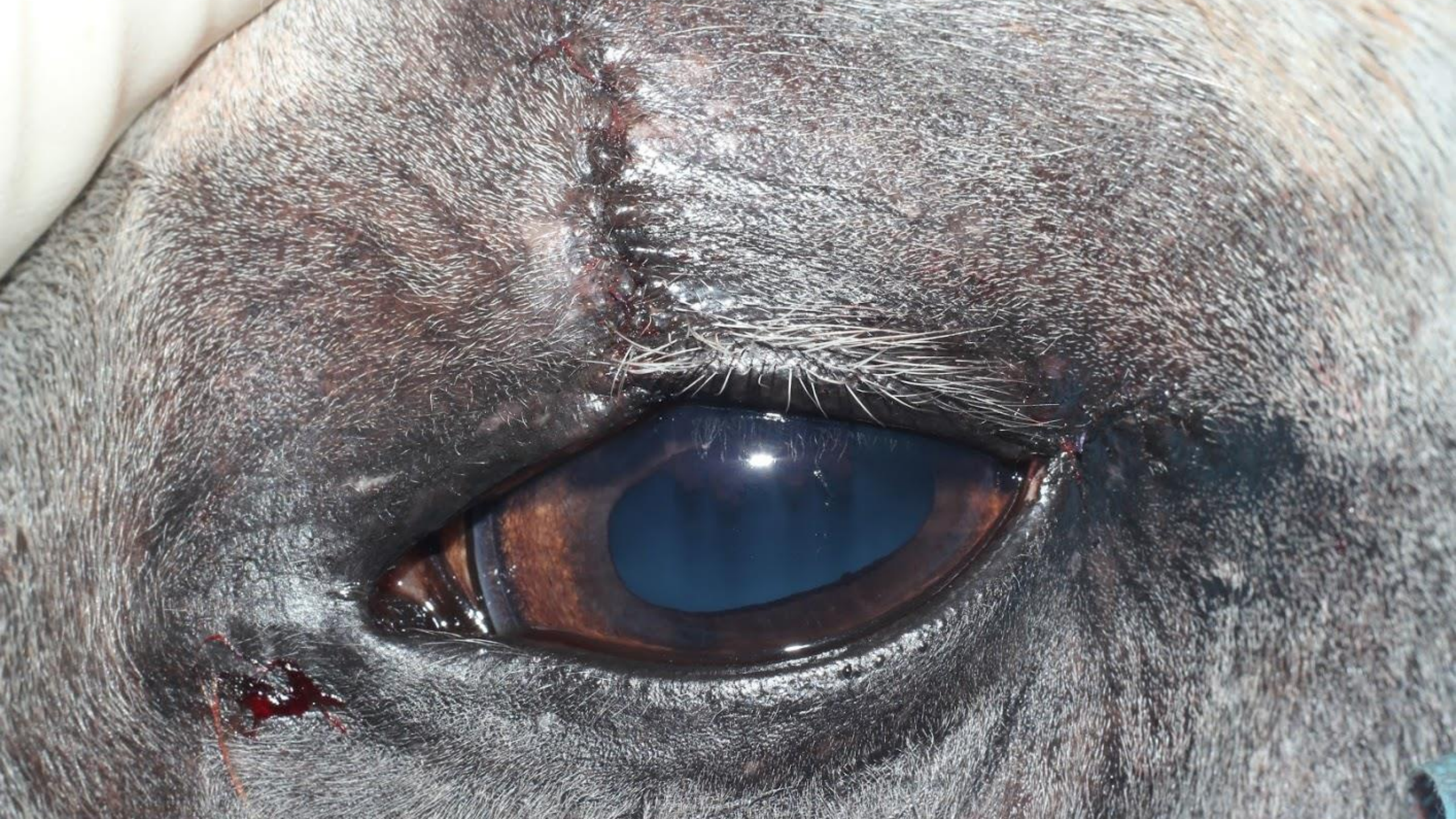
Canthal release



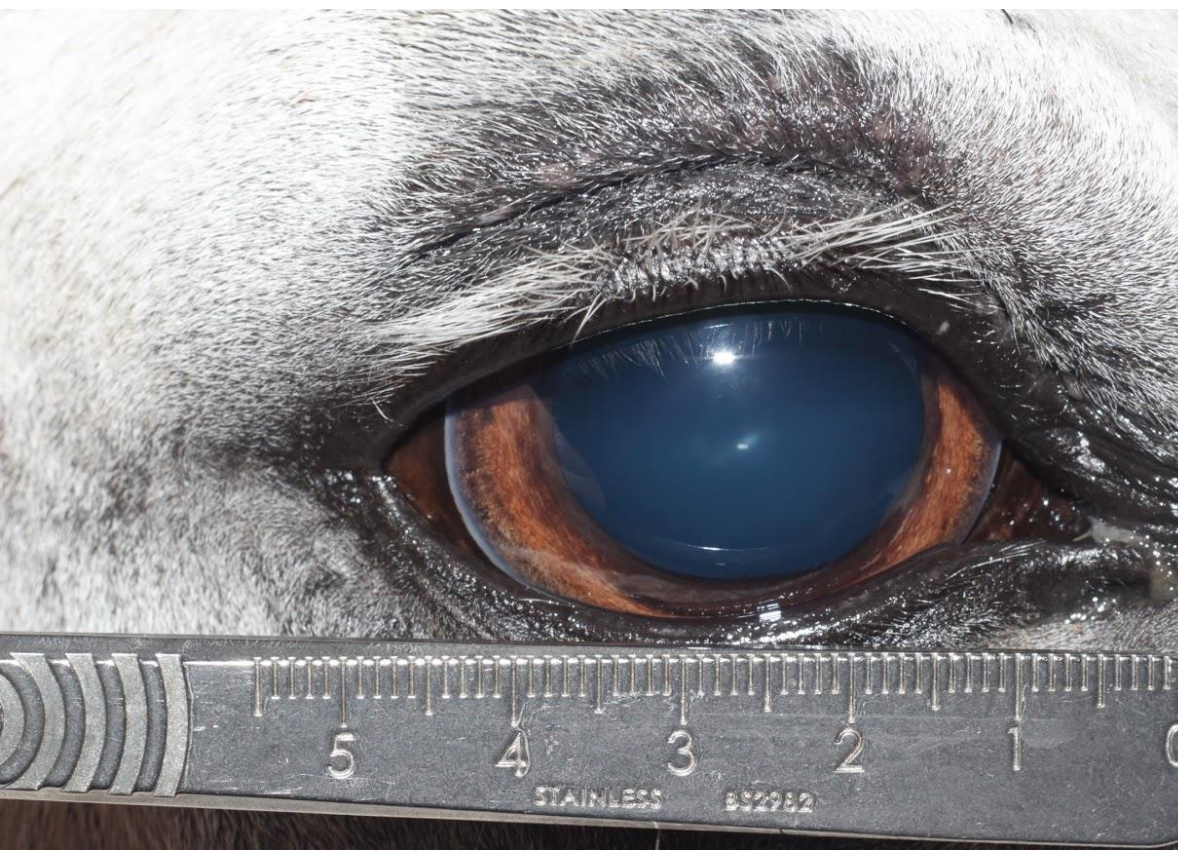
Canthal release



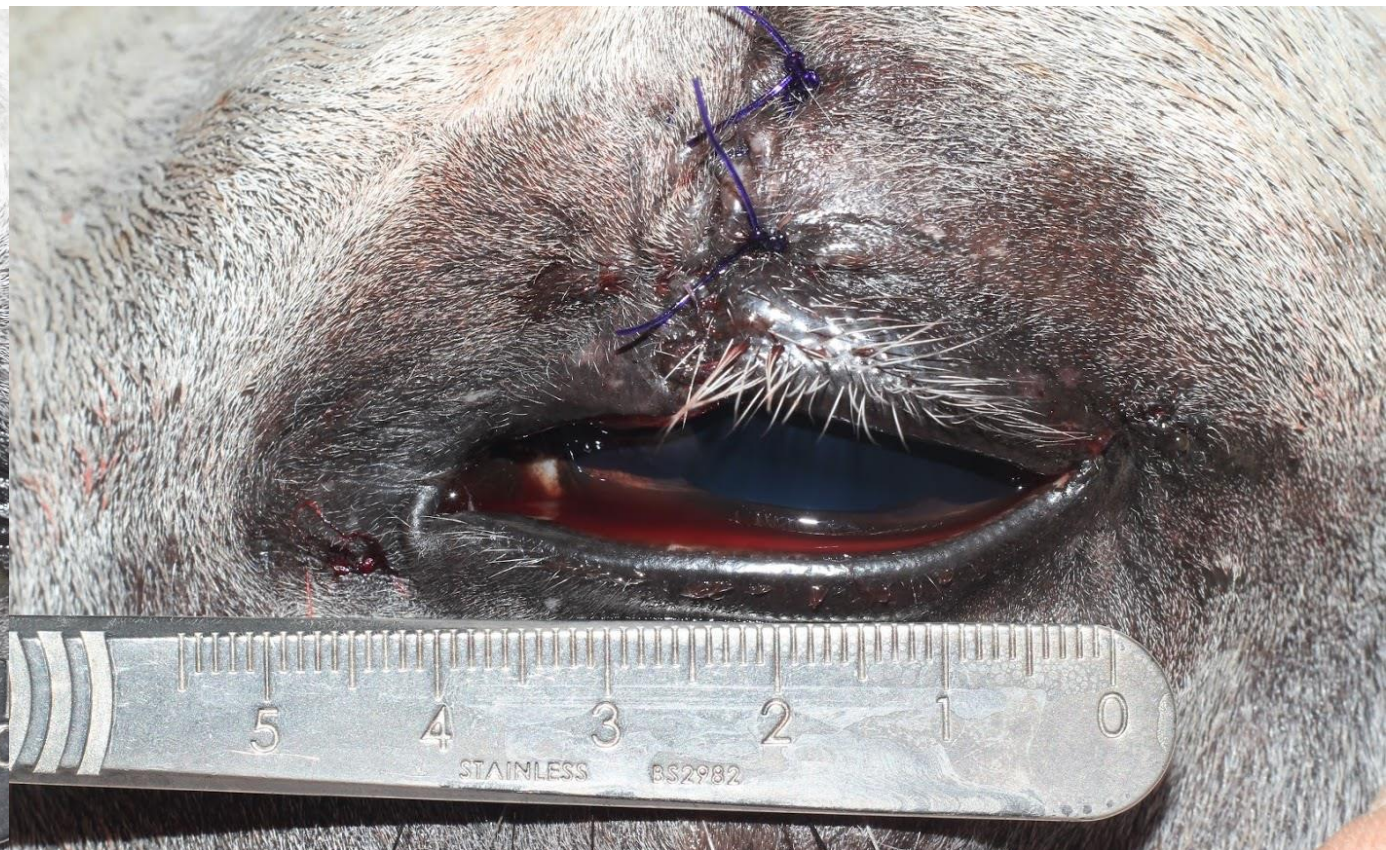

Canthal release

55mm

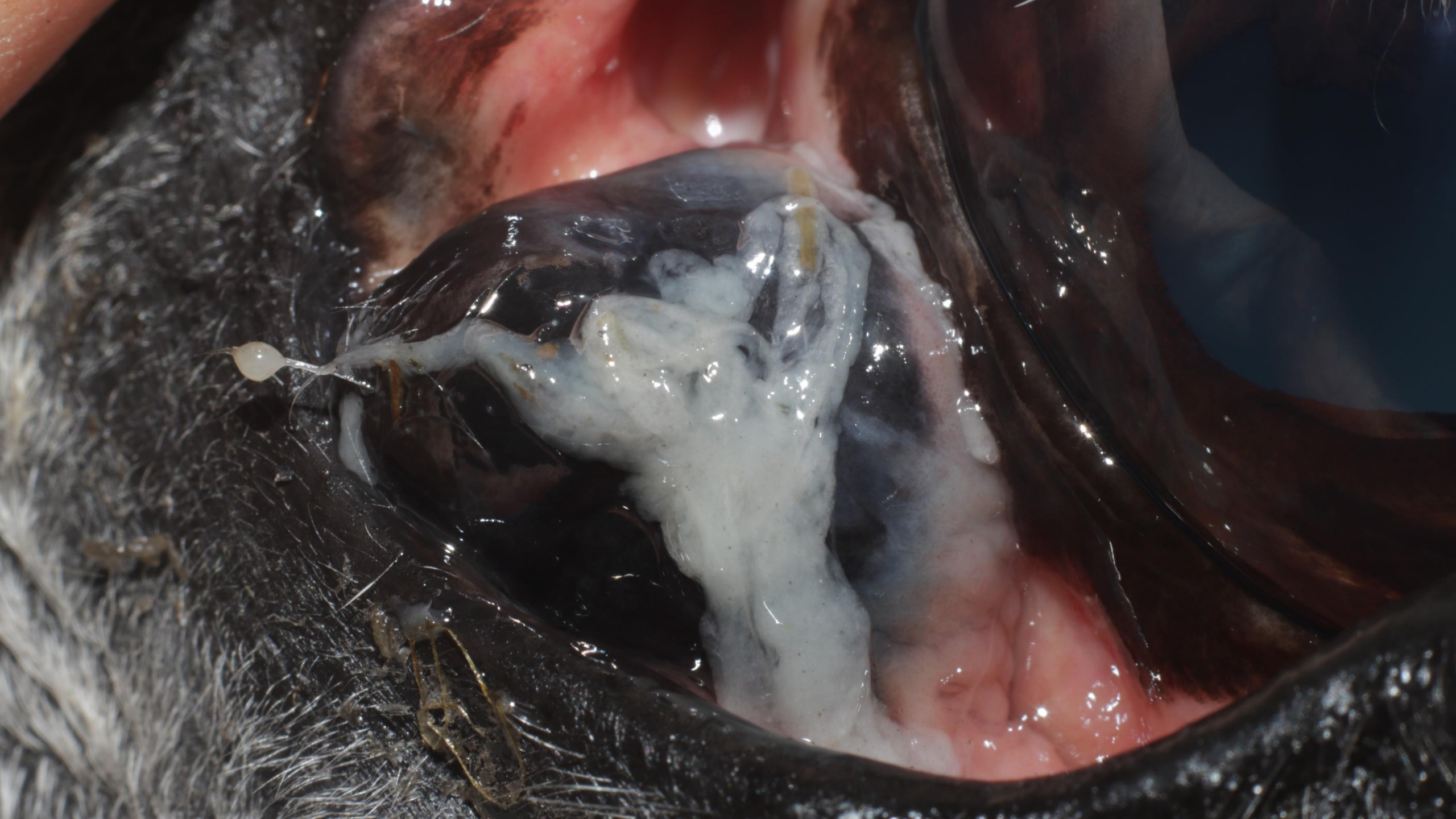

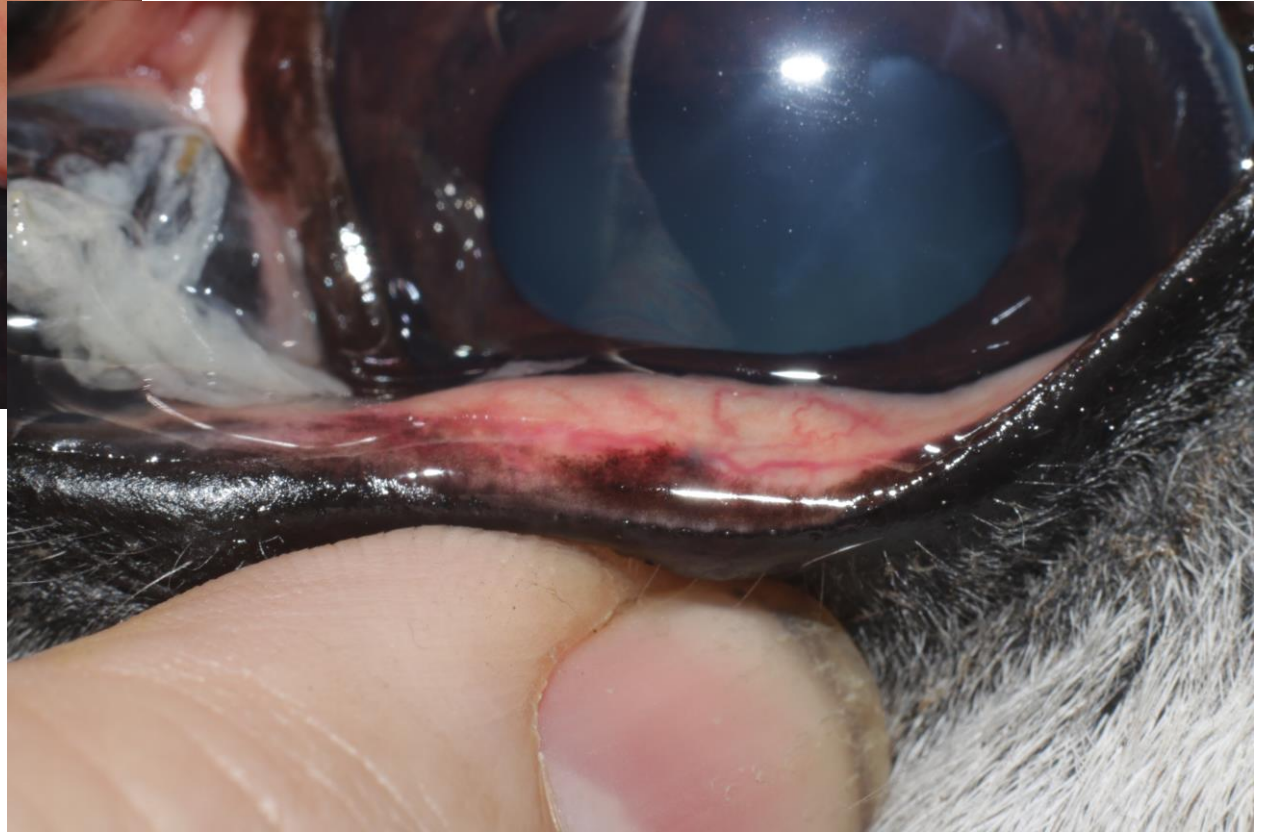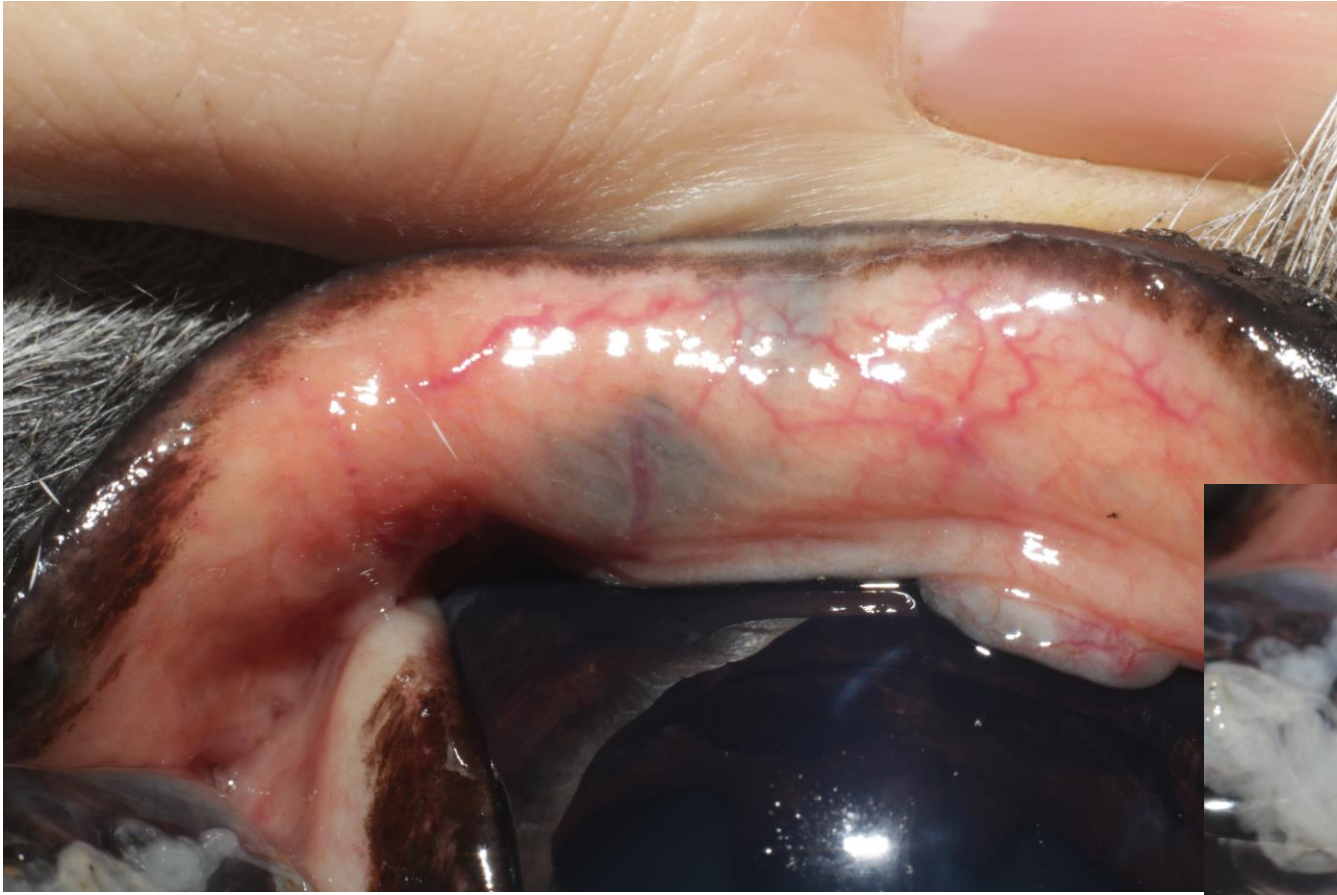35mm



Medial canthal
release

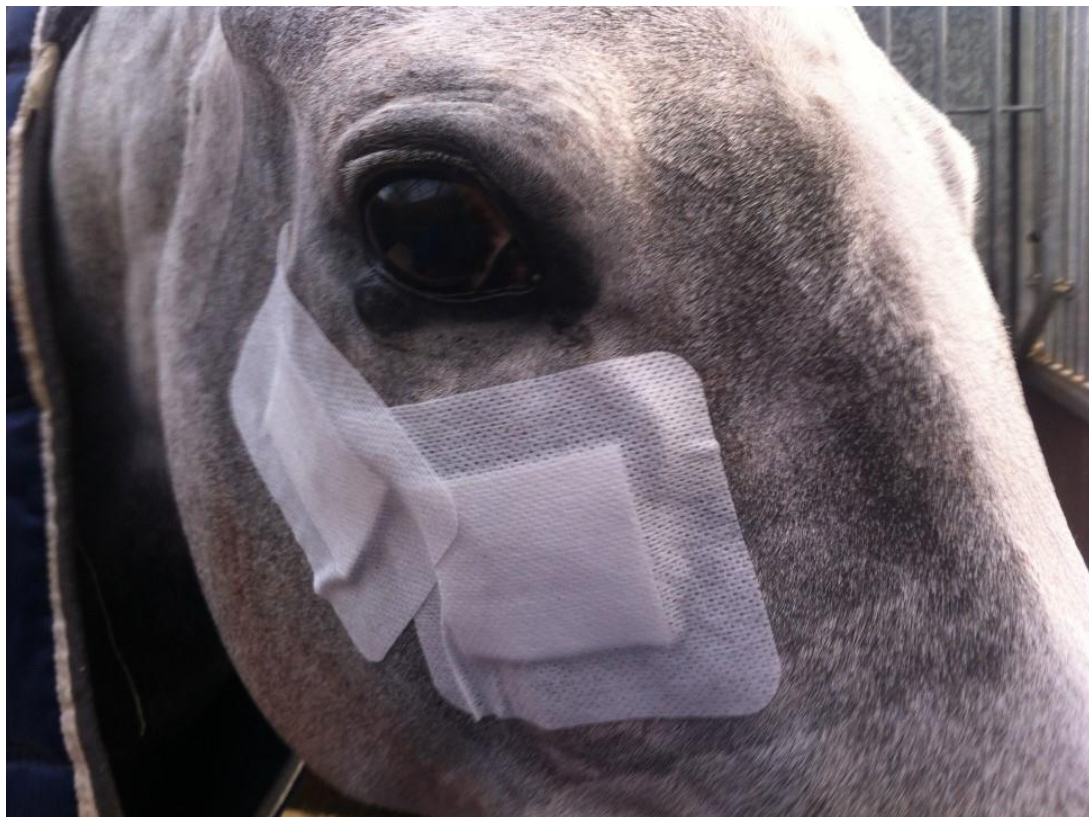





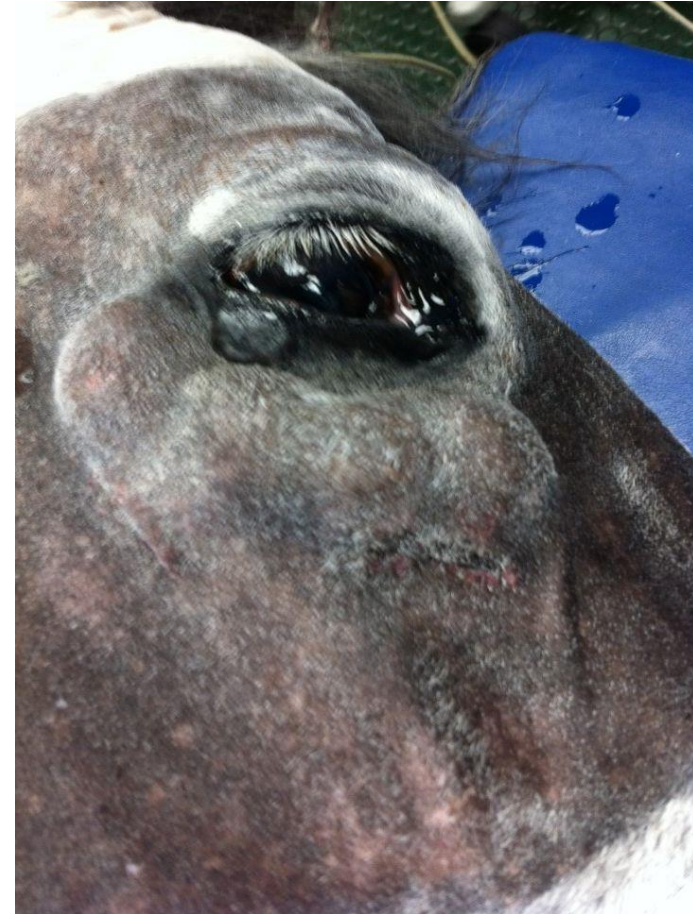

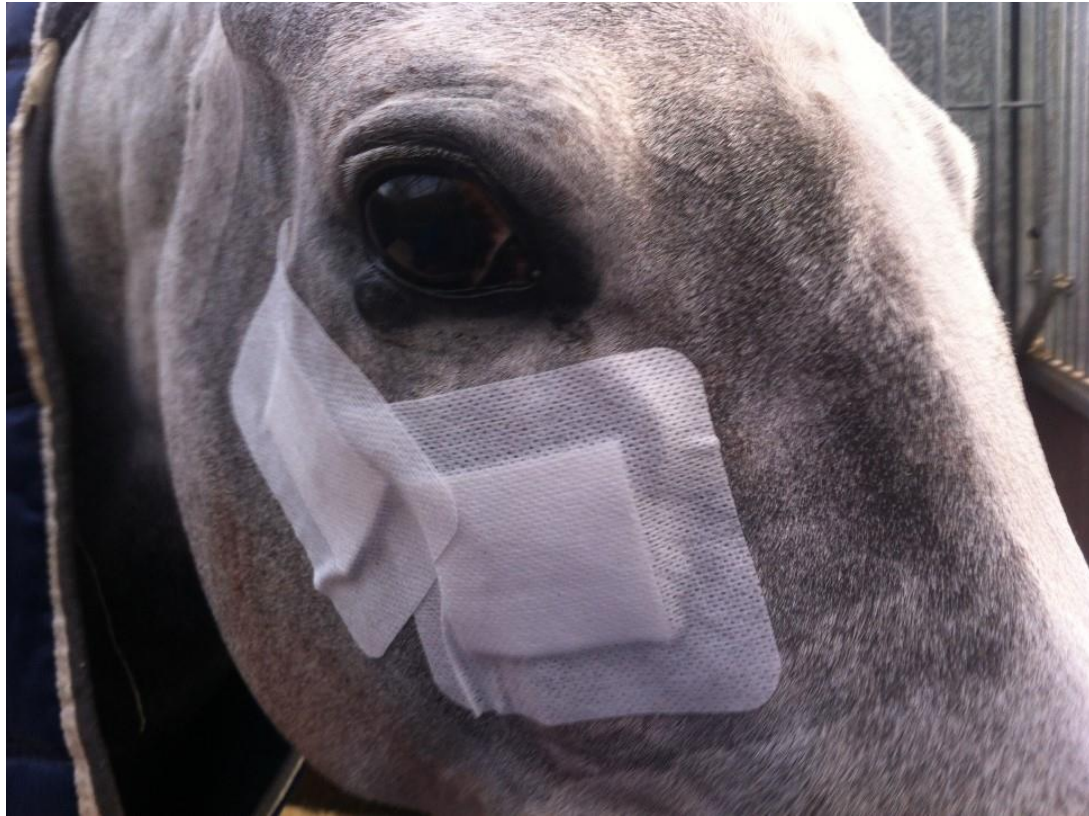
Tissue expanders (Expaniderm©)

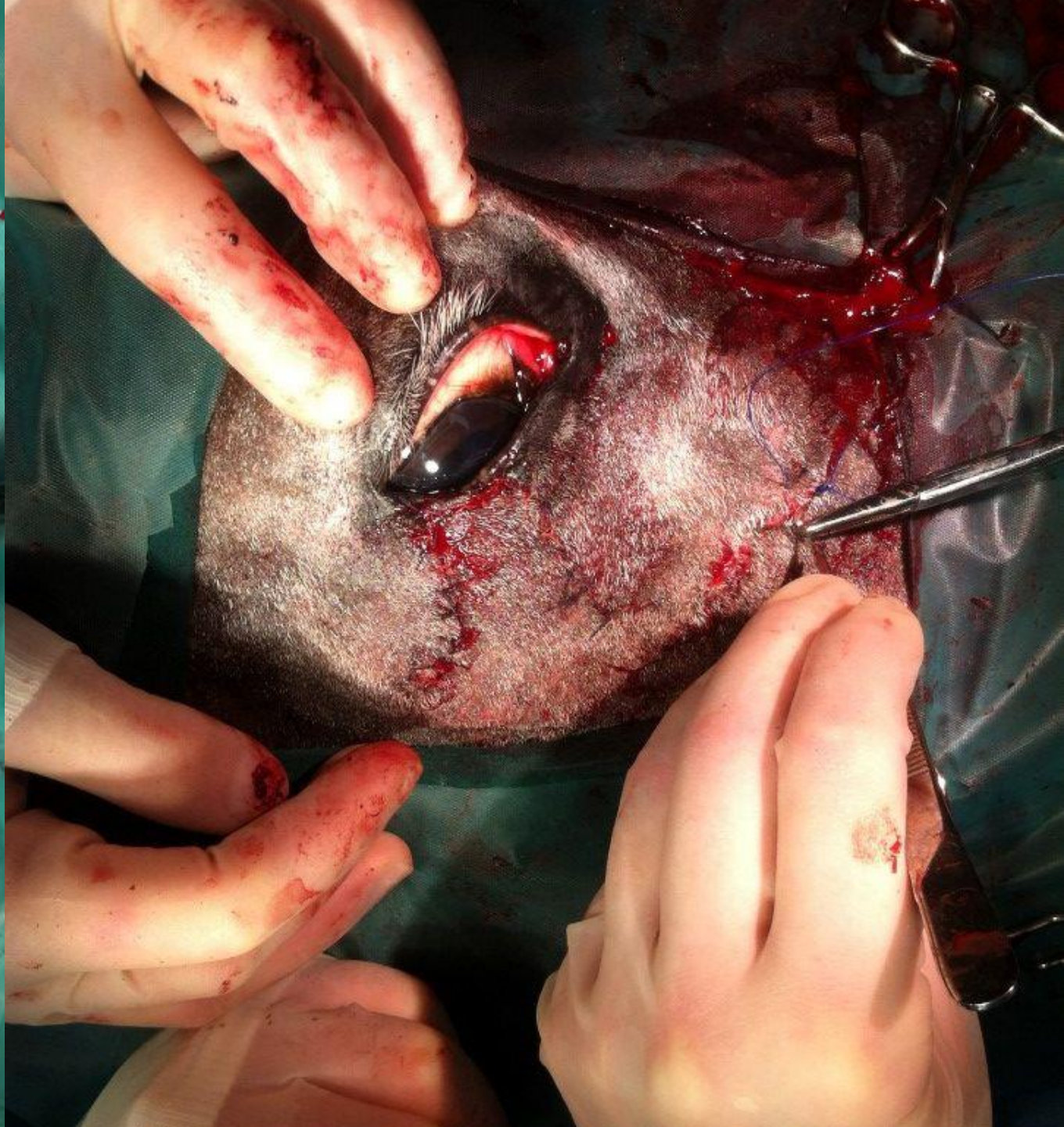
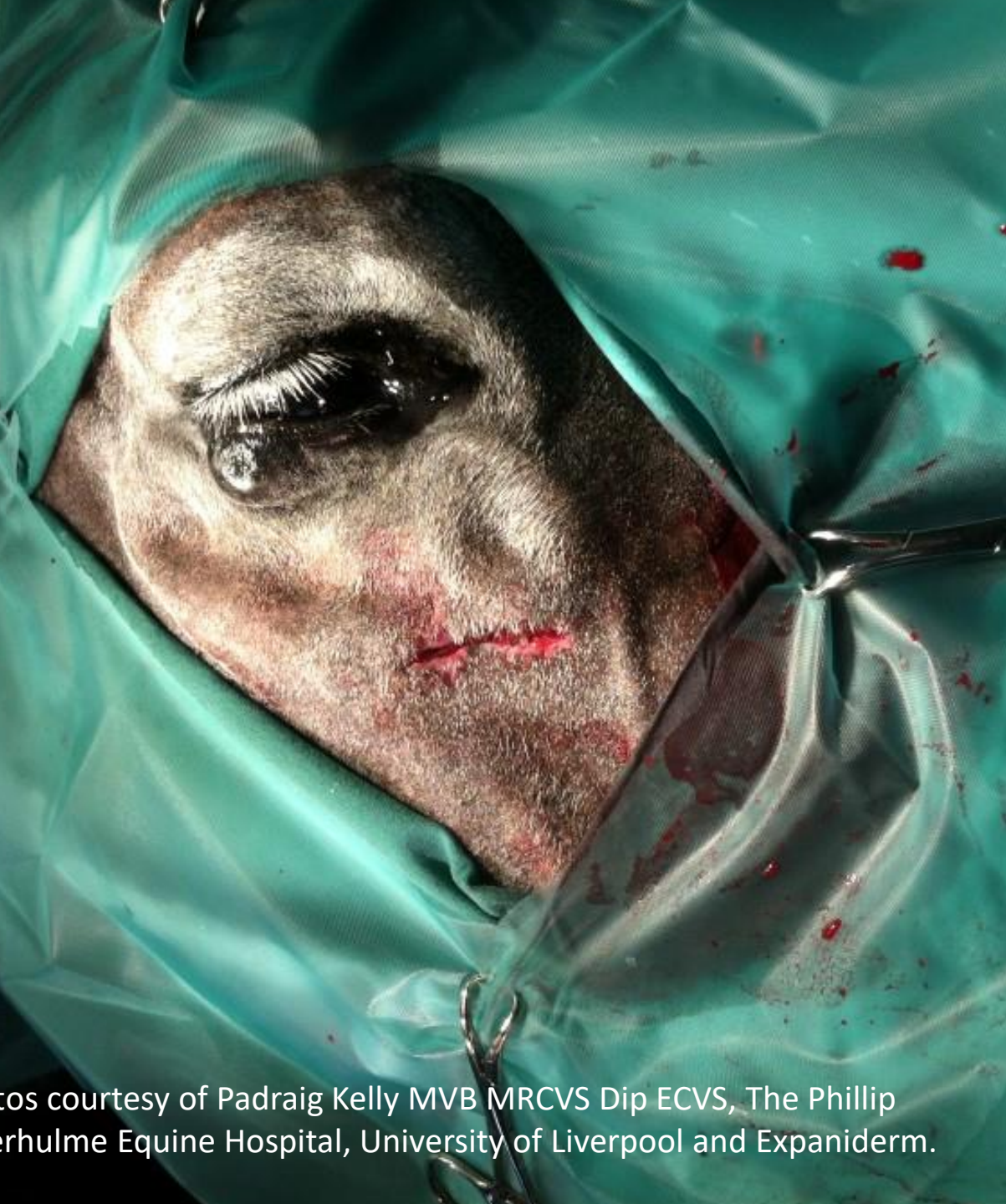
Photos courtesy of Padraig Kelly MVB MRCVS Dip ECVS, The Phillip Leverhulme Equine Hospital, University of Liverpool and Expaniderm.

Tissue expanders



Photos courtesy of Padraig Kelly MVB MRCVS Dip ECVS, The Phillip Leverhulme Equine Hospital, University of Liverpool and Expaniderm.



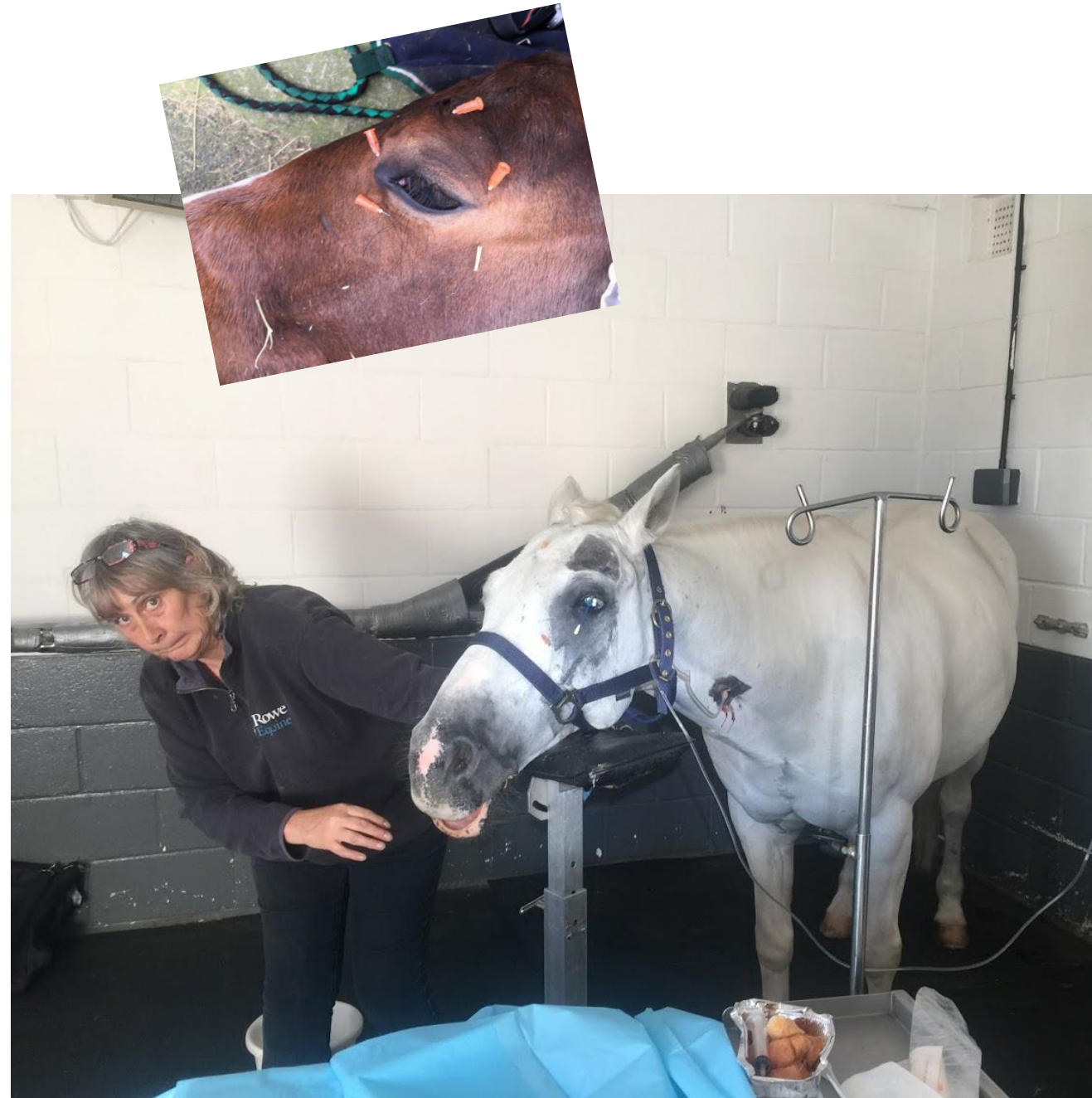os courtesy of Padraig Kelly MVB MRCVS Dip ECVS, The Phillip
erhulme Equine Hospital, University of Liverpool and Expaniderm.

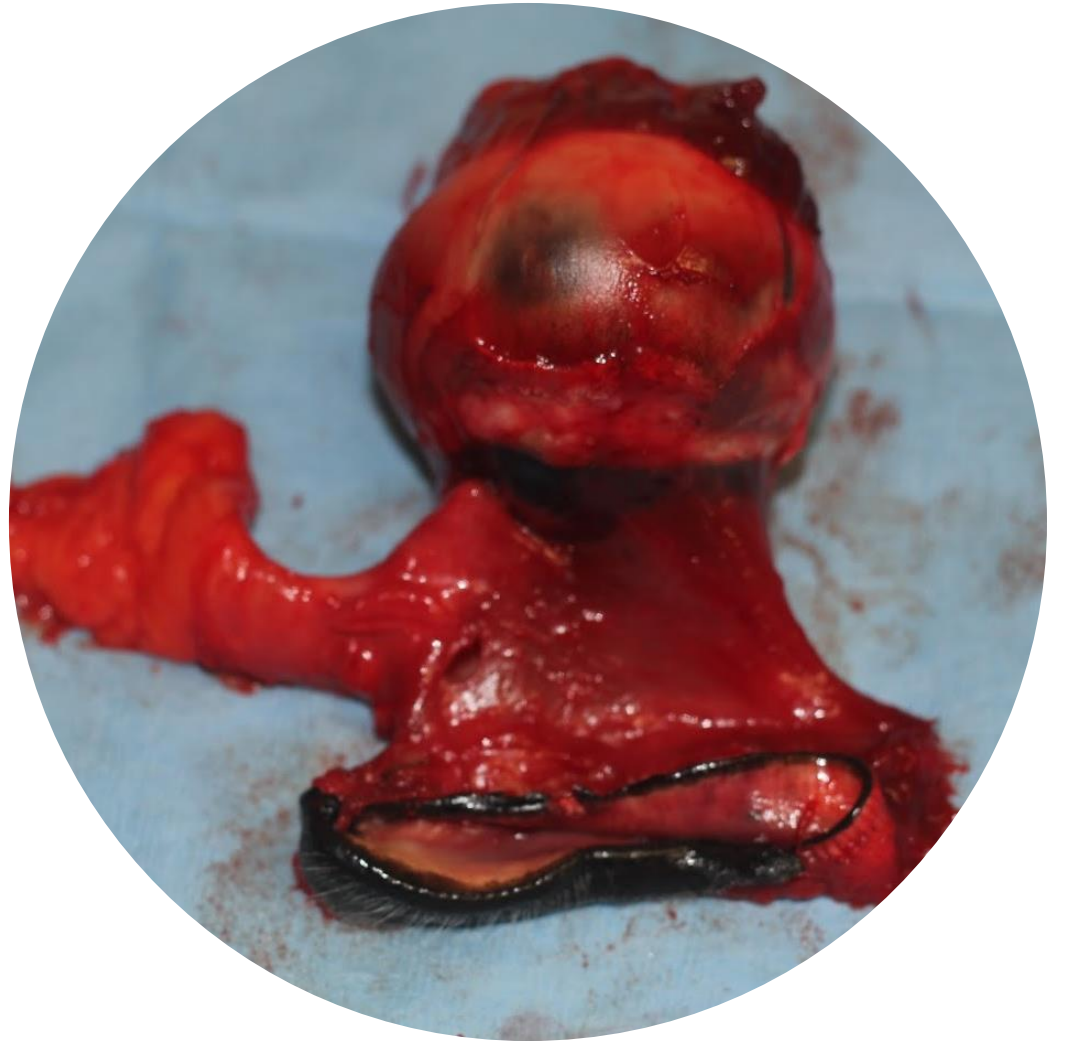
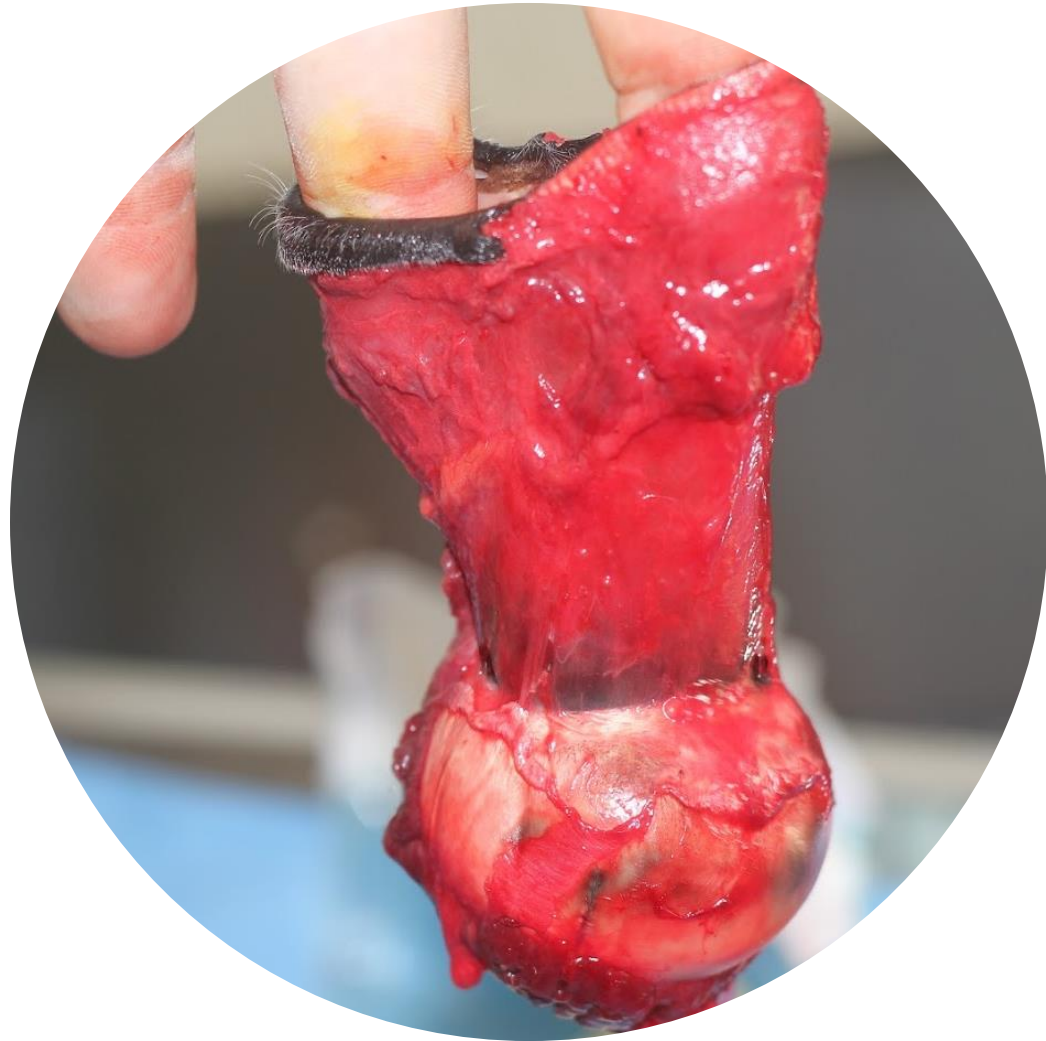A close-up photograph of a white horse's head in a stable. A person wearing a white lab coat and a dark blue sleeve is performing a procedure on the horse's eye. The horse is wearing a black halter. The background is a white brick wall. A semi-transparent white circle is overlaid on the left side of the image, containing the text 'Enucleation in the standing horse' and a horizontal line.

Enucleation in the
standing horse

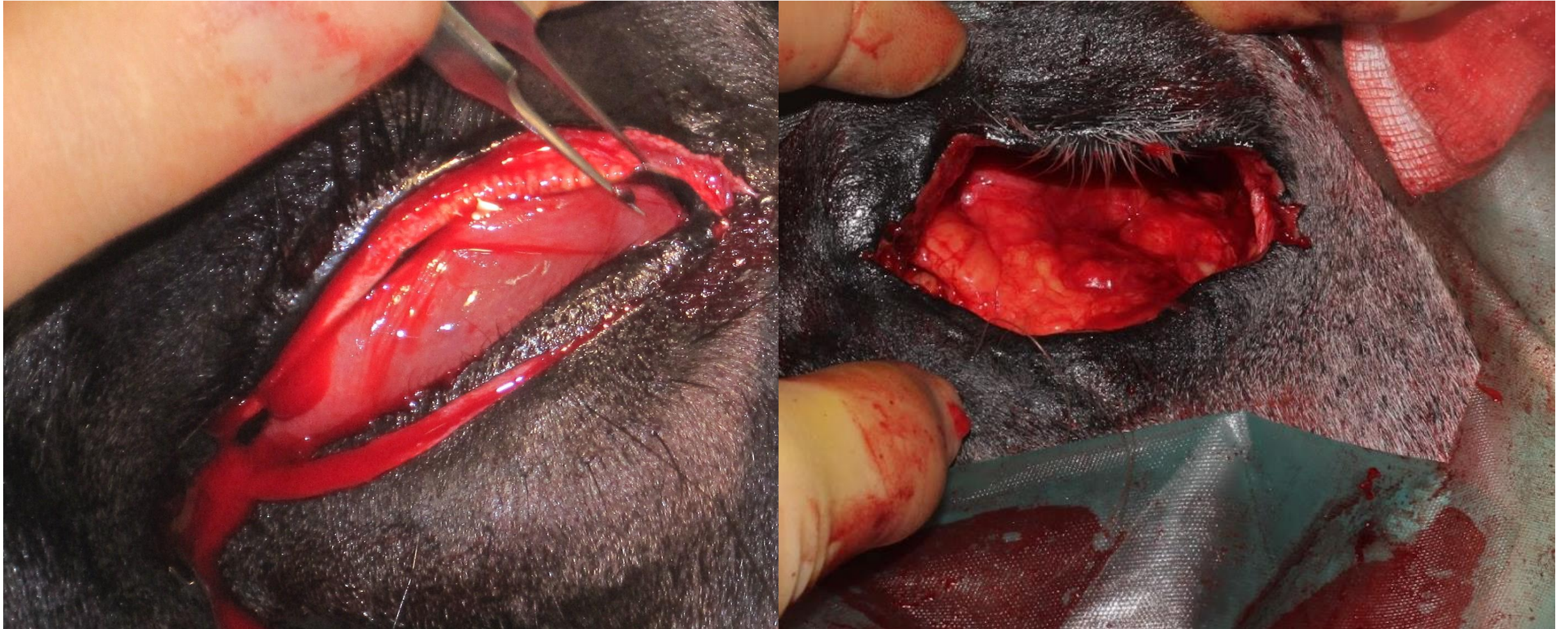
Standing enucleation

- Know your blocks:
 - Diamond block
 - Retrobulbar block
 - Lid infiltration
- Rely on blocks and good help rather than depth of sedation
- Remove as little tissue as possible
- Never leave conjunctiva
- Consider catheterisation even if you're a speedy surgeon

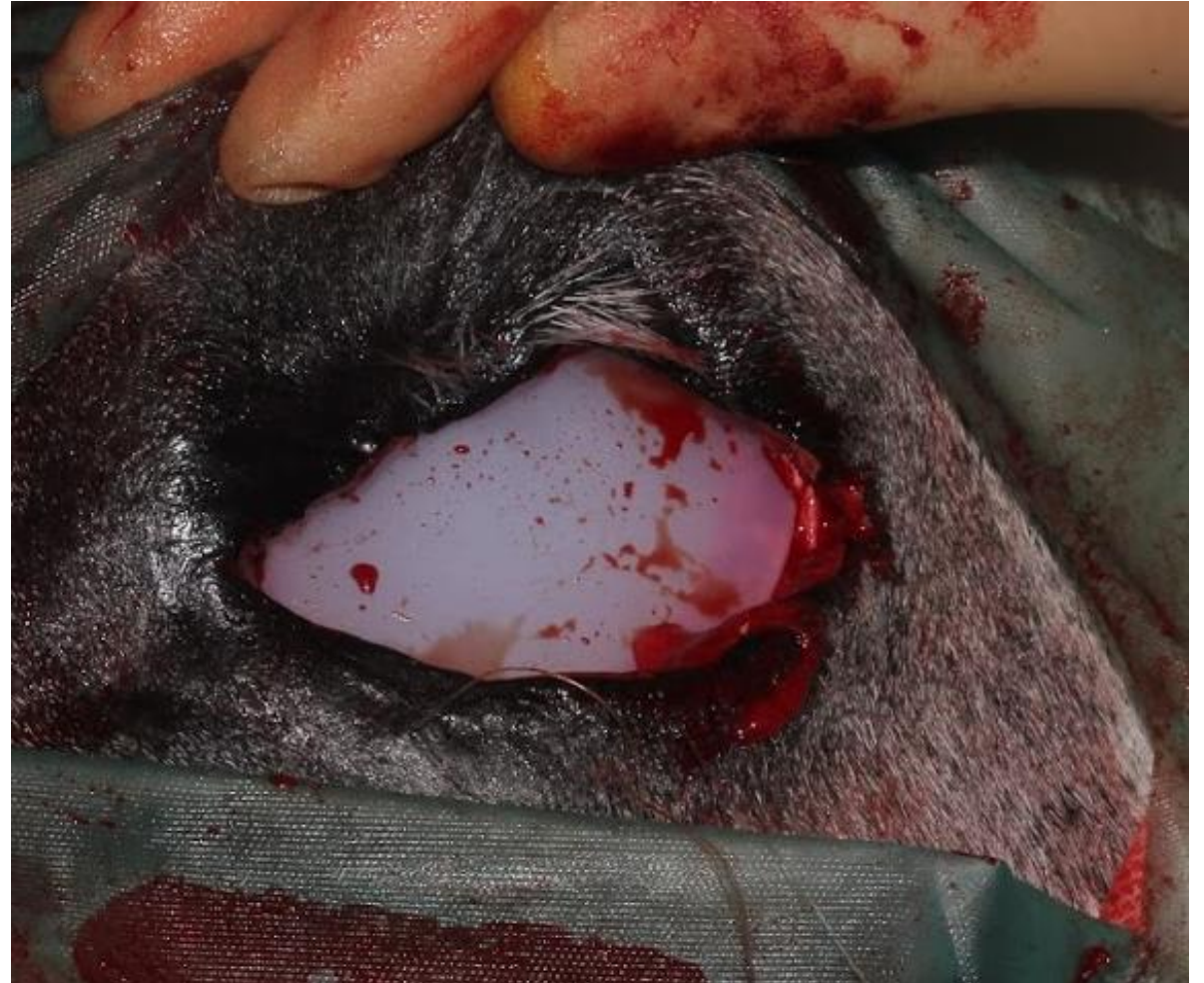
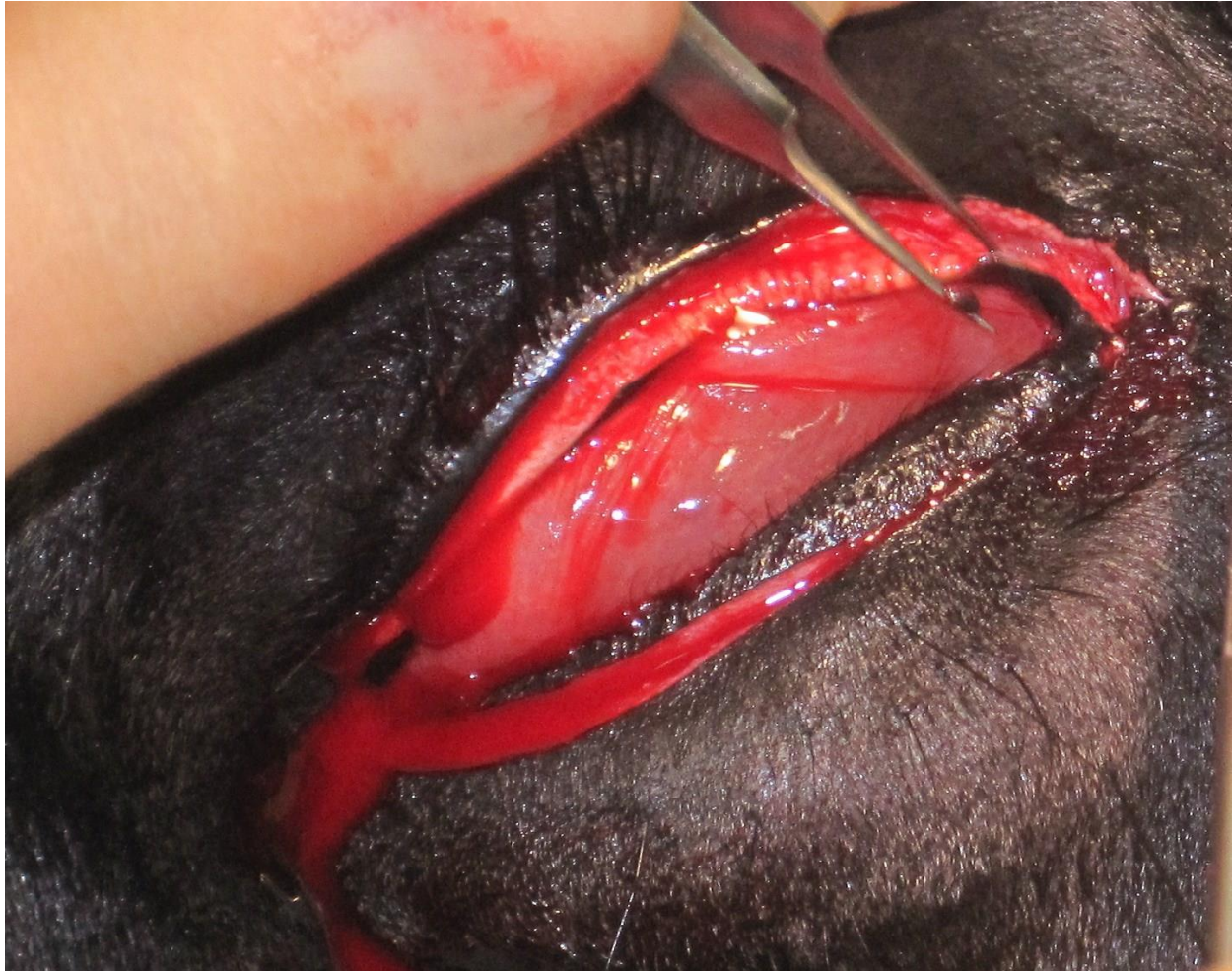


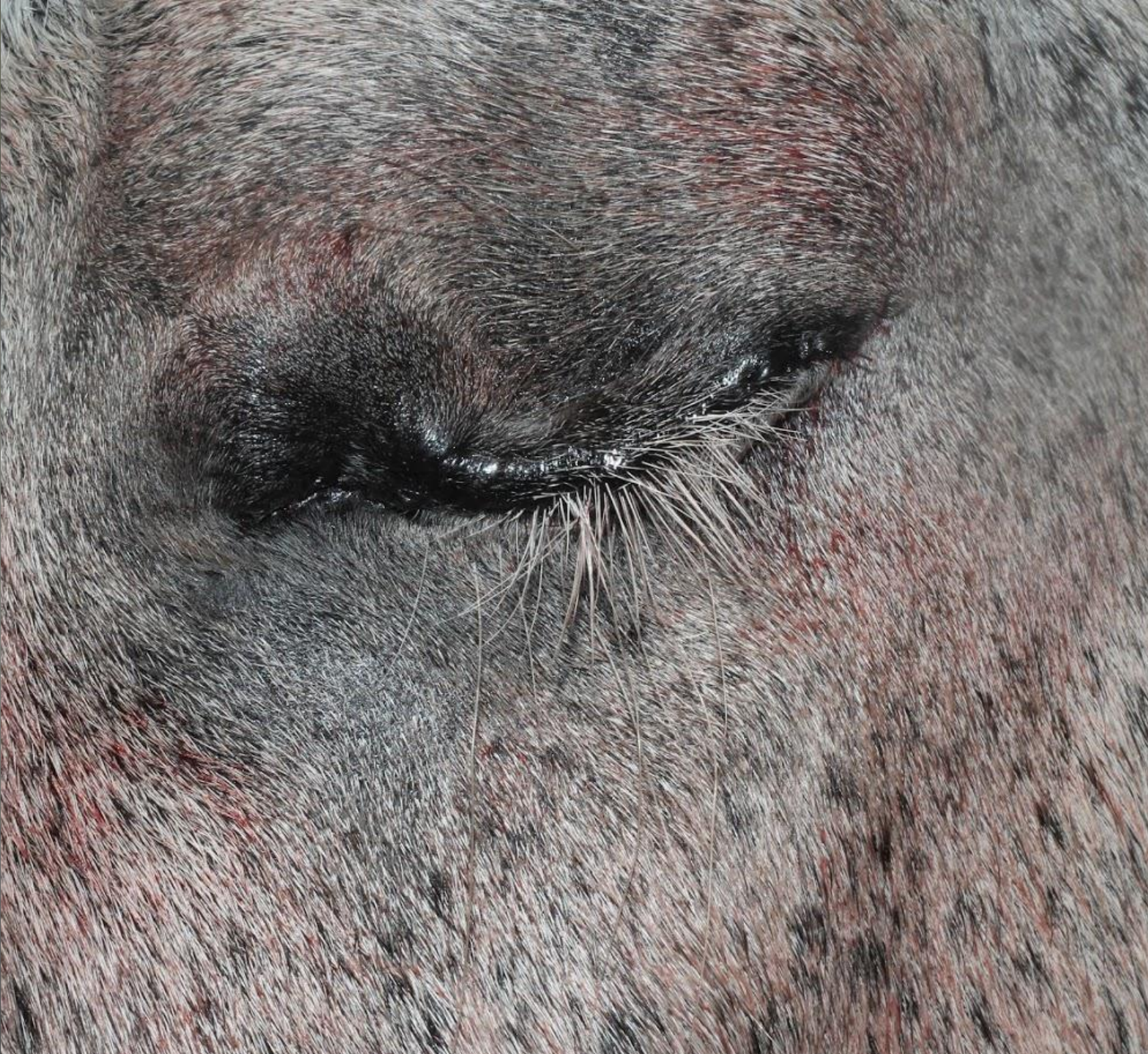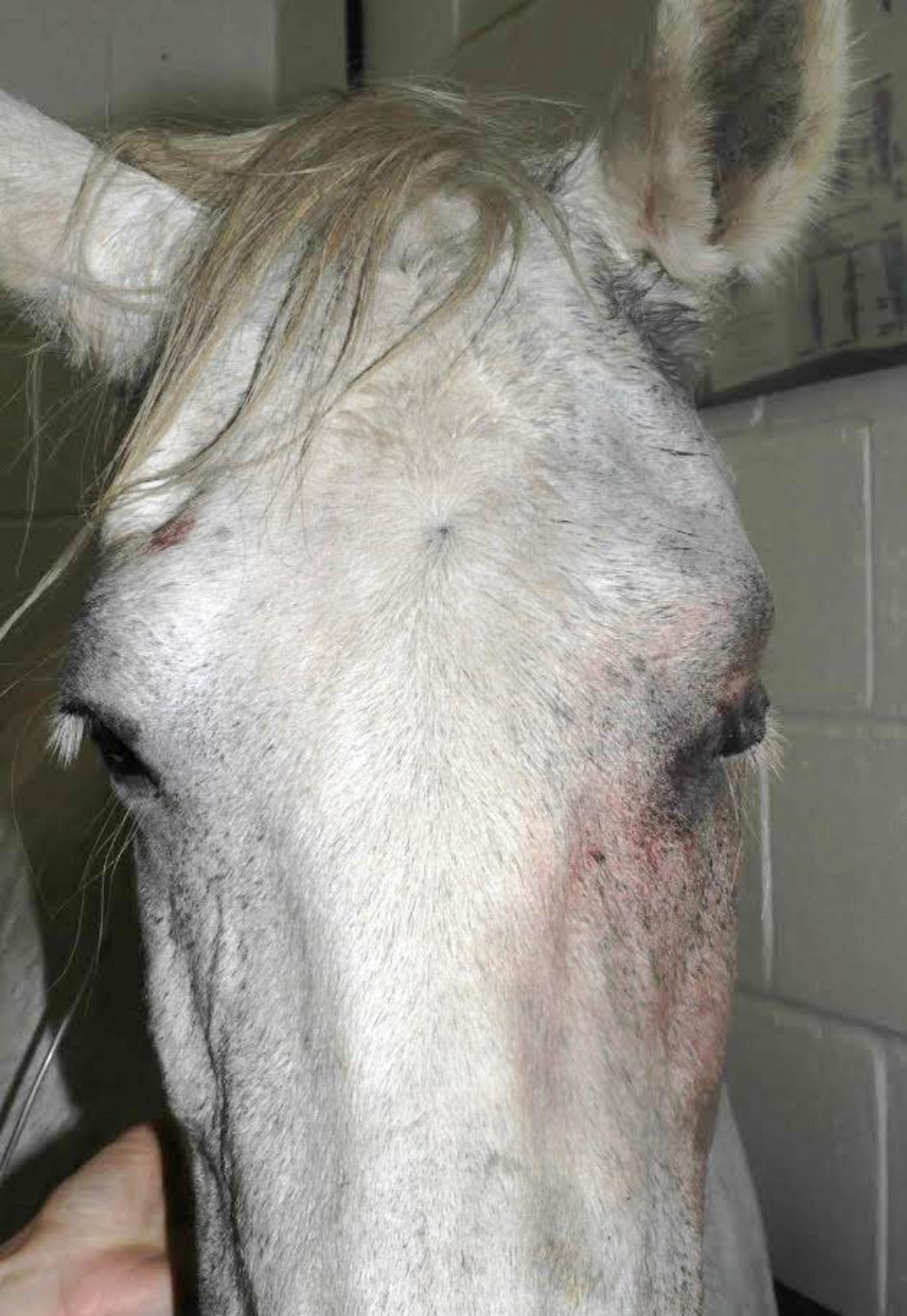Standing enucleation: modified trans-palpebral lid split technique



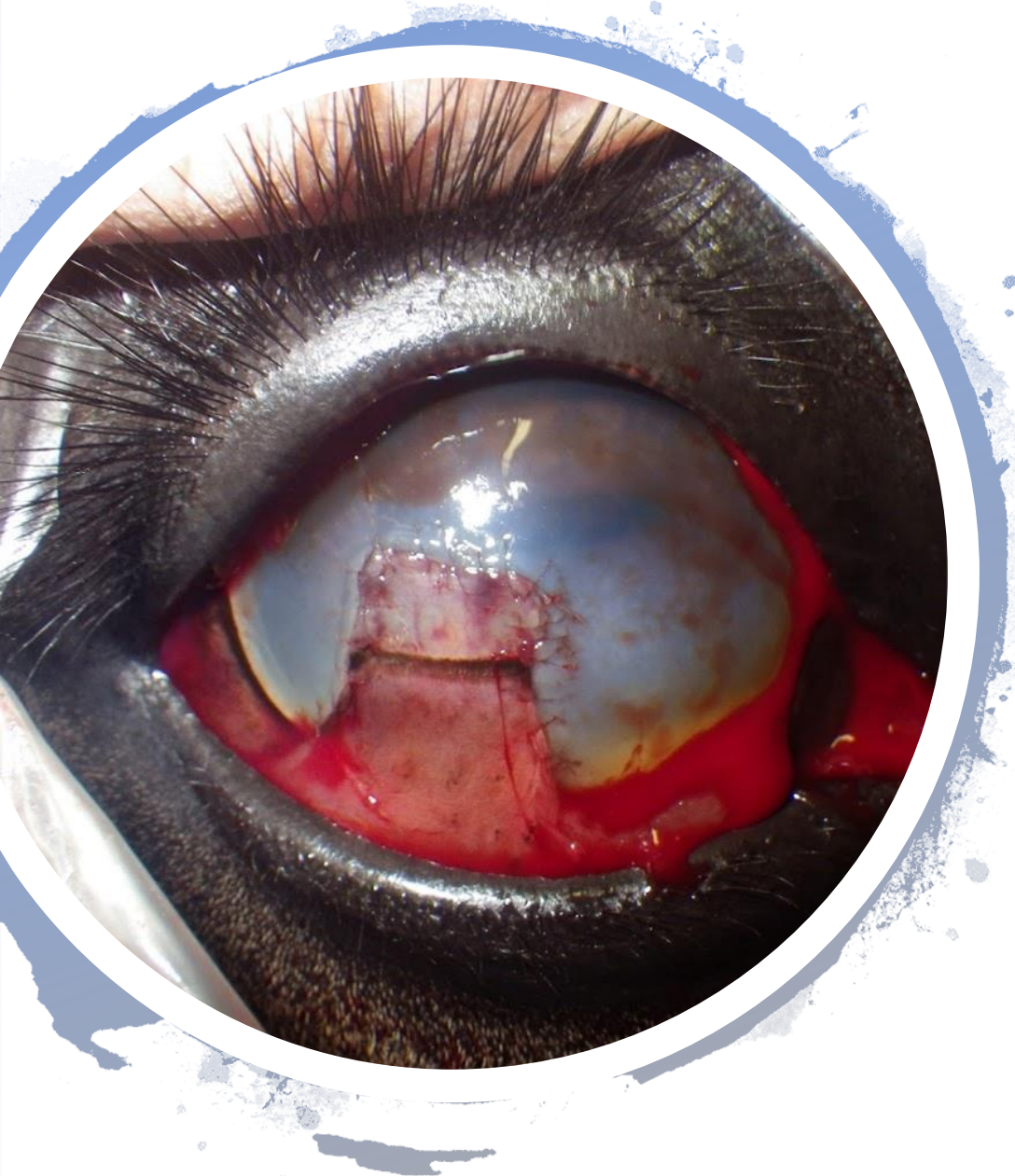
Standing enucleation: modified trans-palpebral lid split technique





Standing enucleation: modified trans-palpebral lid split technique



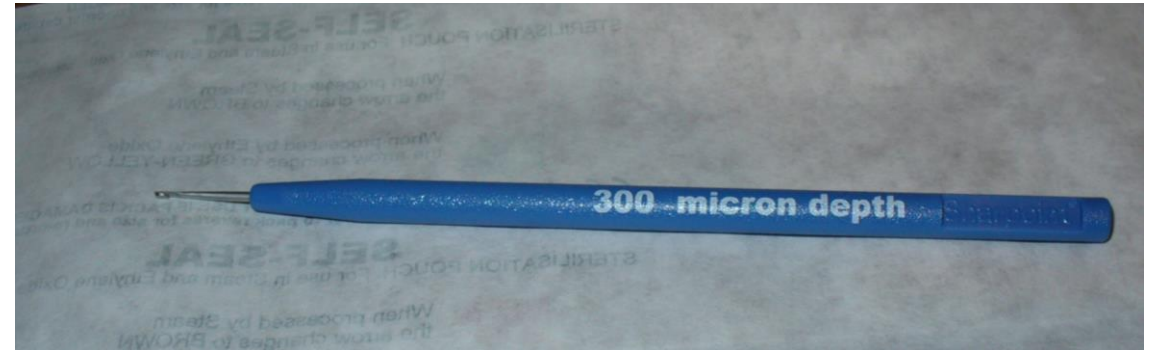


What's new in Corneal surgery?

- Restricted depth corneal knives and corneal lamellar dissectors allow superficial keratectomy to be performed more safely in the standing patient even where the surgeon doesn't have extensive microsurgical experience. These instruments make corneal biopsy a safe diagnostic and treatment option for many equine patients.
- The diamond bur (aka Alger Brush) provides a safer alternative option for indolent ulcers than the anterior grid and punctate keratotomy. Care should be taken to clean the instrument properly to reduce the risk of iatrogenic corneal melting and or infection.
- Corneal grafting techniques: Conjunctival grafting techniques have been widely used for many year, whilst still very useful corneal grafting techniques (e.g. corneo-conjunctival transposition and donor corneal grafting) are now a routine part of the Veterinary ophthalmologists armoury. The availability of a number of biografts (e.g. amnion and "collagen" grafting materials) further increases corneal repair options.

Corneal reconstruction: tools to help

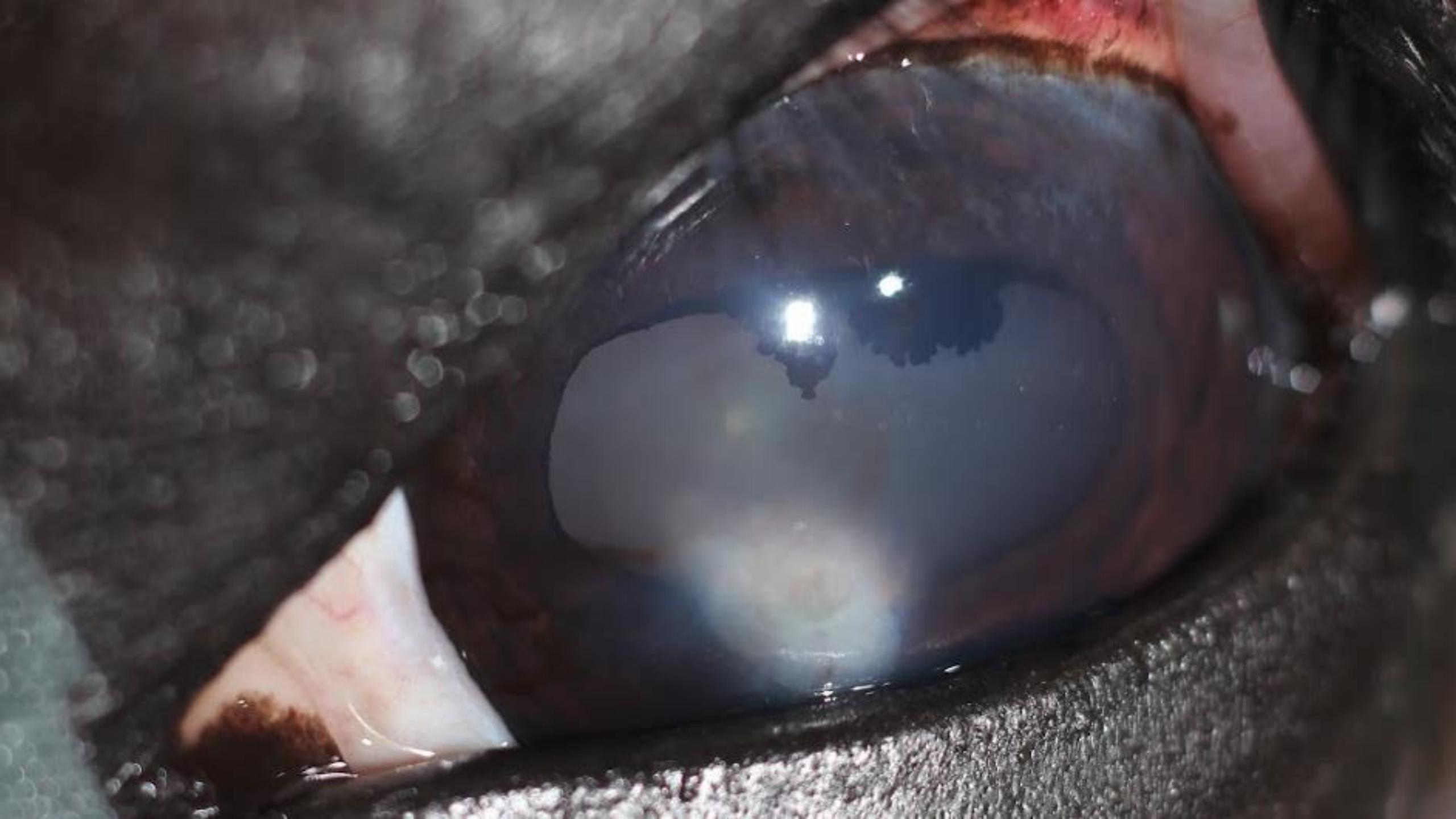
- New instrumentation safer surgery & more done standing
- Disposable microsurgical instruments
- Safer incisions : restricted depth knives
- Safer lamellar dissection : Martinez corneal dissector (or crescent knife)
- **Magnification, light and practice**

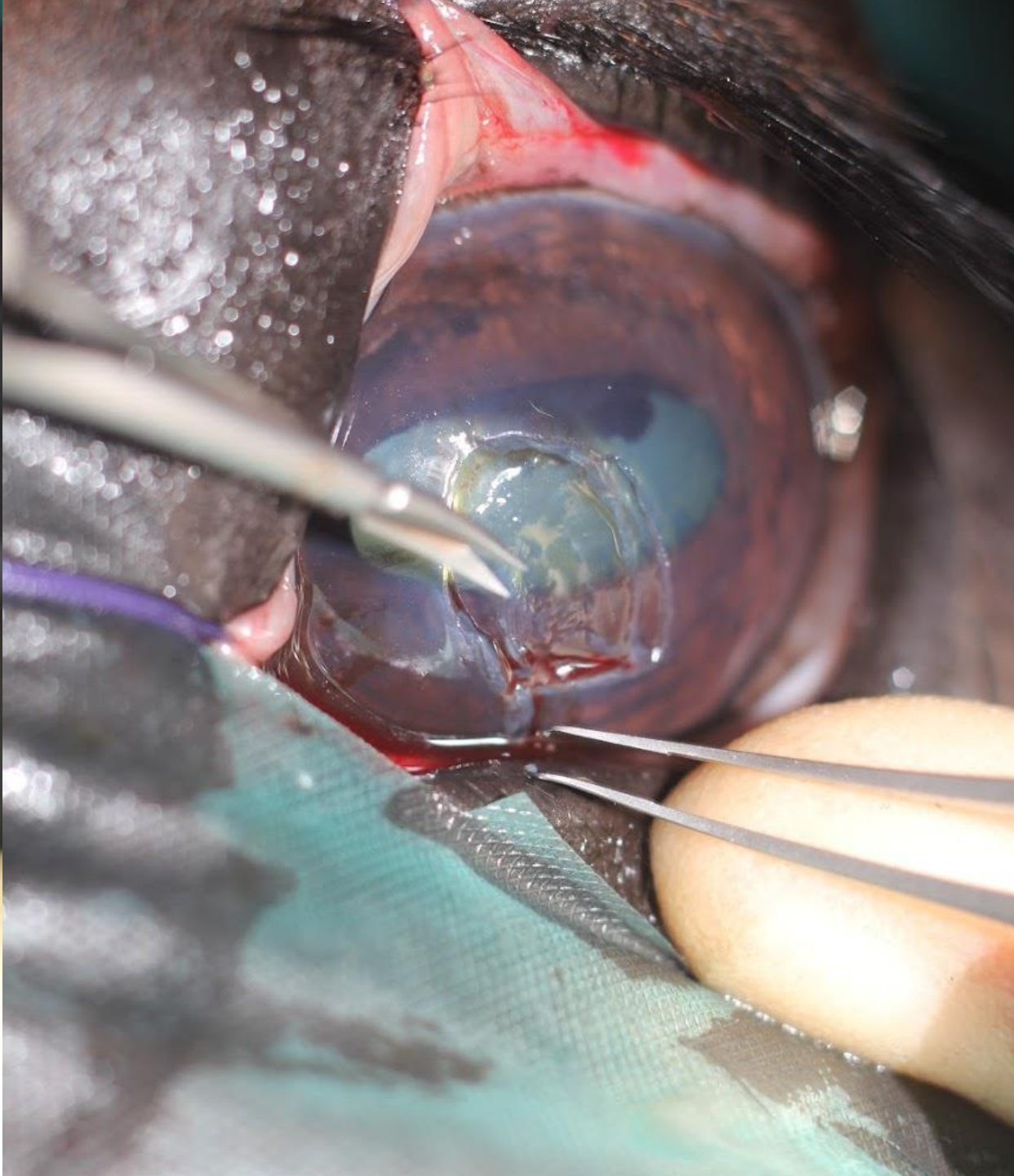
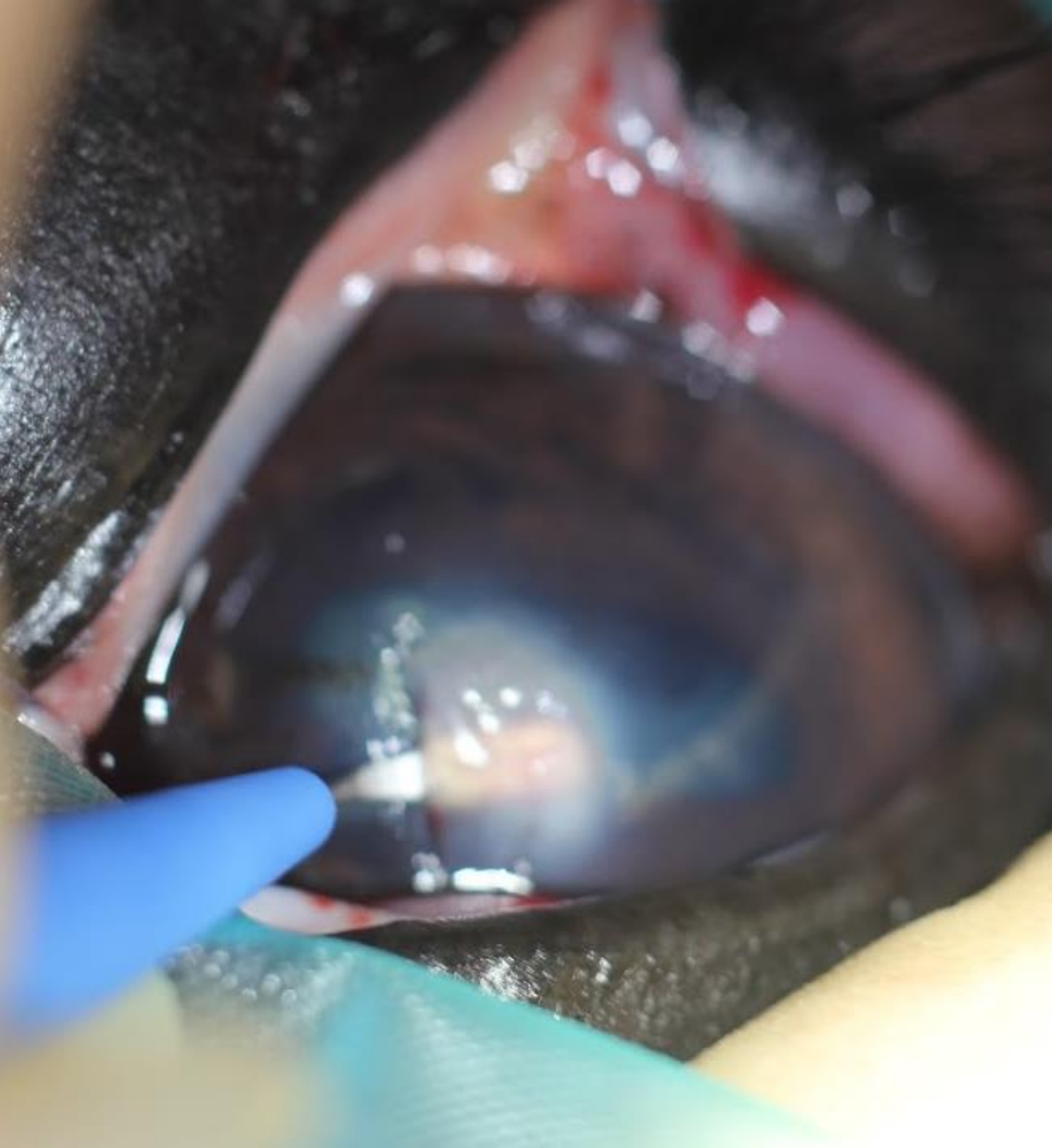

Corneal reconstruction: tools to help

- New instrumentation safer surgery & more done standing
- Disposable microsurgical instruments
- Safer incisions : restricted depth knives
- Safer lamellar dissection : Martinez corneal dissector (or crescent knife)
- **Magnification, light and practice**



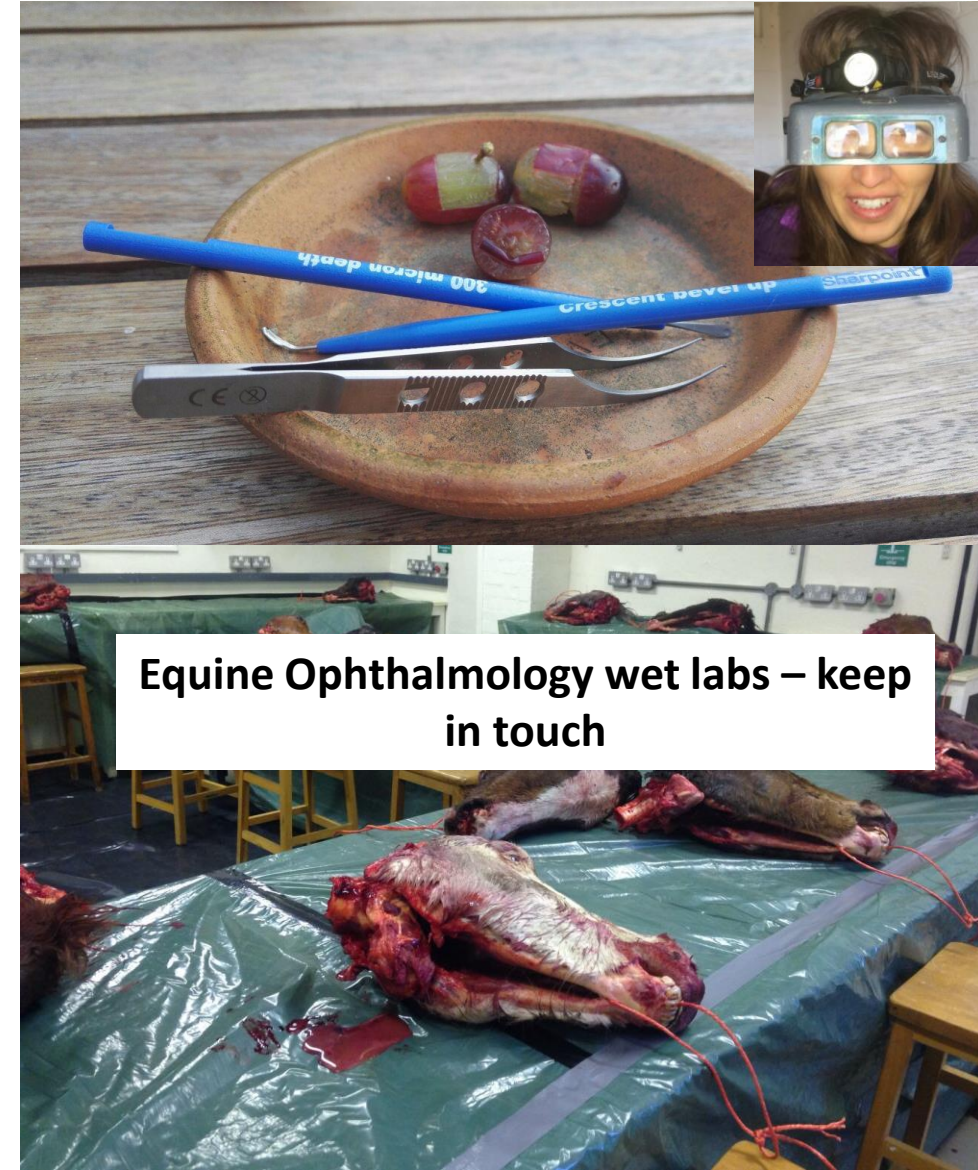






Corneal reconstruction: tools to help

- New instrumentation safer surgery & more done standing
- Disposable microsurgical instruments
- Safer incisions : restricted depth knives
- Safer lamellar dissection : Martinez corneal dissector (or crescent knife)
- **Magnification, light and practice**



Corneal reconstruction: cross linking

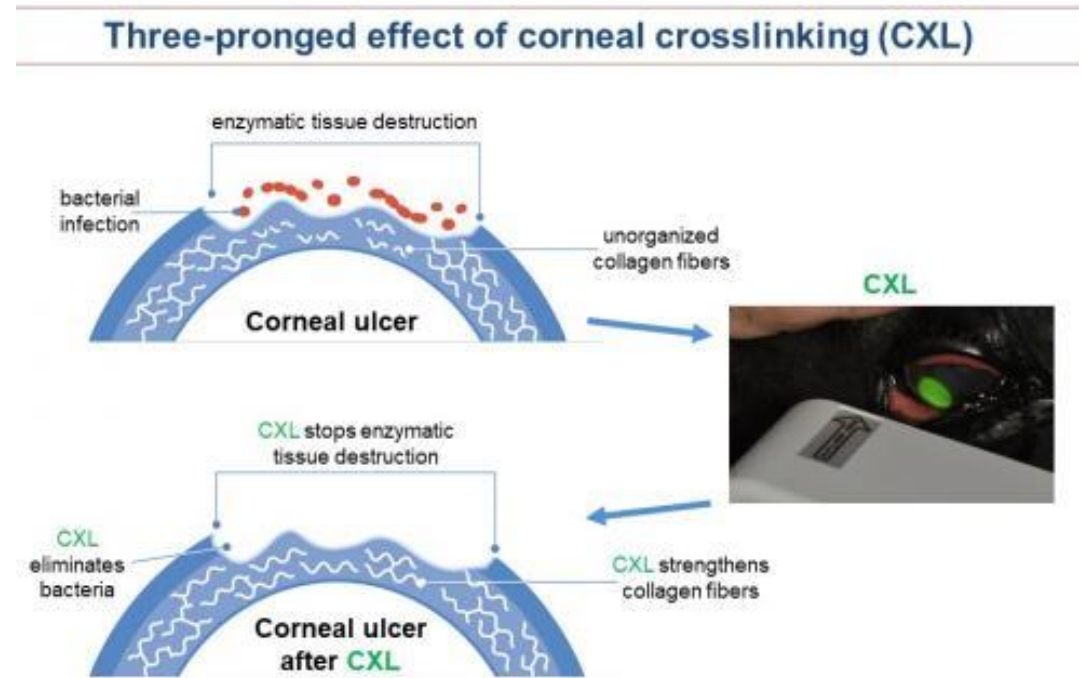
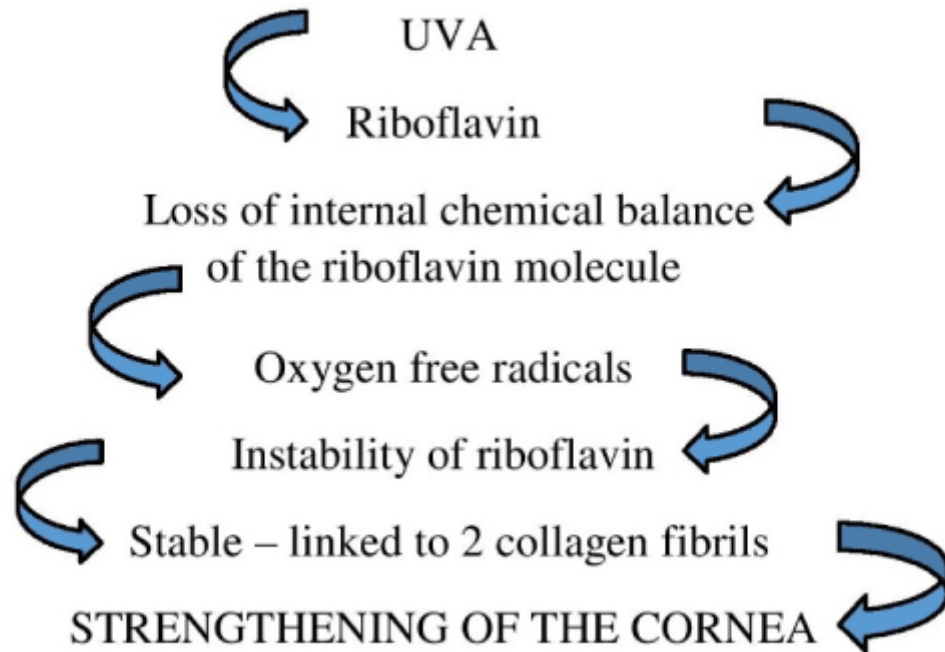
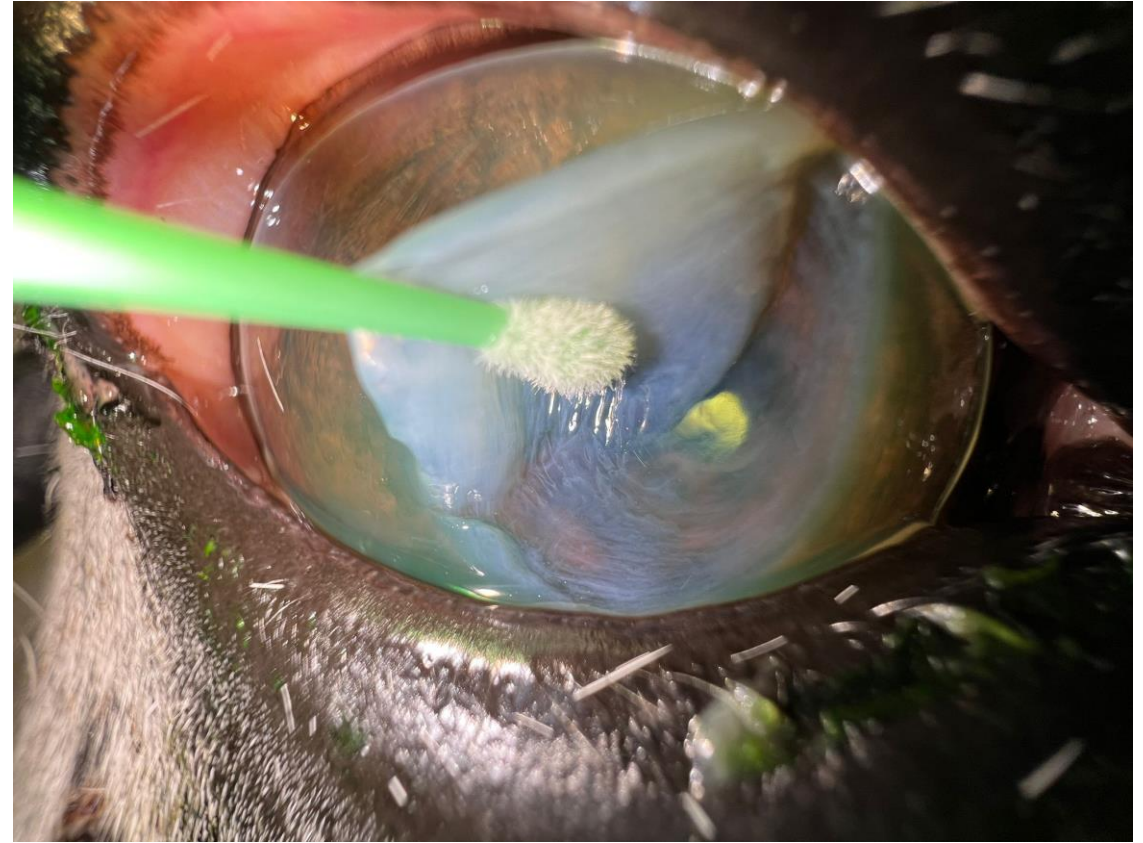
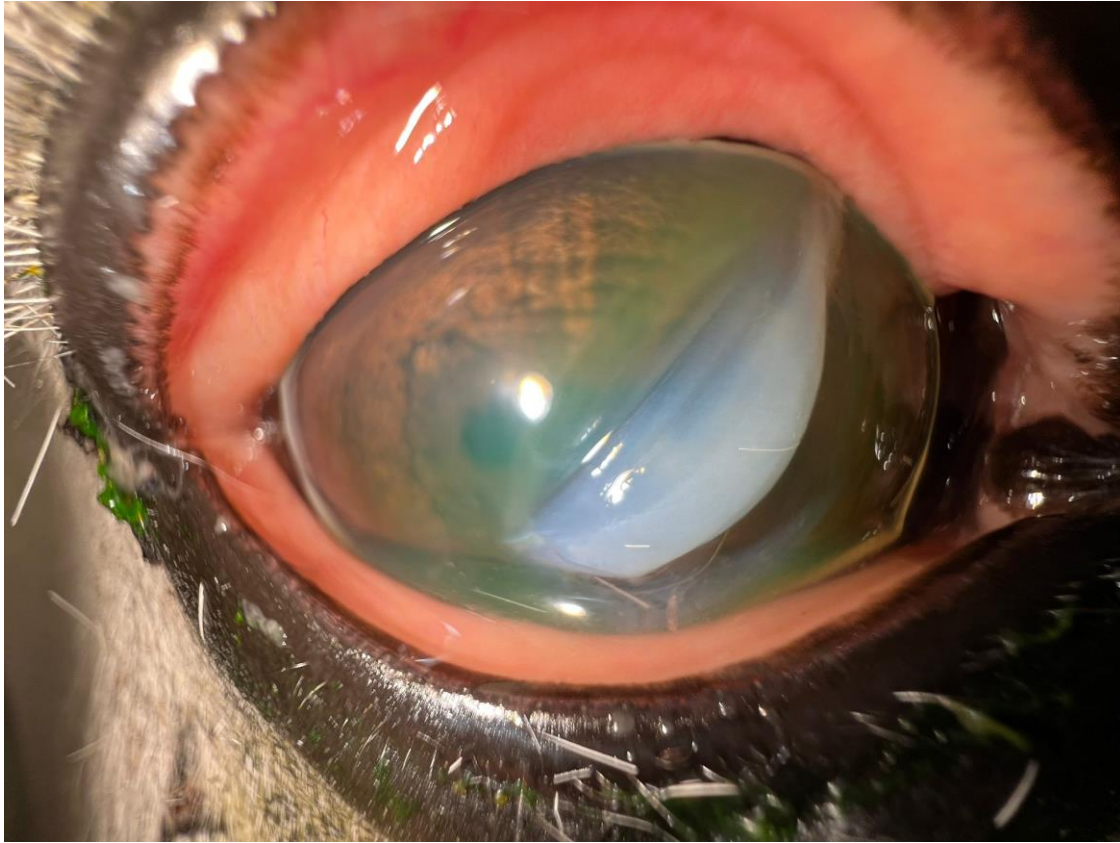


Image: Dr Simon Potts


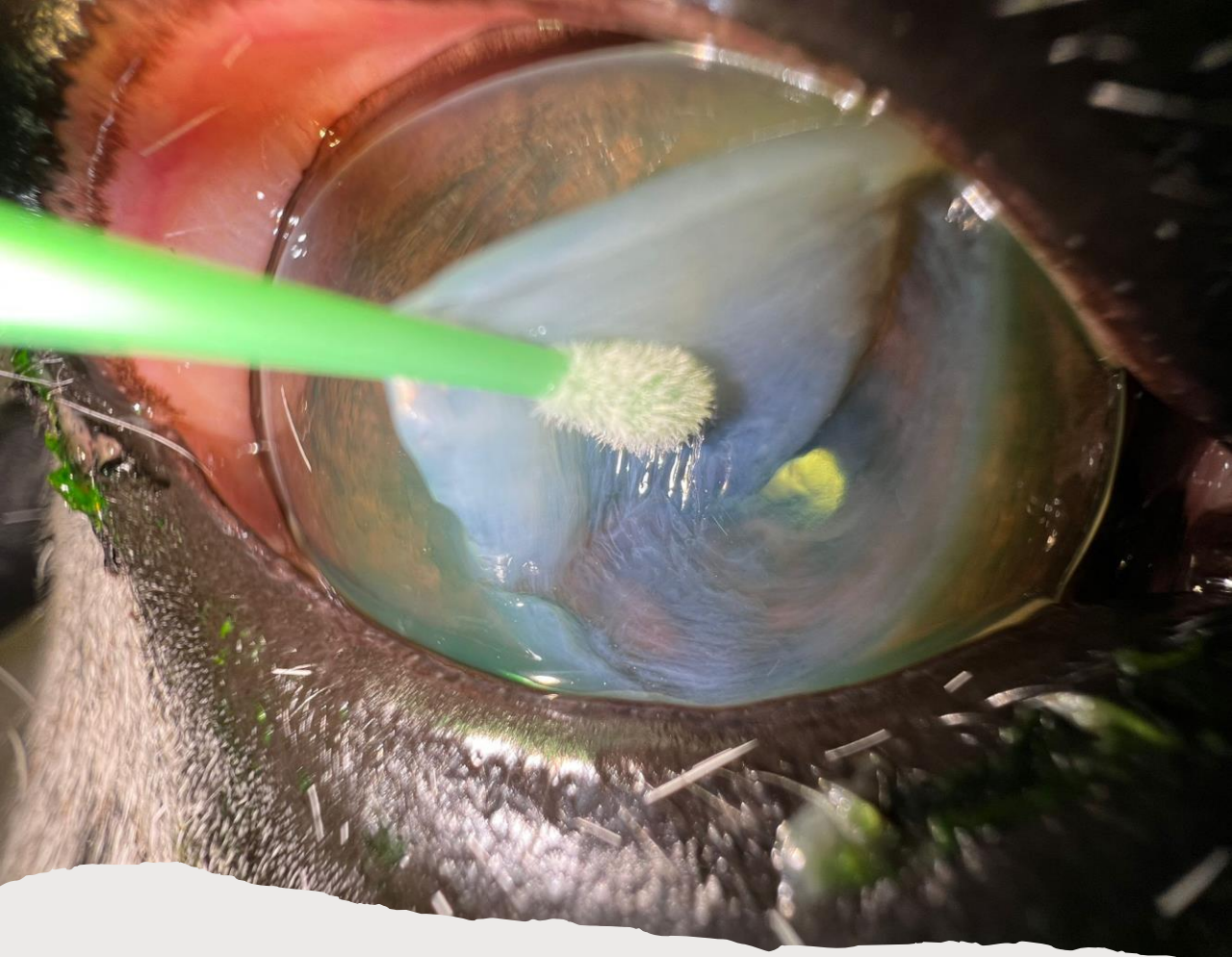
Monty – traumatic near full thickness laceration. Infected and melting.



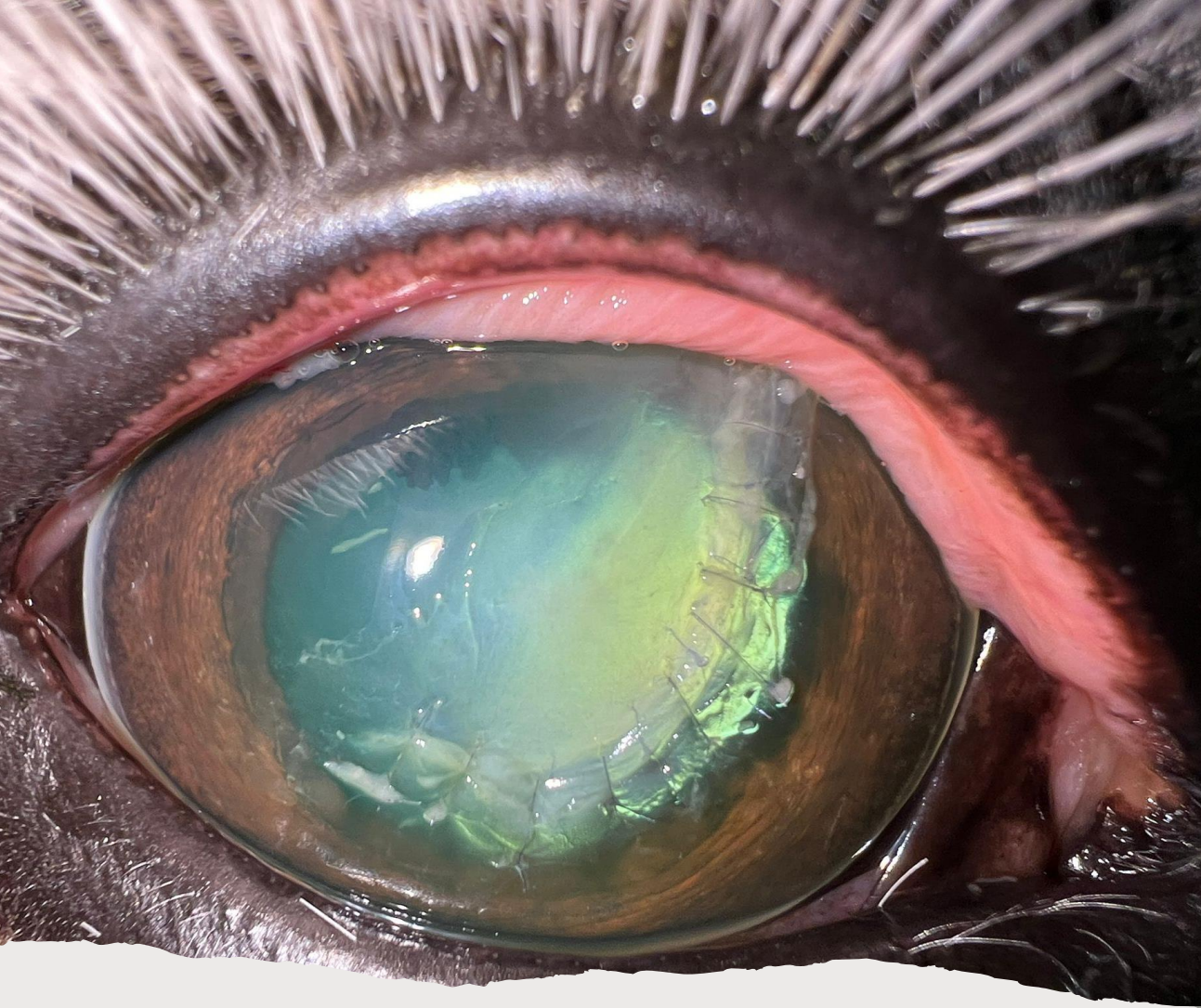
Protocol

- Riboflavin q 2 mins for 20mins
- Until Riboflavin seen in aqueous
- “Sterilization protocol” high power, short duration (2mins)
- “Crosslinking protocol” low power, long duration (30mins)



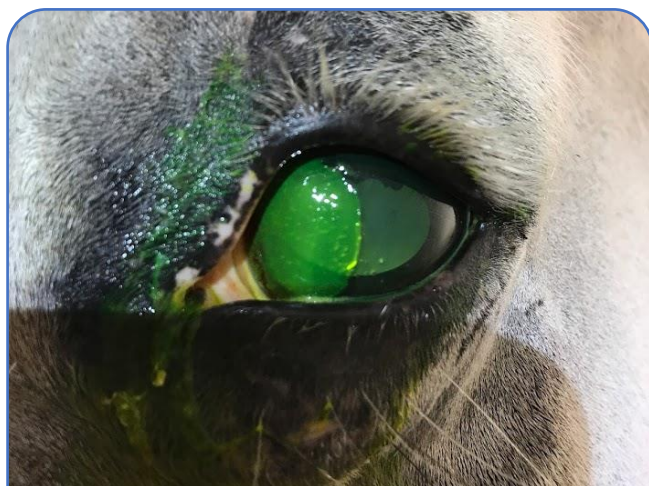


Post CXL: Flap & wound bed thinner & firmer

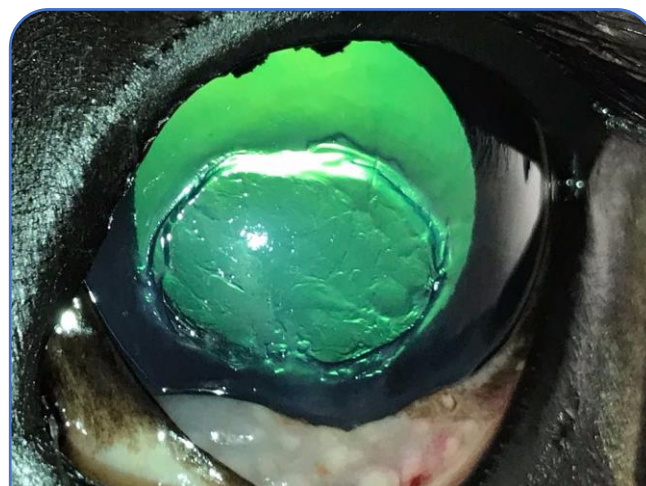


Primary closure – 9-0 PGA


The non-healing ulcer: new tools



Punctate
keratotomy



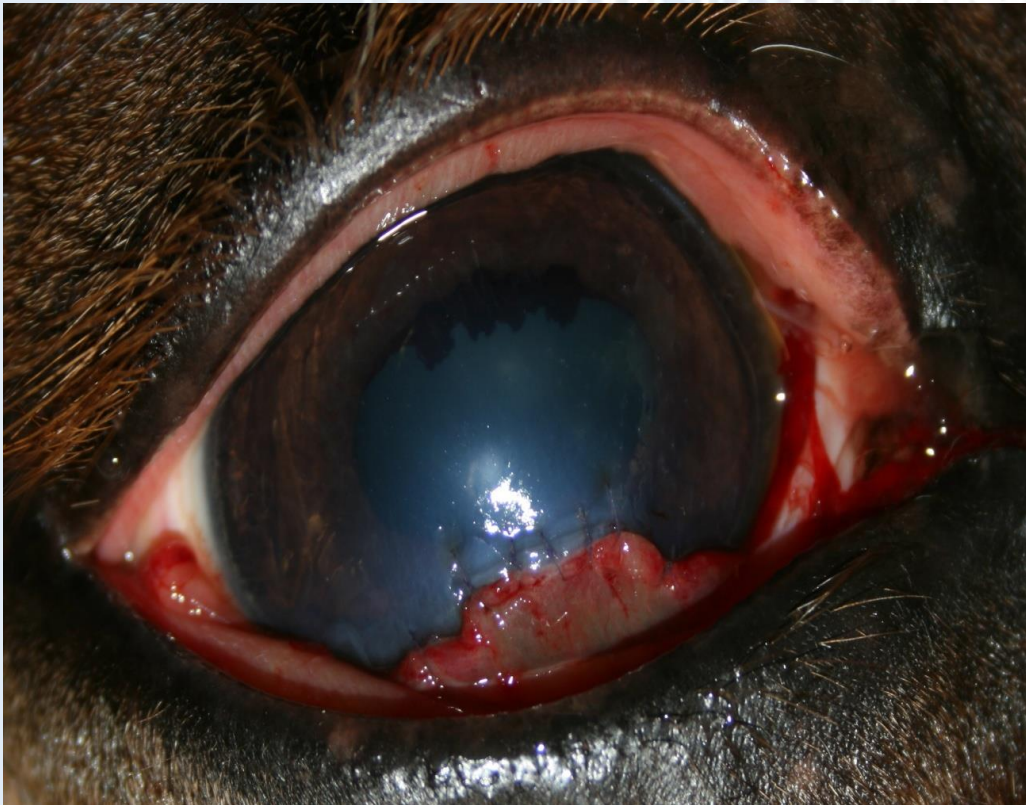Superficial
keratectomy



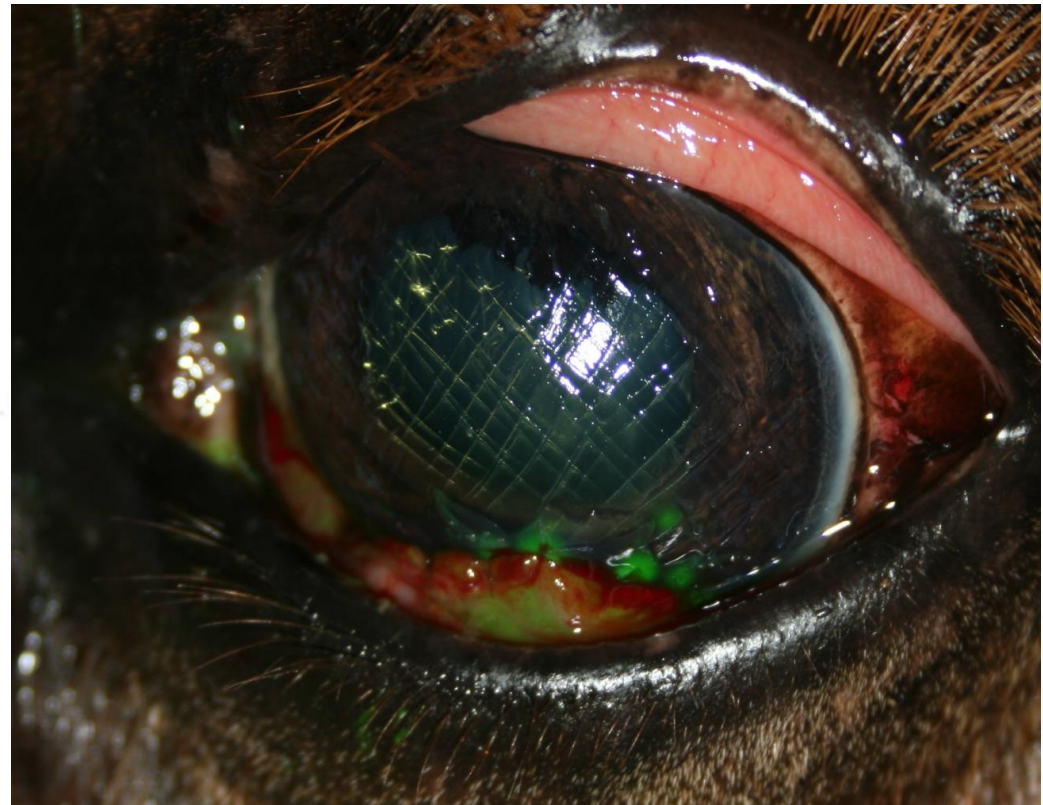Diamond burr
debridement

Surgical treatment


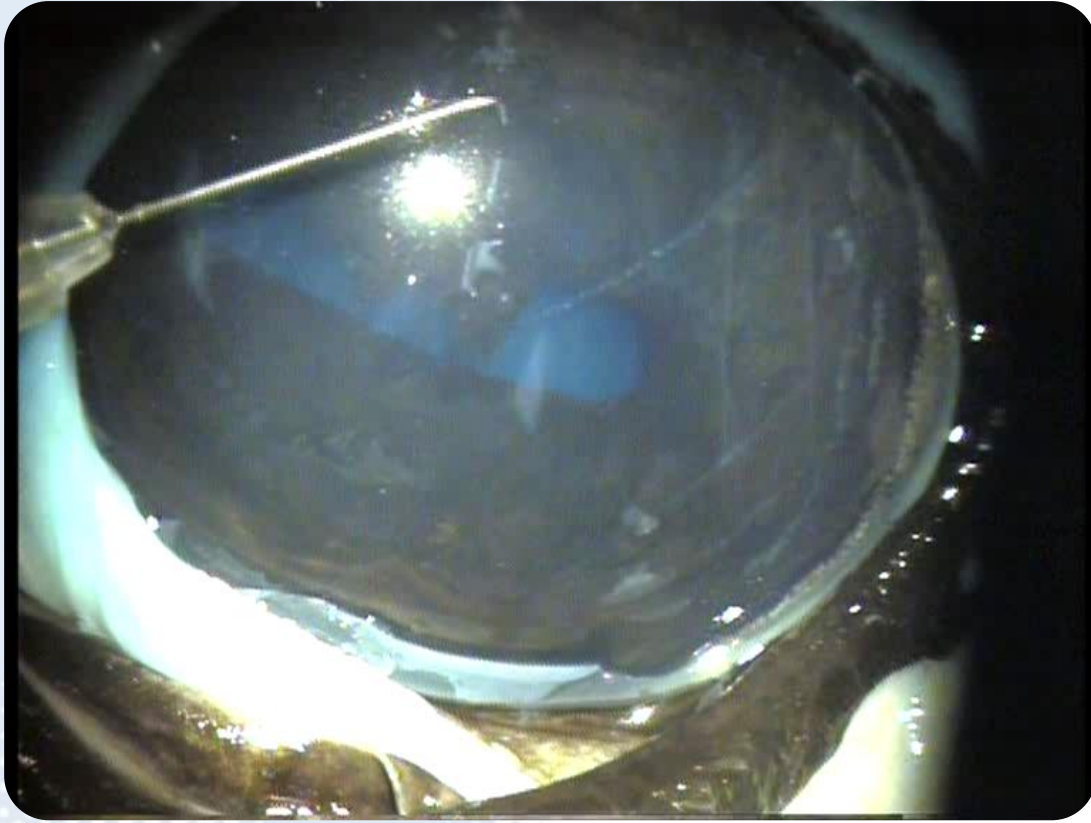
Anterior Punctate Keratotomy



Anterior Grid Keratotomy

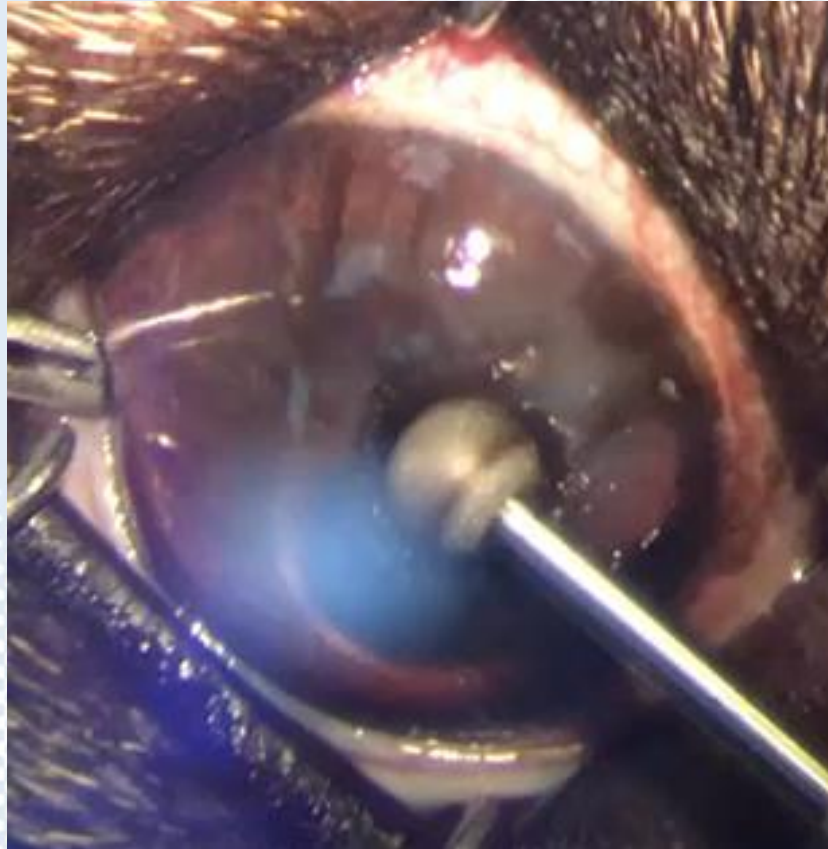


APK: anterior punctate keratotomy

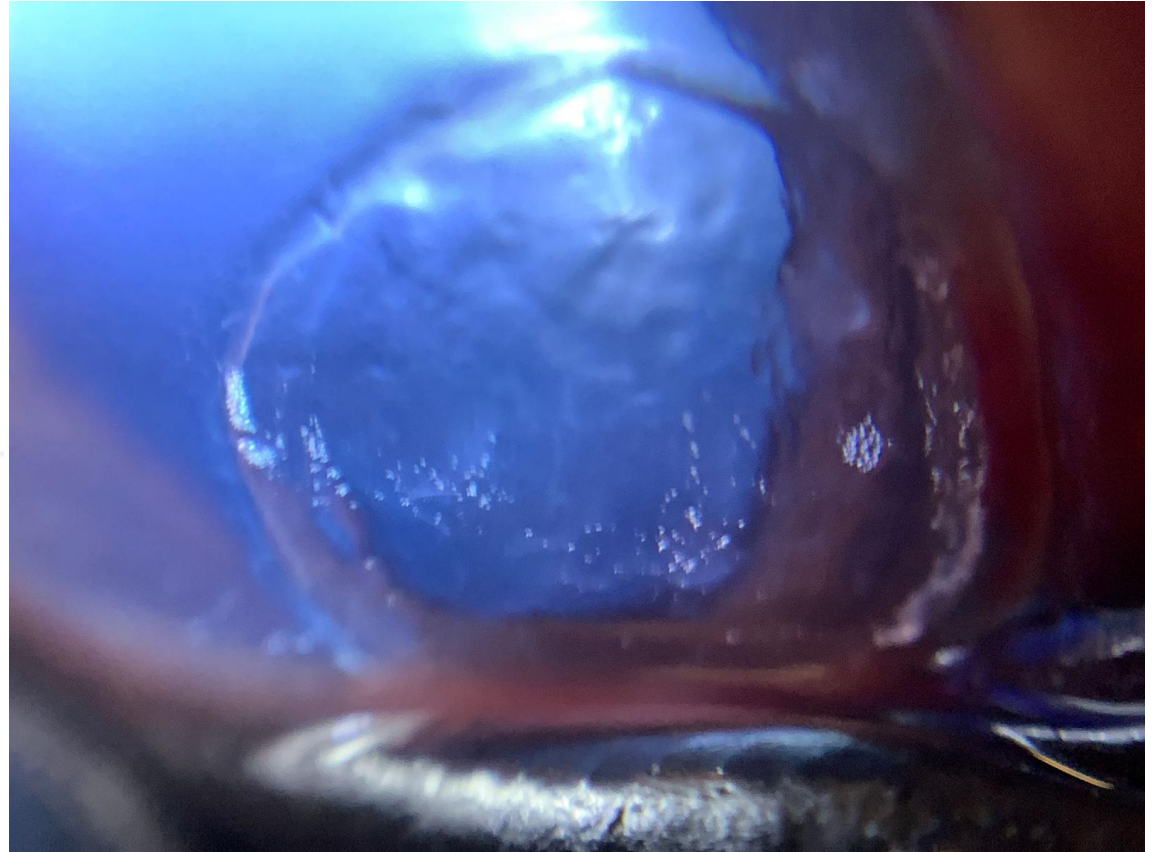


Surgical treatment

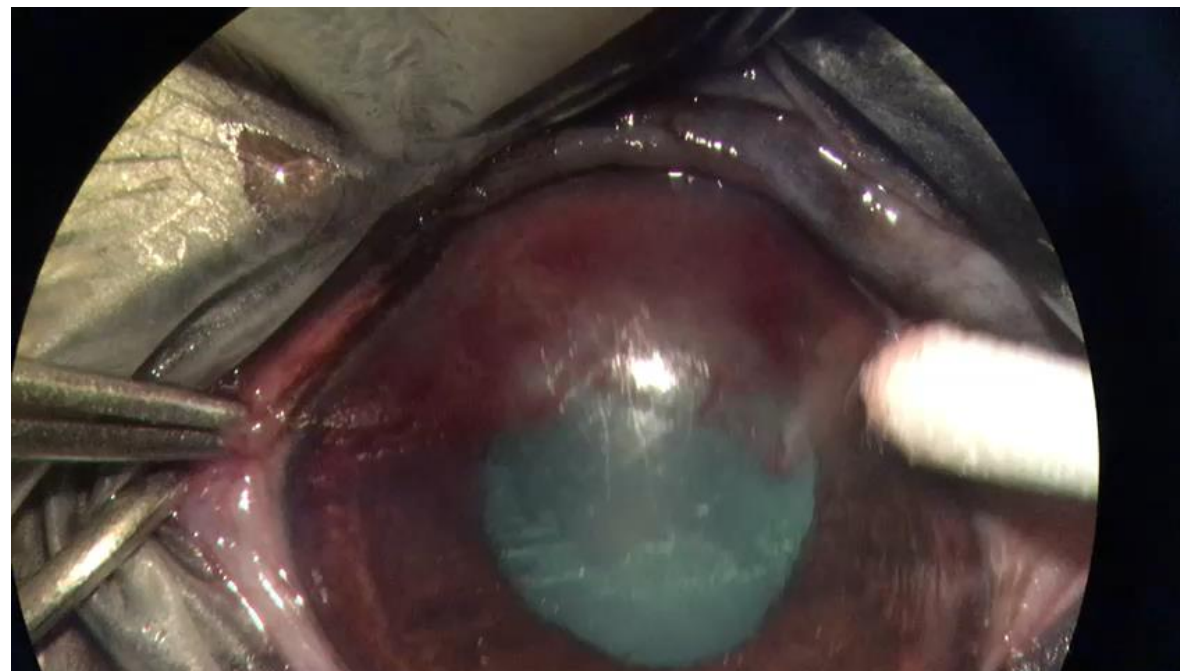
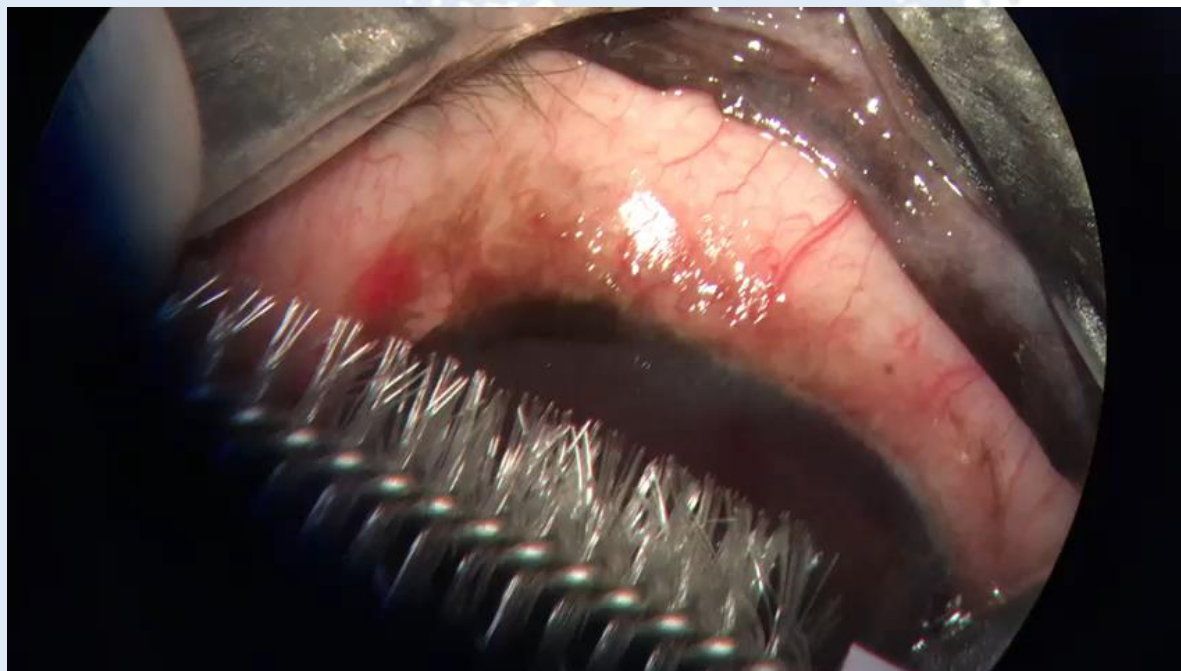
Diamond burr debridement




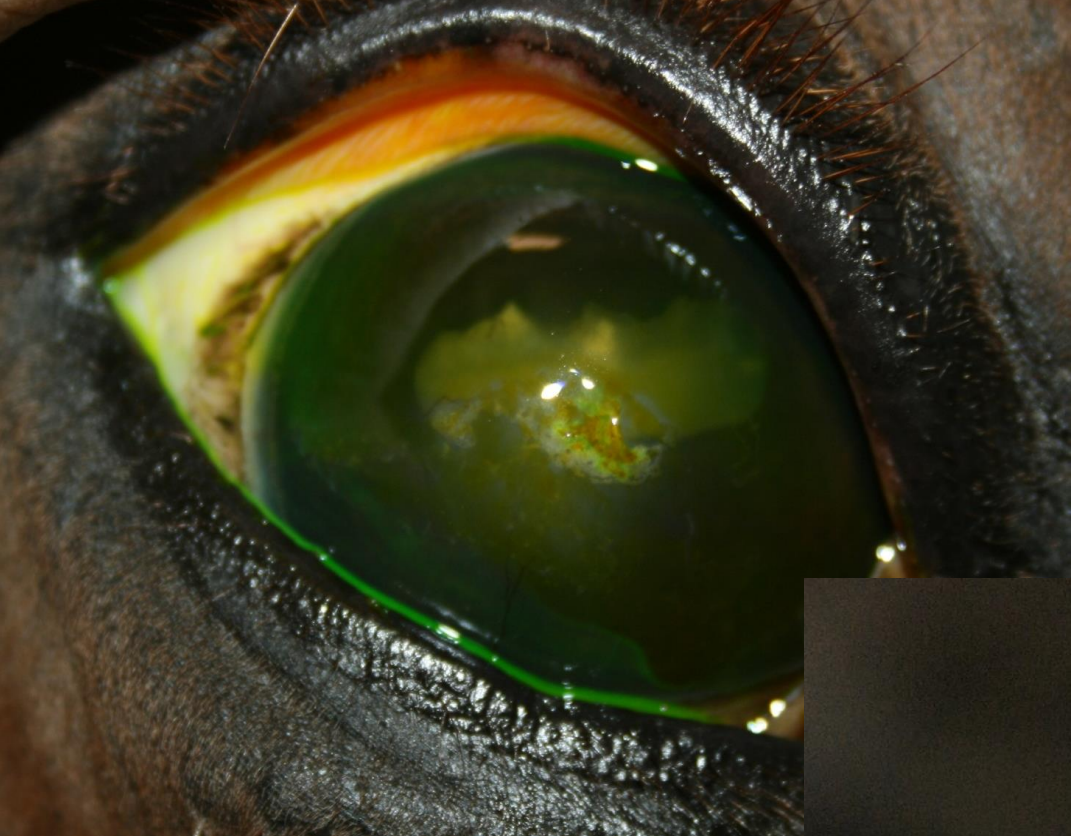


Superficial keratectomy



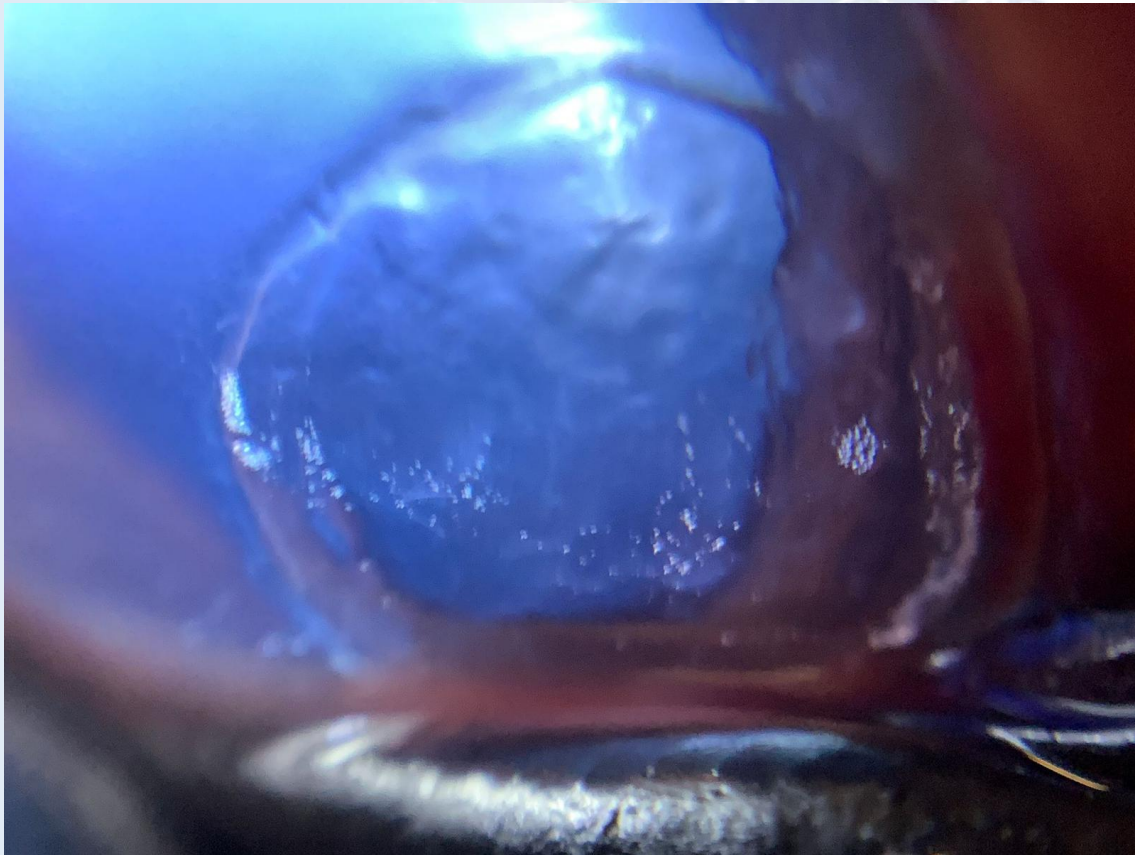
Remember: Cytology & Culture first



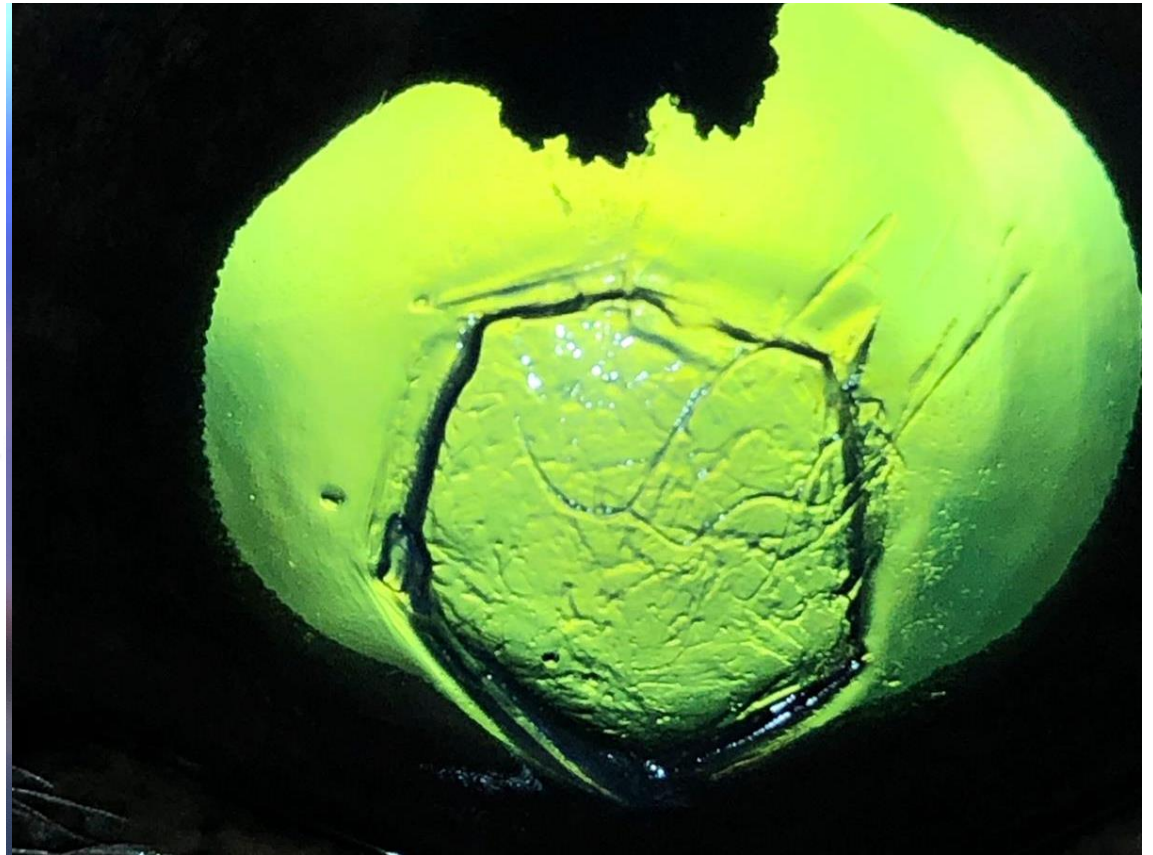


Surgical treatment

Superficial keratectomy

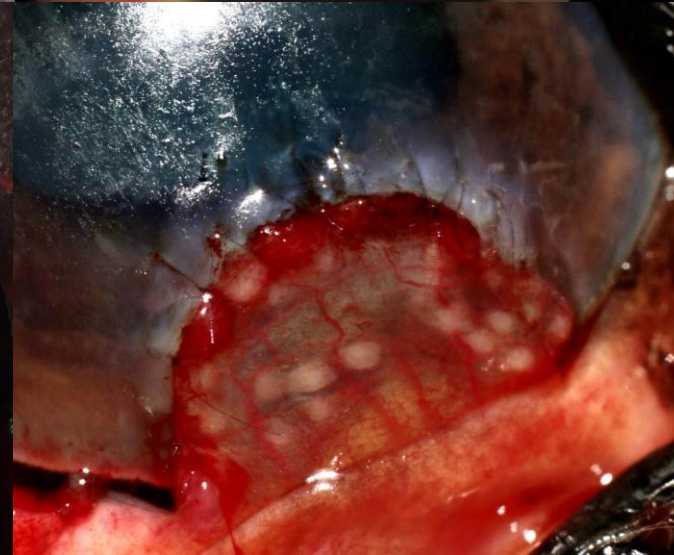
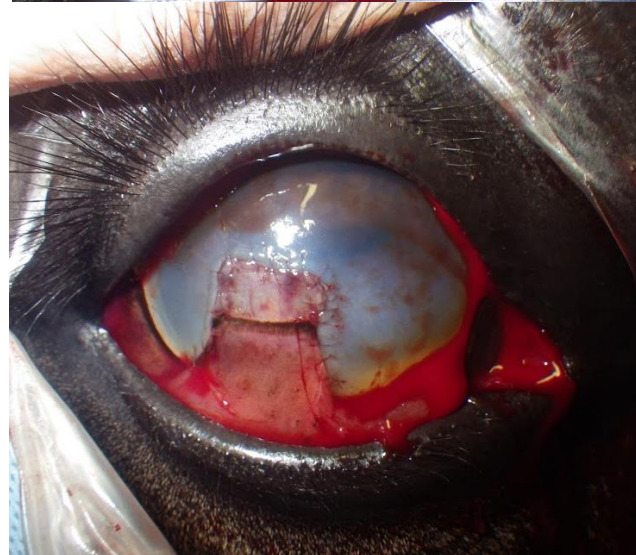
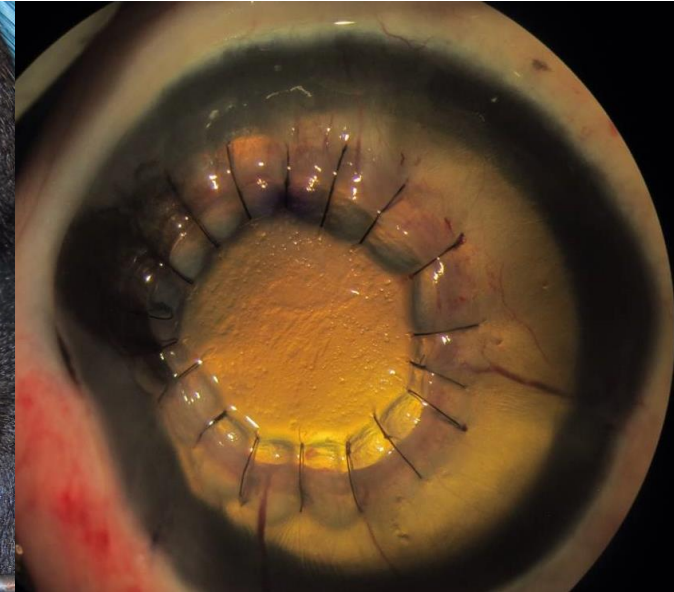
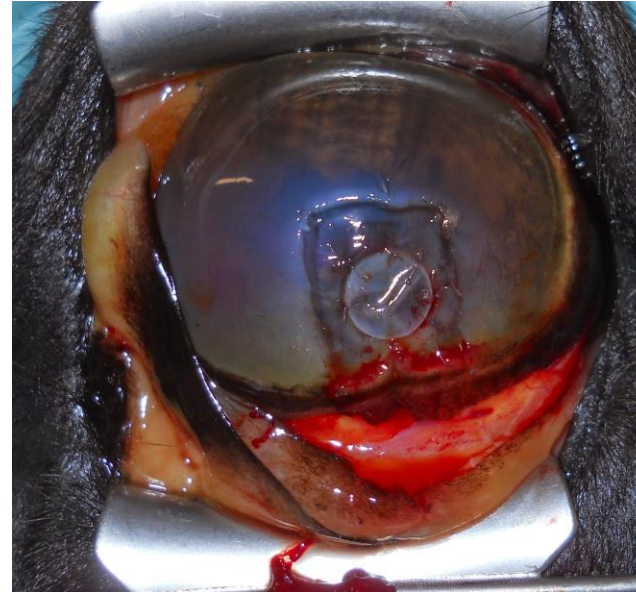


Superficial keratectomy



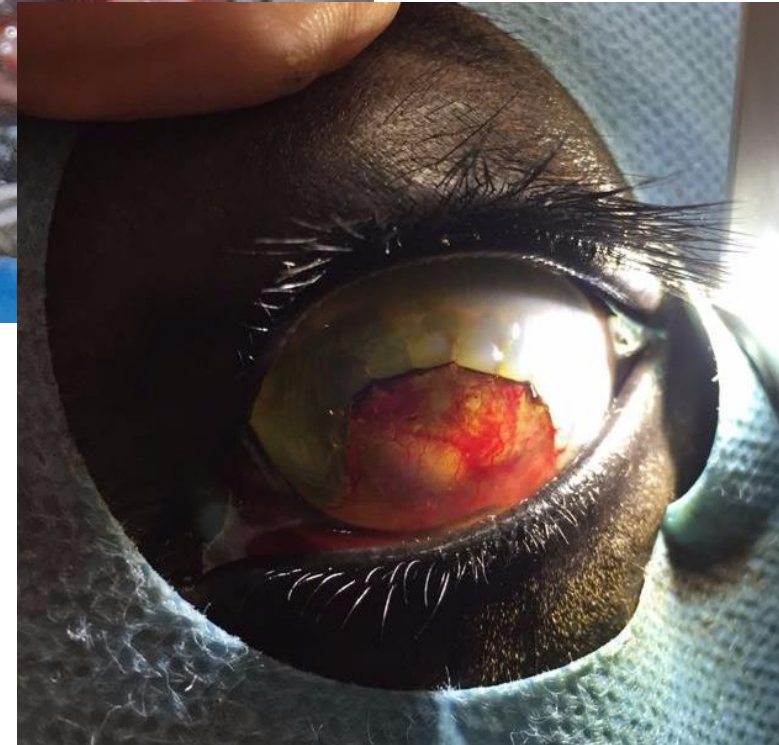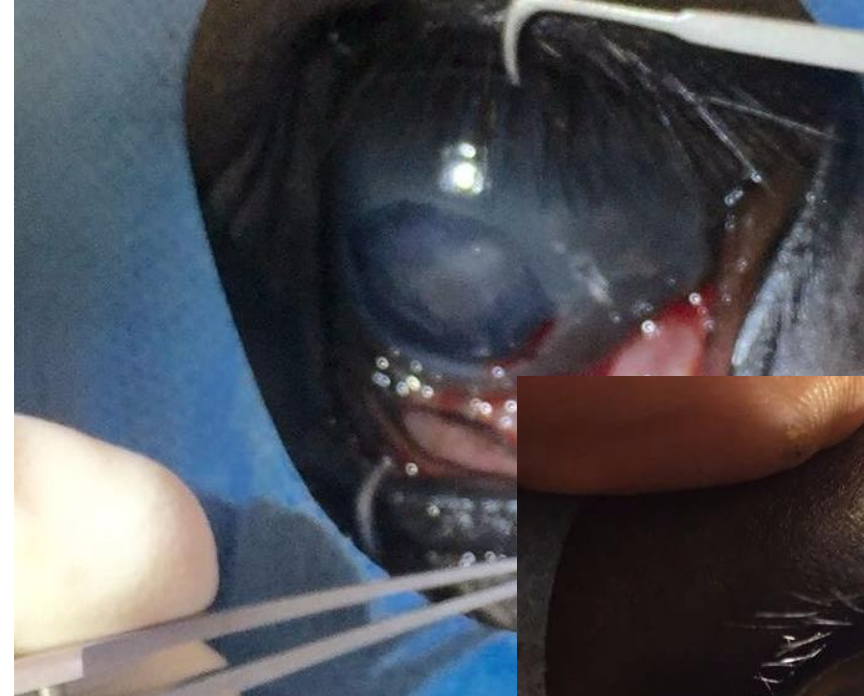Corneal grafting techniques

- Allografts
 - Conjunctiva
 - Corneal sliding grafts
 - Corneal lamellar grafts
 - Penetrating & lamellar keratoplasty
- Xenografts
 - (cornea)
 - Amnion
 - “Collagen scaffolds”



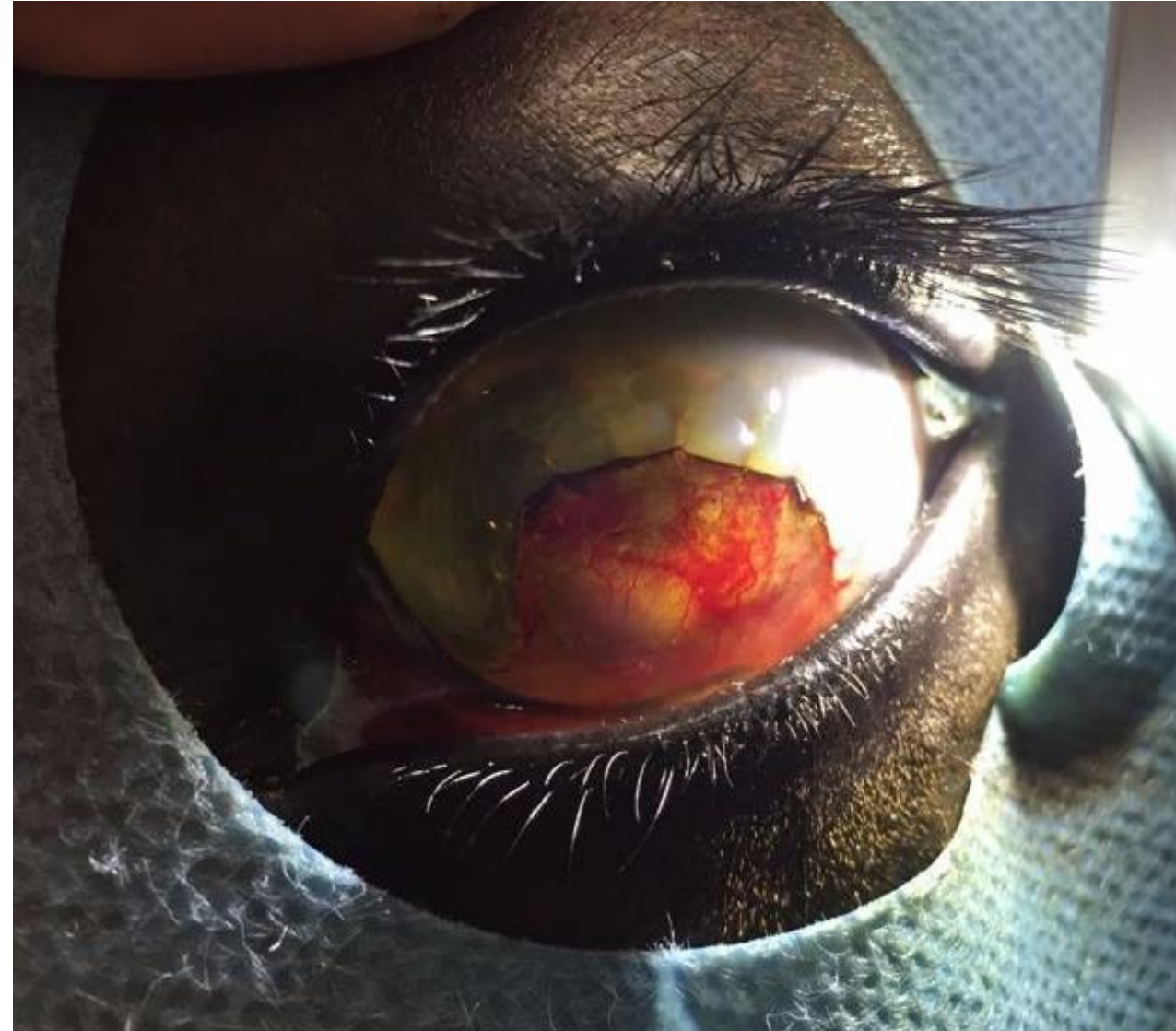Corneal grafting techniques

- Allografts
 - Conjunctiva
 - Outside the visual axis
 - >40% stroma left
 - Avoid rotational pedicle graft
 - When fungus suspected
 - Corneal sliding grafts
 - Corneal lamellar grafts
 - Penetrating & lamellar keratoplasty
- Xenografts
 - (cornea)
 - Amnion
 - “Collagen scaffolds”



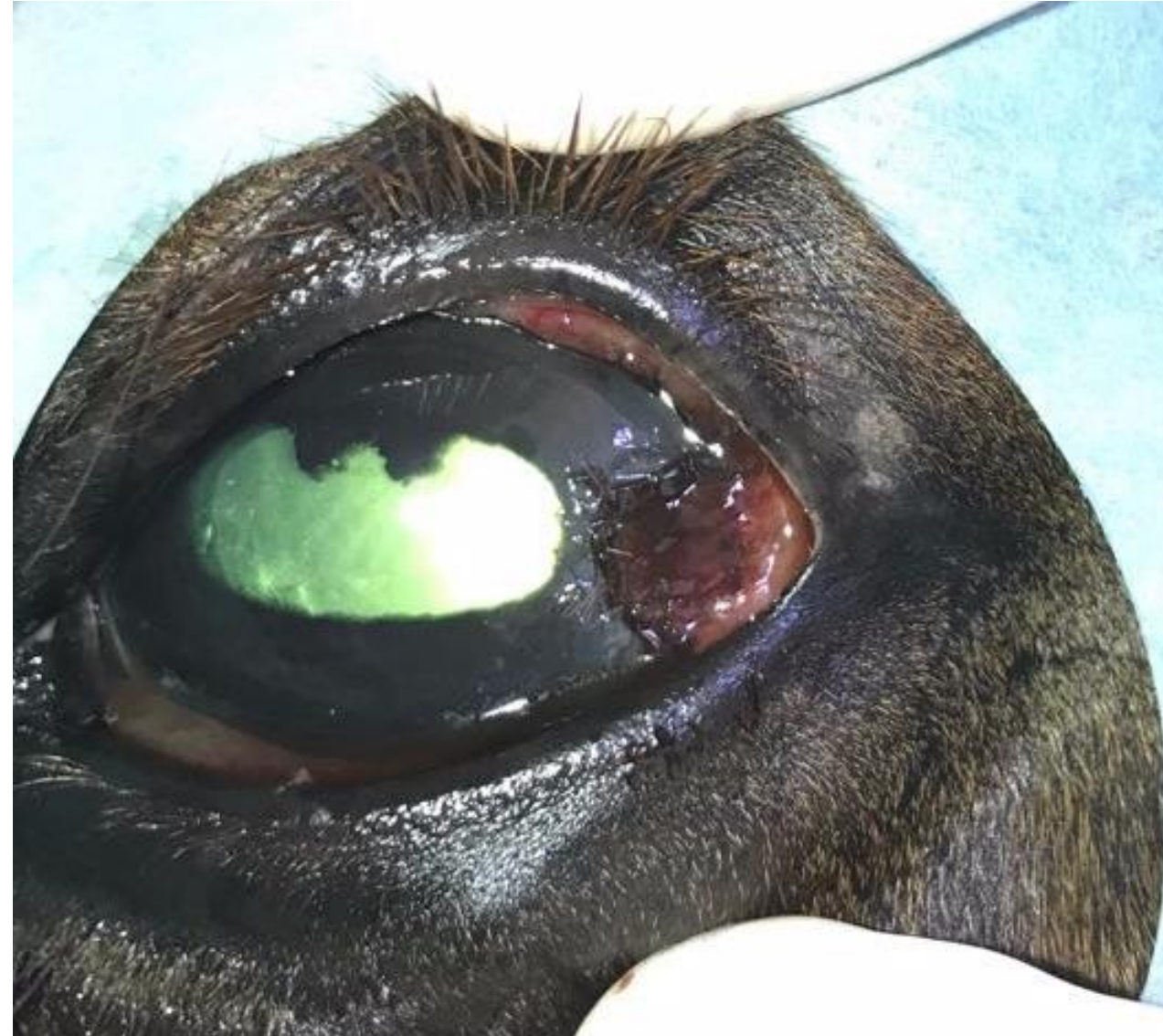Corneal grafting techniques

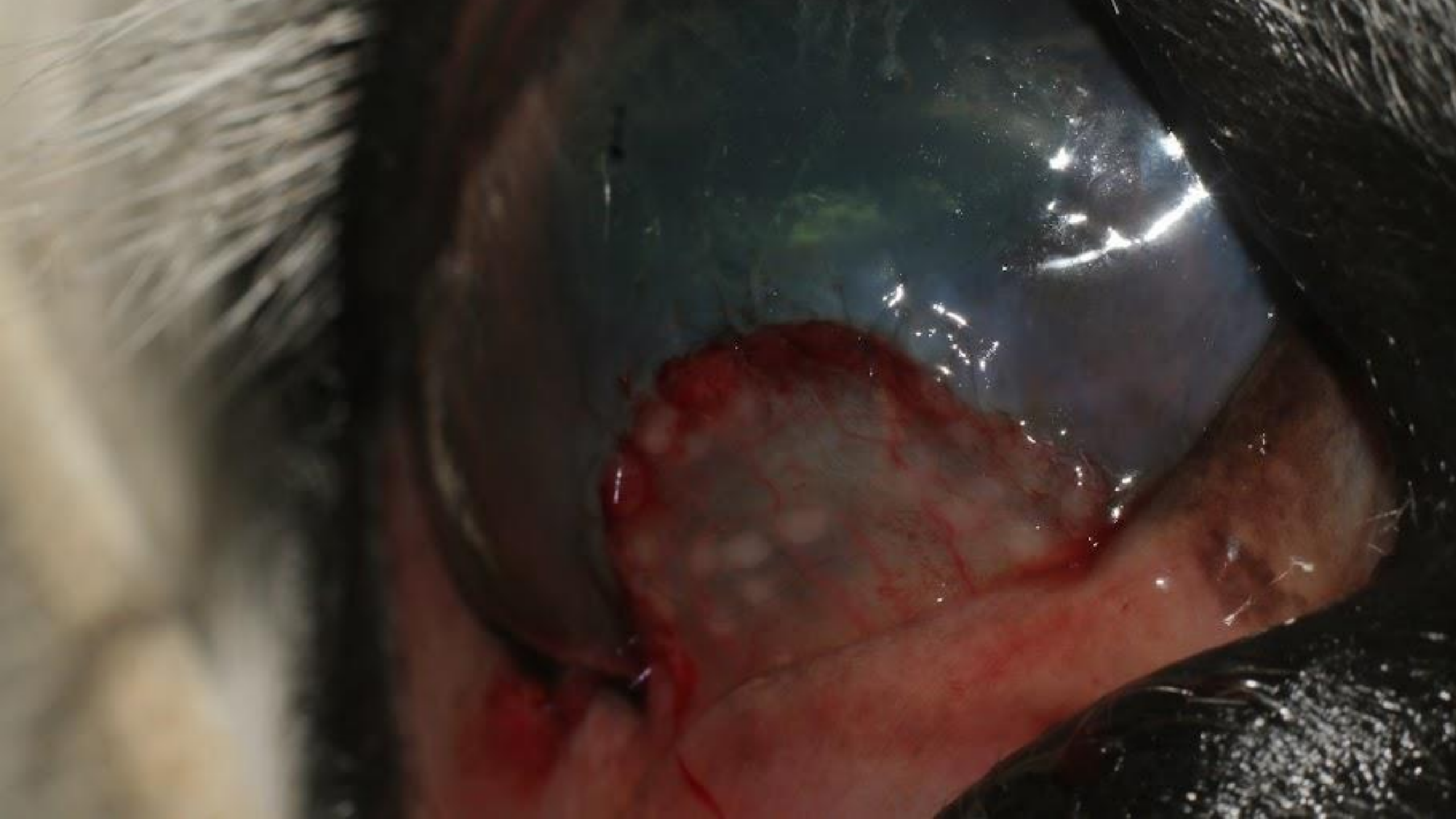
- Allografts
 - Conjunctiva
 - Outside the visual axis
 - >40% stroma left
 - Avoid rotational pedicle graft
 - When fungus suspected
 - Corneal sliding grafts
 - Corneal lamellar grafts
 - Penetrating & lamellar keratoplasty
- Xenografts
 - (cornea)
 - Amnion
 - “Collagen scaffolds”

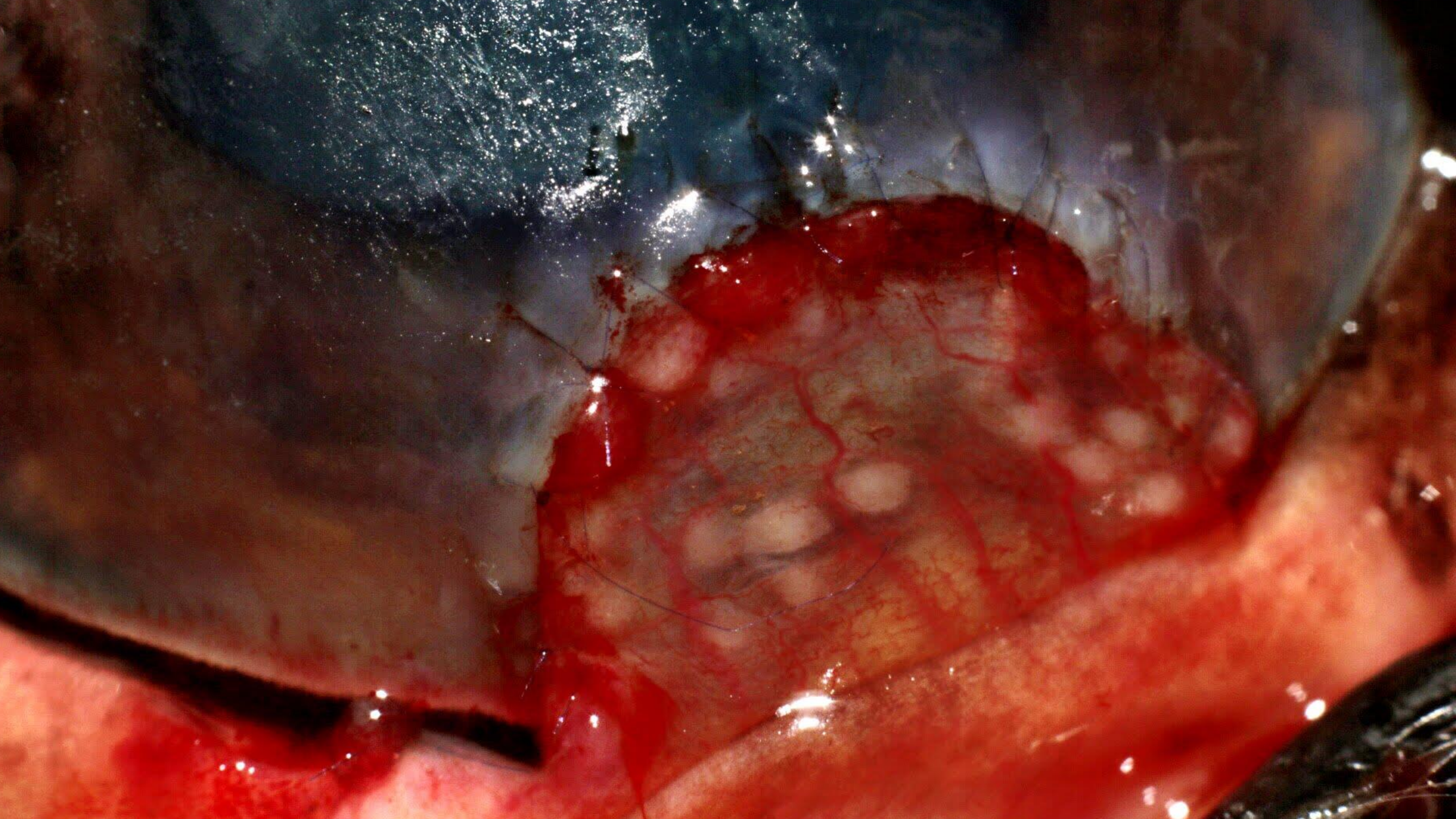


Corneal grafting techniques

- Allografts
 - Conjunctiva
 - Outside the visual axis
 - >40% stroma left
 - Avoid rotational pedicle graft
 - When fungus suspected
 - Corneal sliding grafts
 - Corneal lamellar grafts
 - Penetrating & lamellar keratoplasty
- Xenografts
 - (cornea)
 - Amnion
 - “Collagen scaffolds”

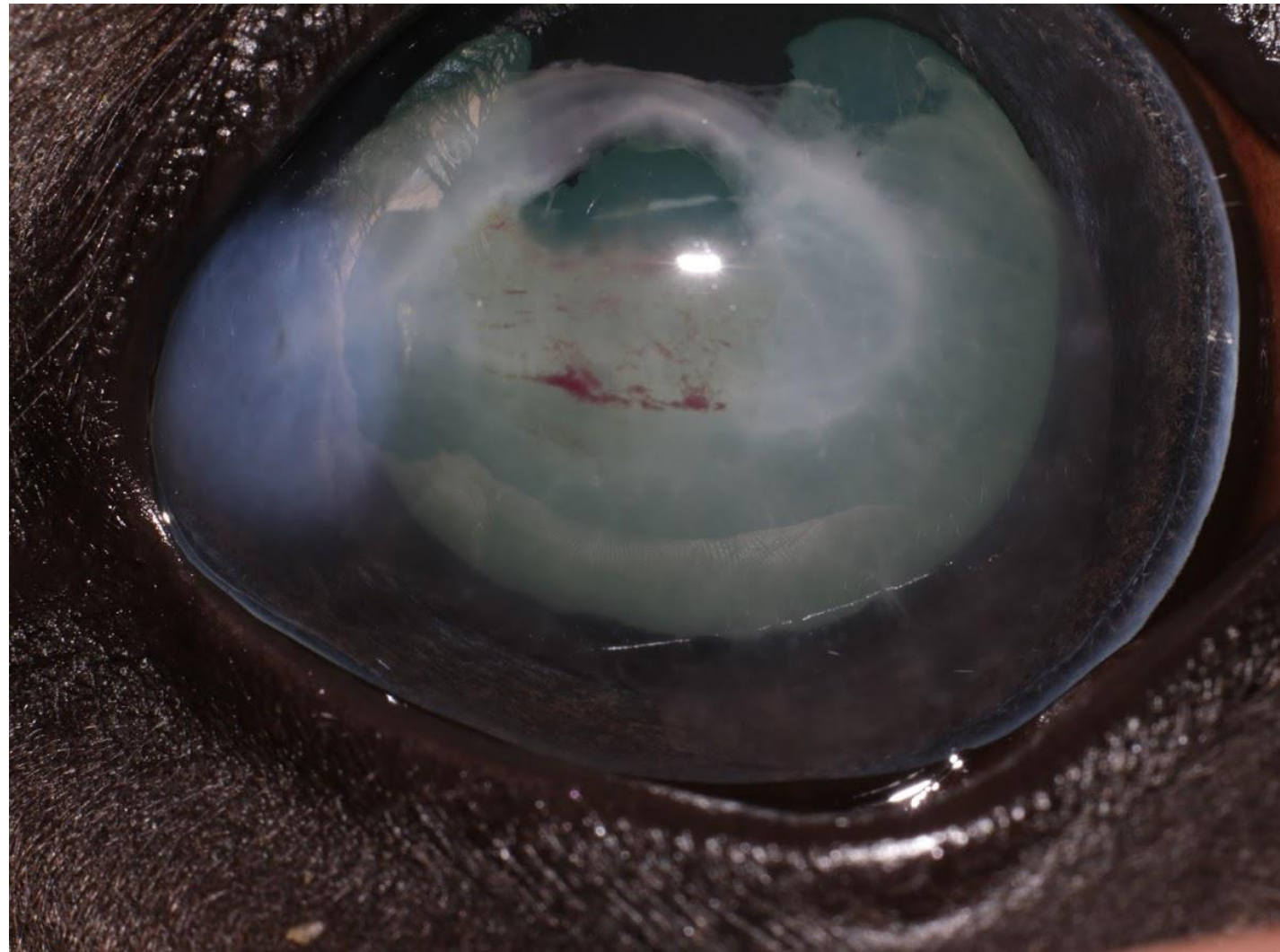






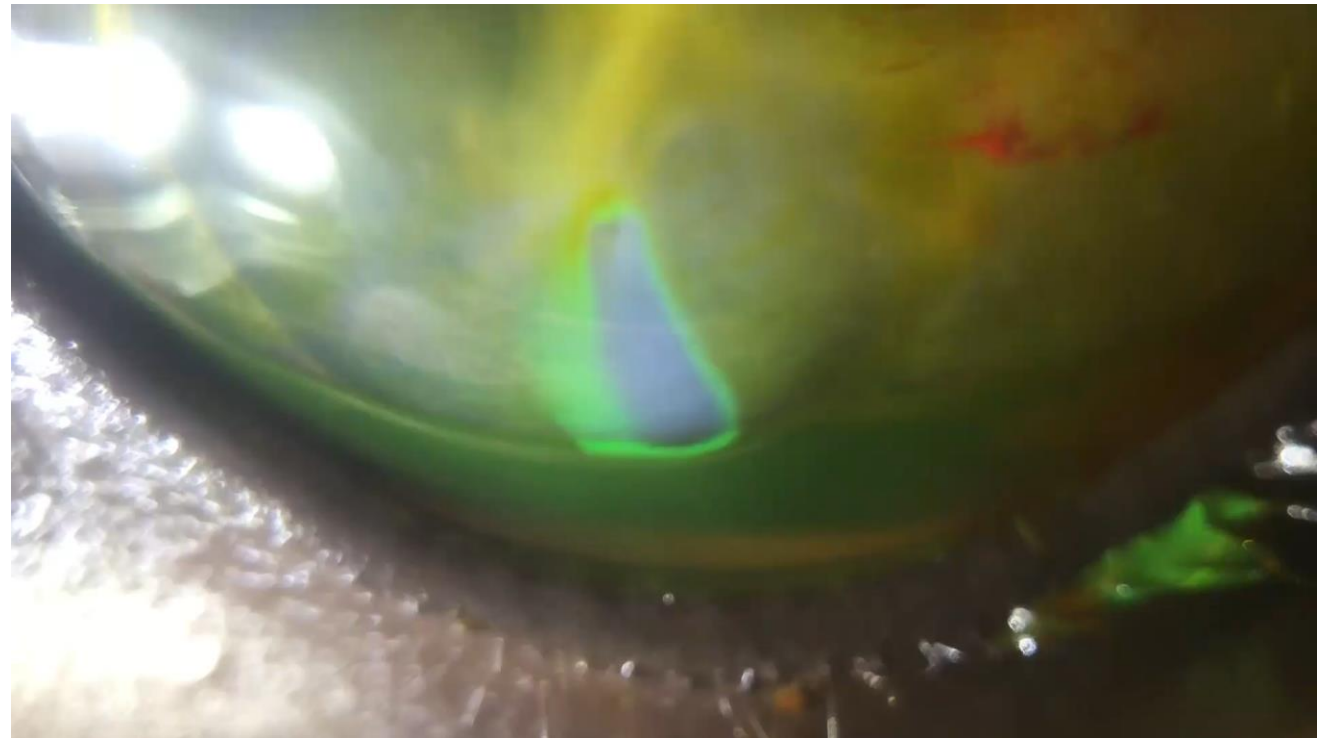
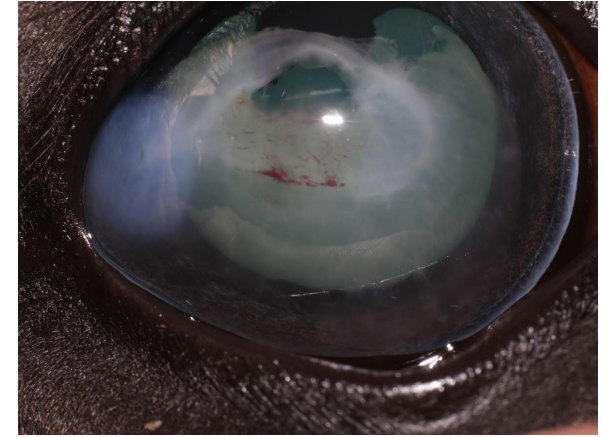
Corneal grafting techniques

- Allografts
 - Conjunctiva
 - Outside the visual axis
 - >40% stroma left
 - Avoid rotational pedicle graft
 - When fungus suspected
 - Corneal sliding grafts
 - Perforations
 - >40% stromal loss
 - Repairing lesions in visual axis
 - Corneal lamellar grafts
 - Penetrating keratoplasty
- Xenografts
 - (cornea)
 - Amnion
 - “Collagen scaffolds”



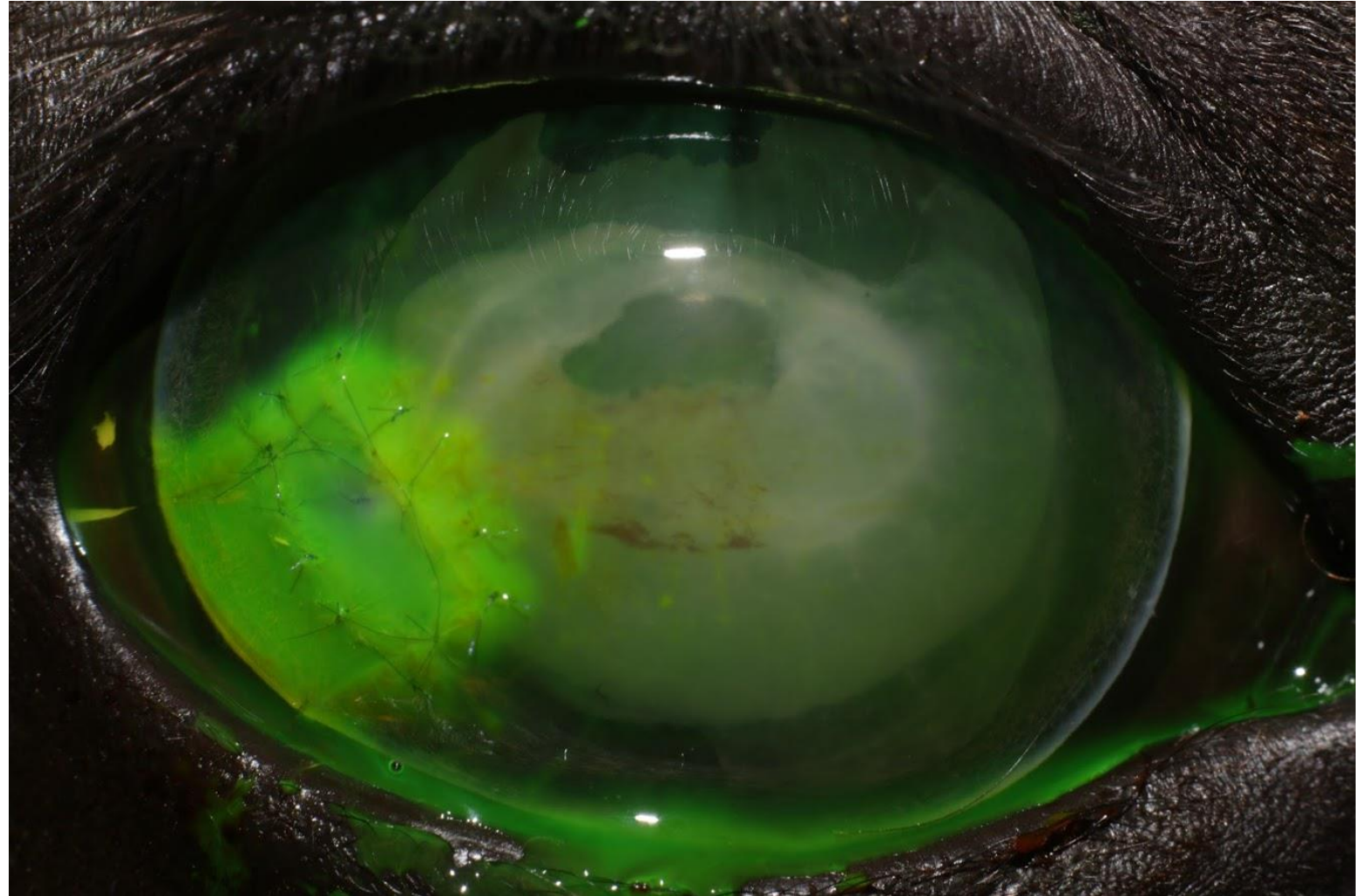
Corneal grafting techniques

- Allografts
 - Conjunctiva
 - Outside the visual axis
 - >40% stroma left
 - Avoid rotational pedicle graft
 - When fungus suspected
 - Corneal sliding grafts
 - Perforations
 - >40% stromal loss
 - Repairing lesions in visual axis
 - Corneal lamellar grafts
 - Penetrating keratoplasty
- Xenografts
 - (cornea)
 - Amnion
 - “Collagen scaffolds”



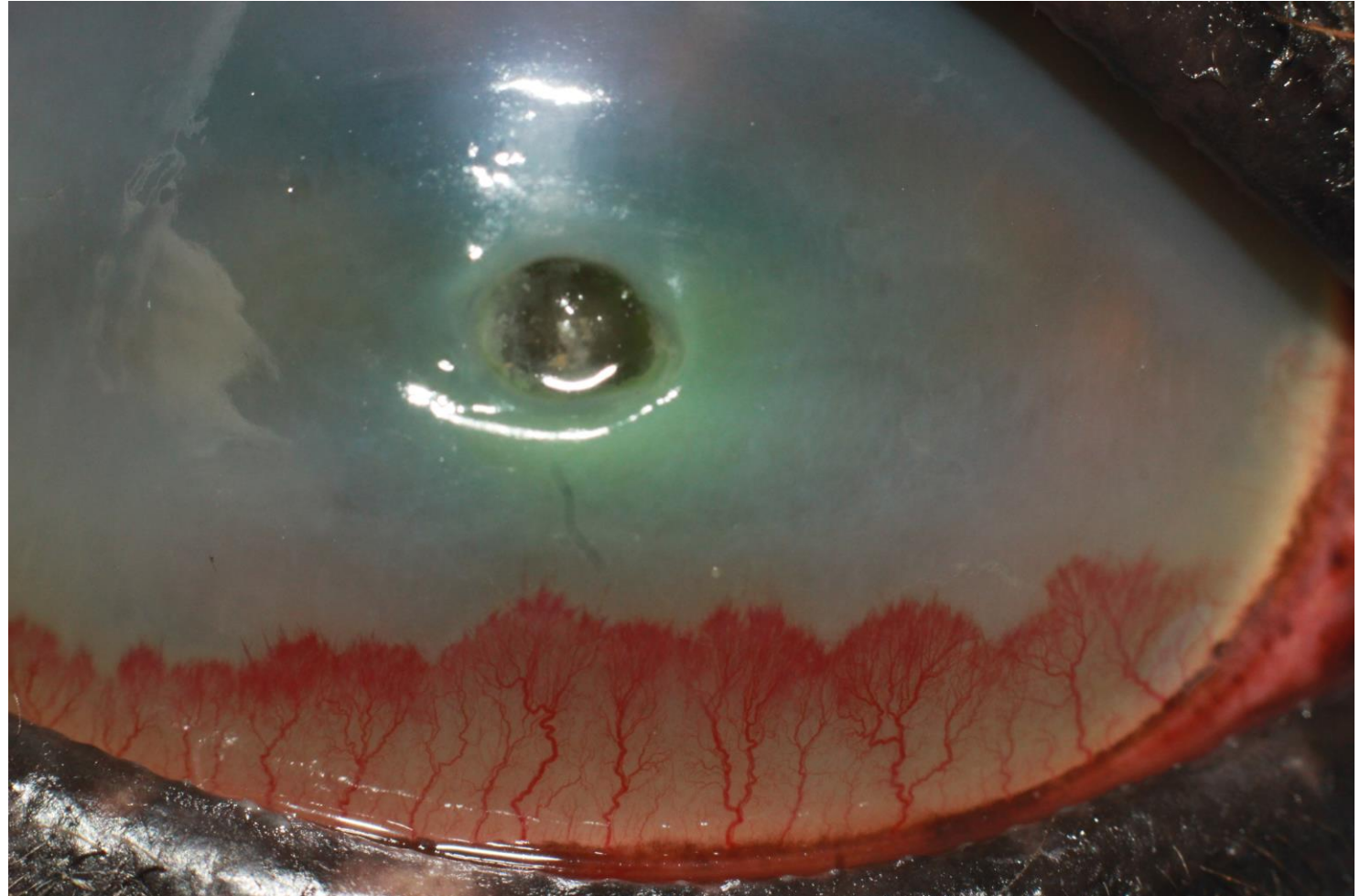Corneal grafting techniques

- Allografts
 - Conjunctiva
 - Outside the visual axis
 - >40% stroma left
 - Avoid rotational pedicle graft
 - When fungus suspected
 - Corneal sliding grafts
 - Perforations
 - >40% stromal loss
 - Repairing lesions in visual axis
 - Corneal lamellar grafts
 - Penetrating keratoplasty
- Xenografts
 - (cornea)
 - Amnion
 - “Collagen scaffolds”



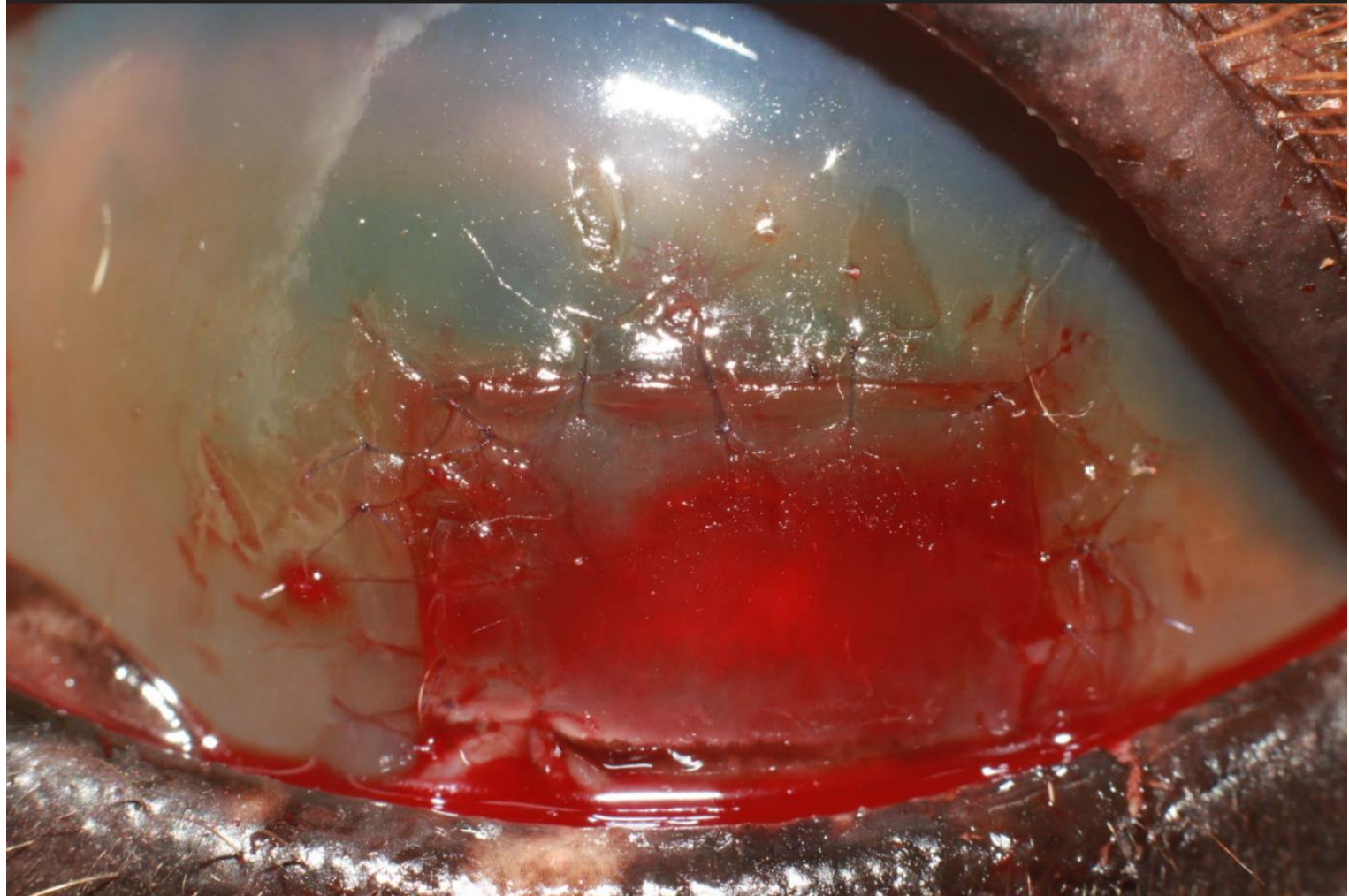
Corneal grafting techniques

- Allografts
 - Conjunctiva
 - Outside the visual axis
 - >40% stroma left
 - Avoid rotational pedicle graft
 - When fungus suspected
 - Corneal sliding grafts
 - Perforations
 - >40% stromal loss
 - Repairing lesions in visual axis
 - Corneal lamellar grafts
 - Penetrating keratoplasty
- Xenografts
 - (cornea)
 - Amnion
 - “Collagen scaffolds”



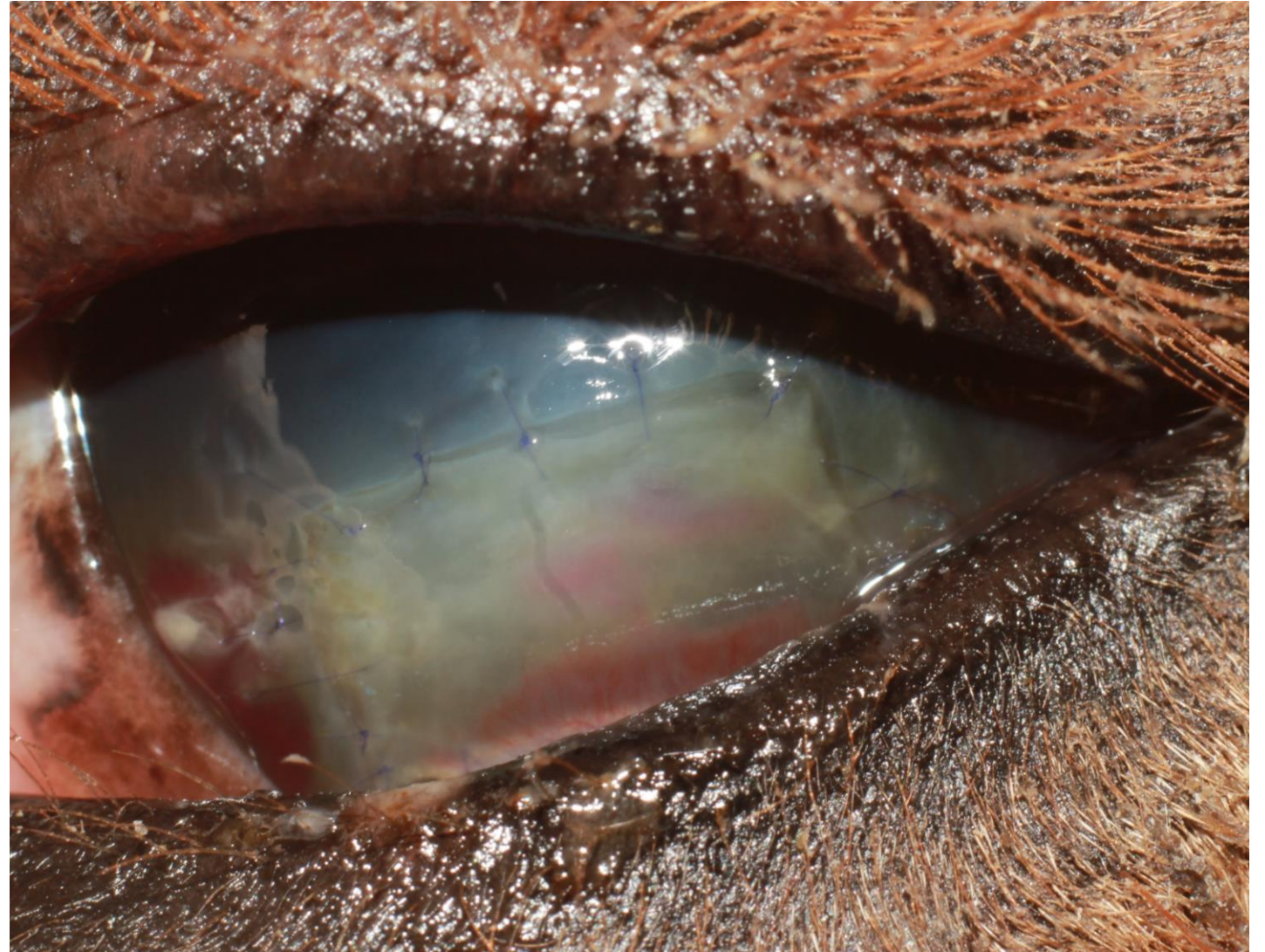Corneal grafting techniques

- Allografts
 - Conjunctiva
 - Outside the visual axis
 - >40% stroma left
 - Avoid rotational pedicle graft
 - When fungus suspected
 - Corneal sliding grafts
 - Perforations
 - >40% stromal loss
 - Repairing lesions in visual axis
 - Corneal lamellar grafts
 - Penetrating keratoplasty
- Xenografts
 - (cornea)
 - Amnion
 - “Collagen scaffolds”



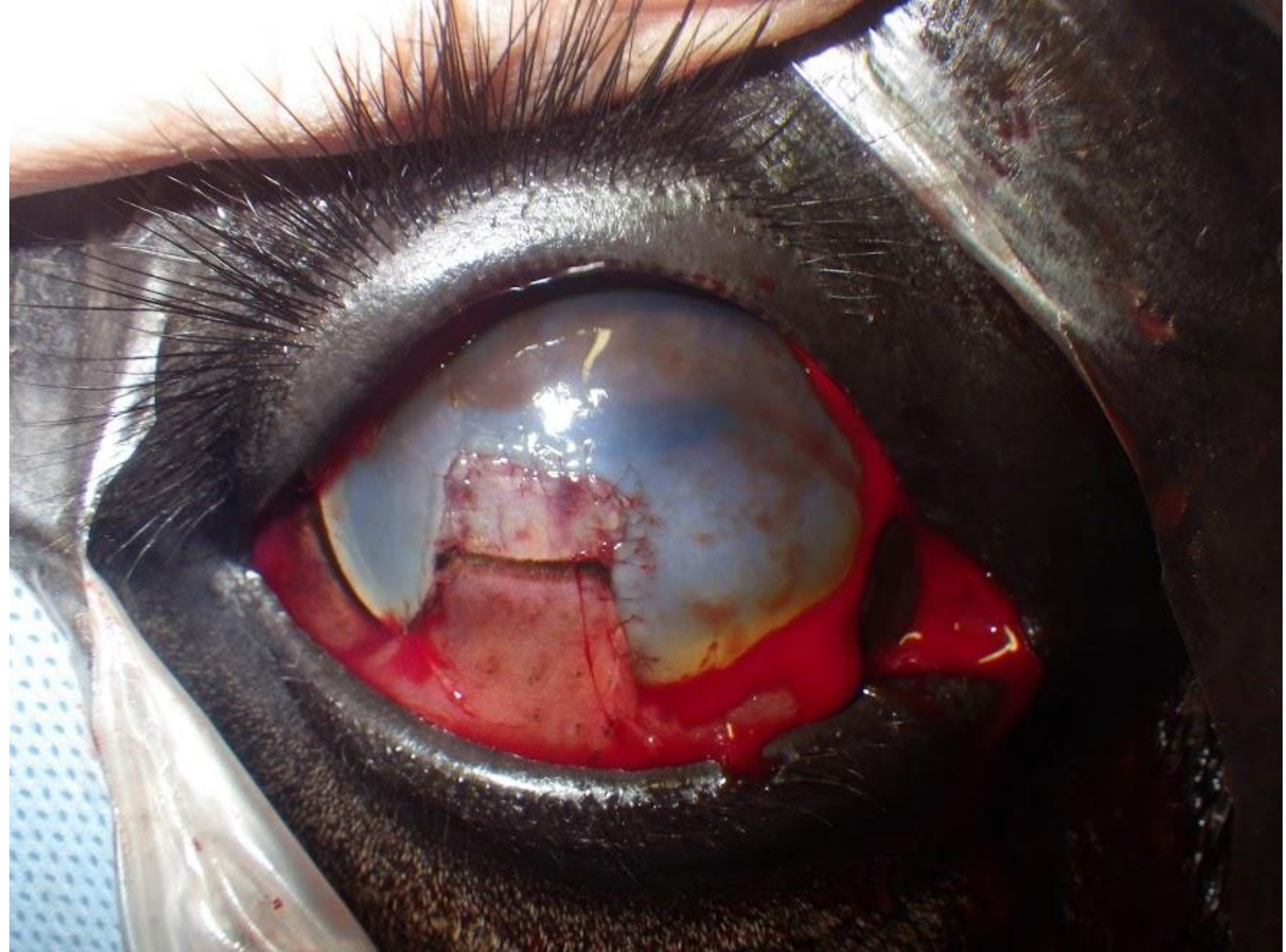Corneal grafting techniques

- Allografts
 - Conjunctiva
 - Outside the visual axis
 - >40% stroma left
 - Avoid rotational pedicle graft
 - When fungus suspected
 - Corneal sliding grafts
 - Perforations
 - >40% stromal loss
 - Repairing lesions in visual axis
 - Corneal lamellar grafts
 - Penetrating keratoplasty
- Xenografts
 - (cornea)
 - Amnion
 - “Collagen scaffolds”



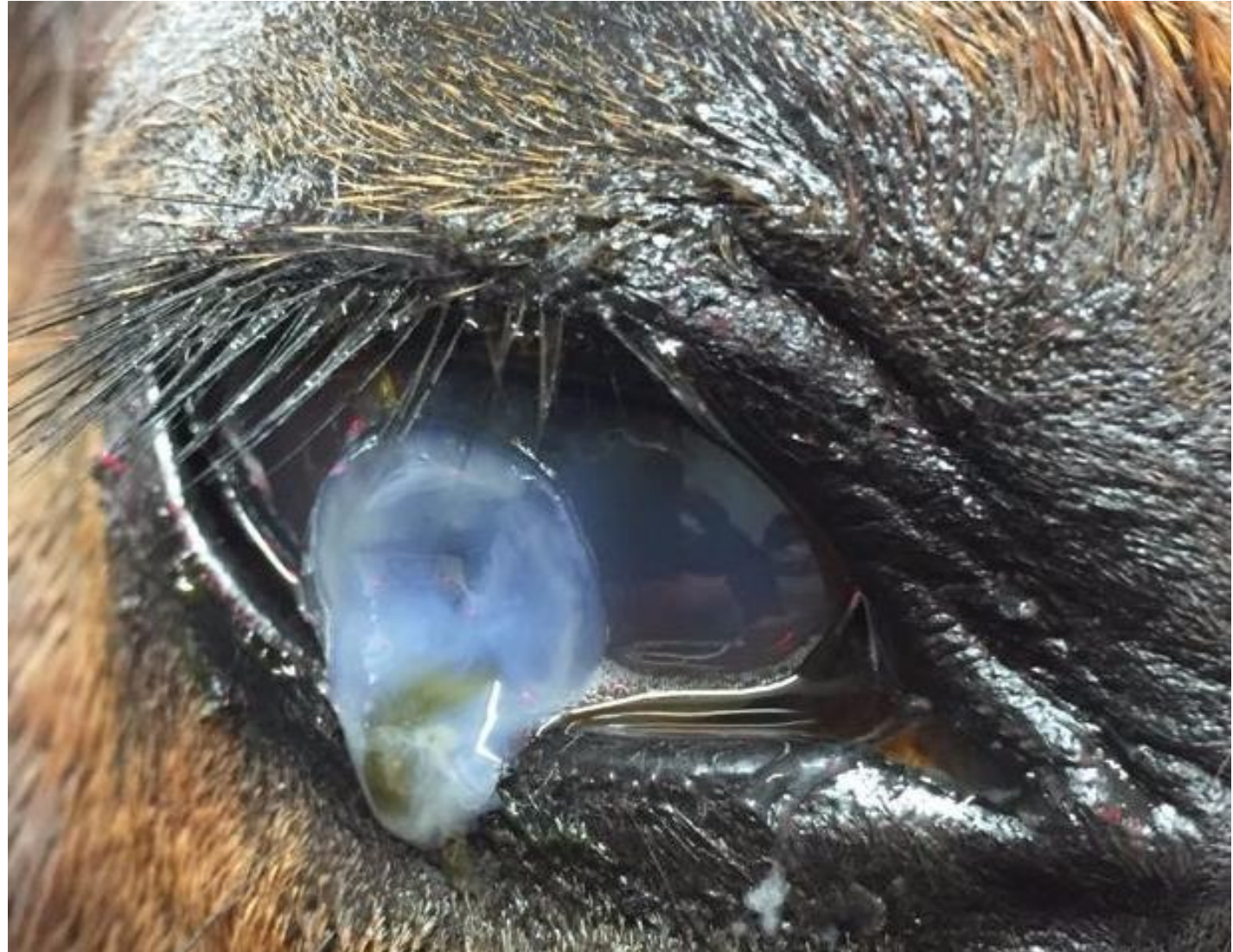Corneal grafting techniques

- Allografts
 - Conjunctiva
 - Outside the visual axis
 - >40% stroma left
 - Avoid rotational pedicle graft
 - When fungus suspected
 - Corneal sliding grafts
 - Perforations
 - >40% stromal loss
 - Repairing lesions in visual axis
 - Corneal lamellar grafts
 - Penetrating keratoplasty
- Xenografts
 - (cornea)
 - Amnion
 - “Collagen scaffolds”

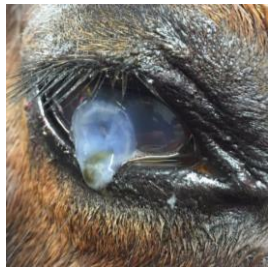

Corneal grafting techniques

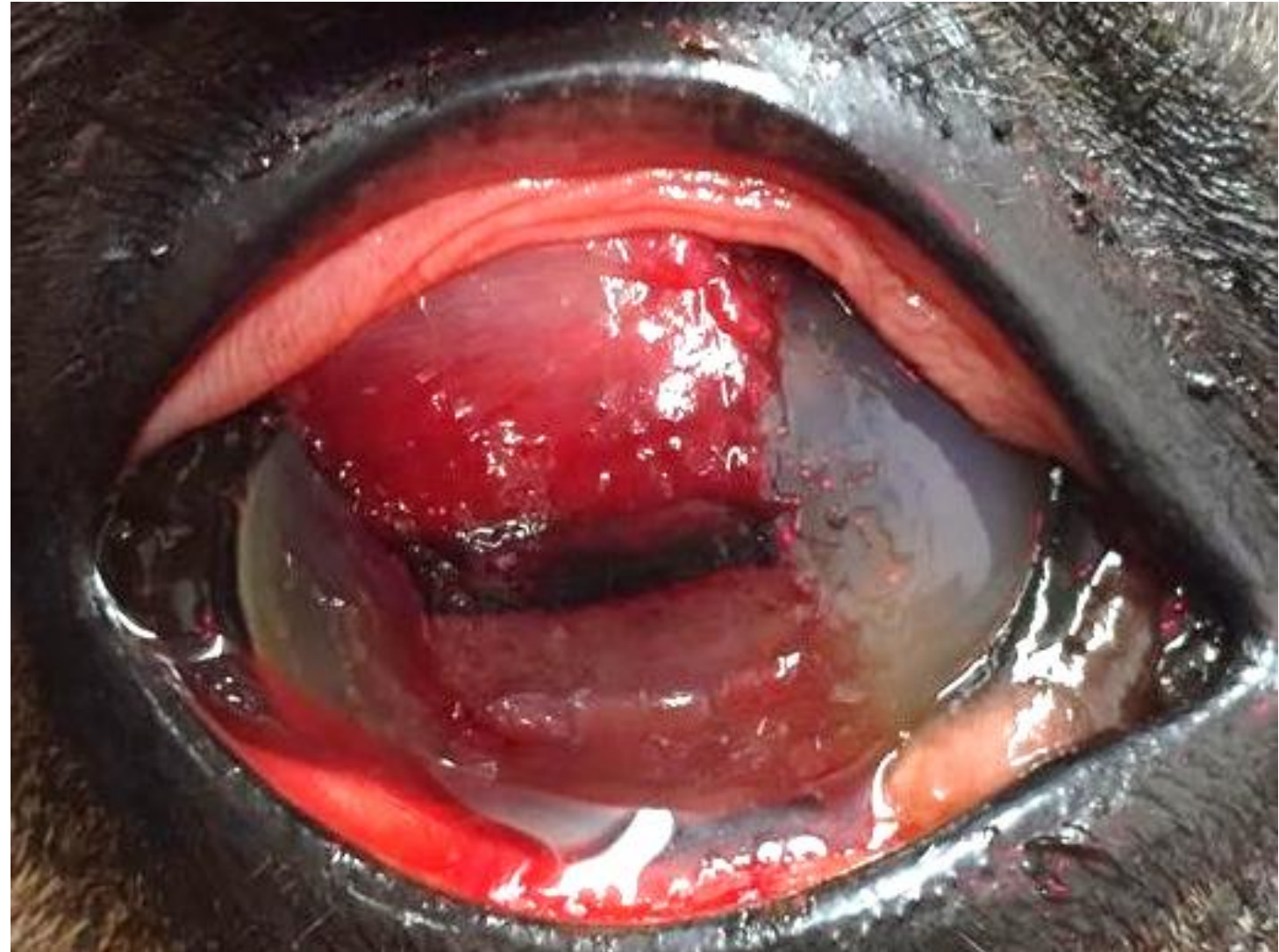- Allografts
 - Conjunctiva
 - Outside the visual axis
 - >40% stroma left
 - Avoid rotational pedicle graft
 - When fungus suspected
 - Corneal sliding grafts
 - Perforations
 - >40% stromal loss
 - Repairing lesions in visual axis
 - Corneal lamellar grafts
 - Penetrating keratoplasty
- Xenografts
 - (cornea)
 - Amnion
 - “Collagen scaffolds”



Corneal grafting techniques

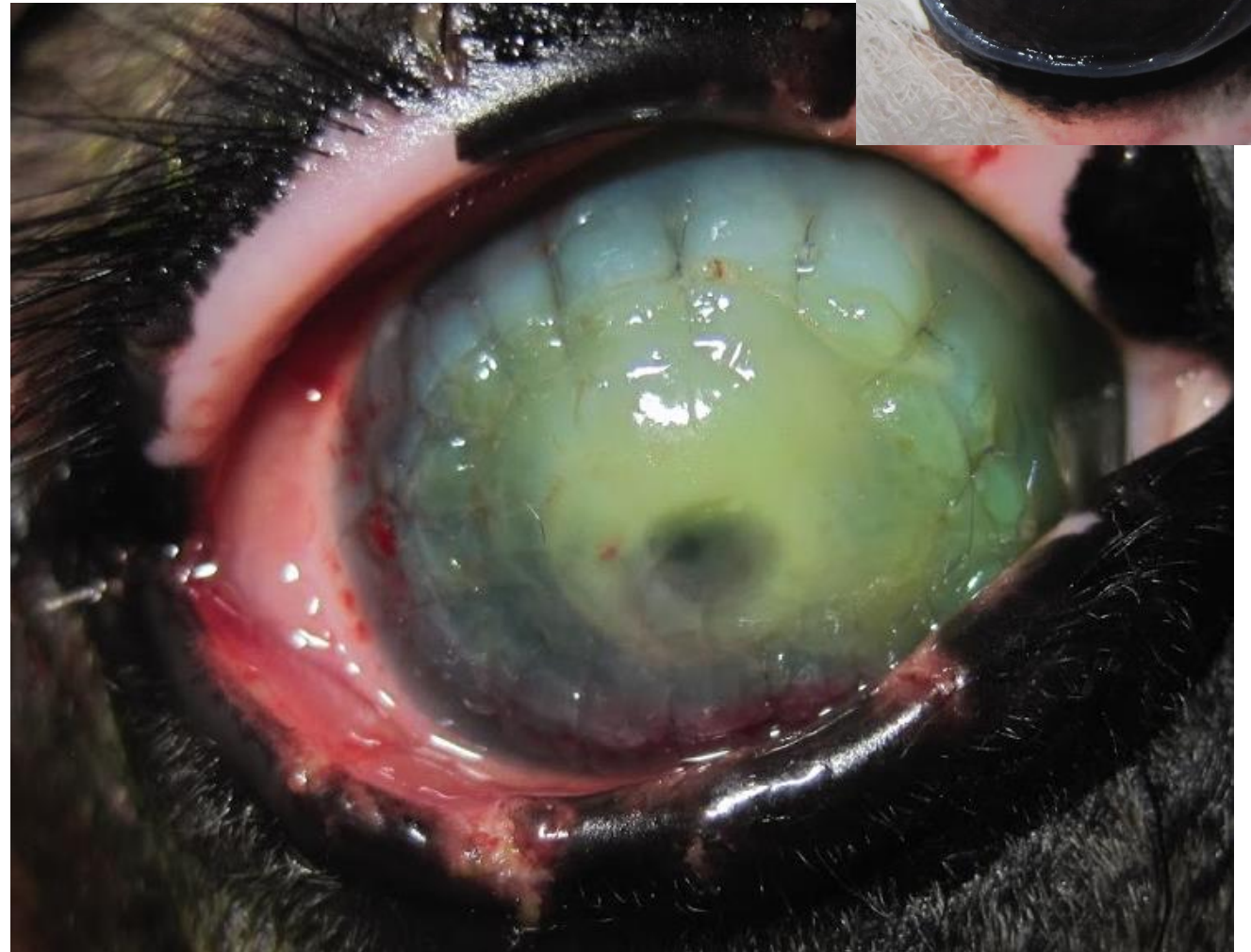

- Allografts
 - Conjunctiva
 - Outside the visual axis
 - >40% stroma left
 - Avoid rotational pedicle graft
 - When fungus suspected
 - Corneal sliding grafts
 - Perforations
 - >40% stromal loss
 - Repairing lesions in visual axis
 - Corneal lamellar grafts
 - Penetrating keratoplasty
- Xenografts
 - (cornea)
 - Amnion
 - “Collagen scaffolds”



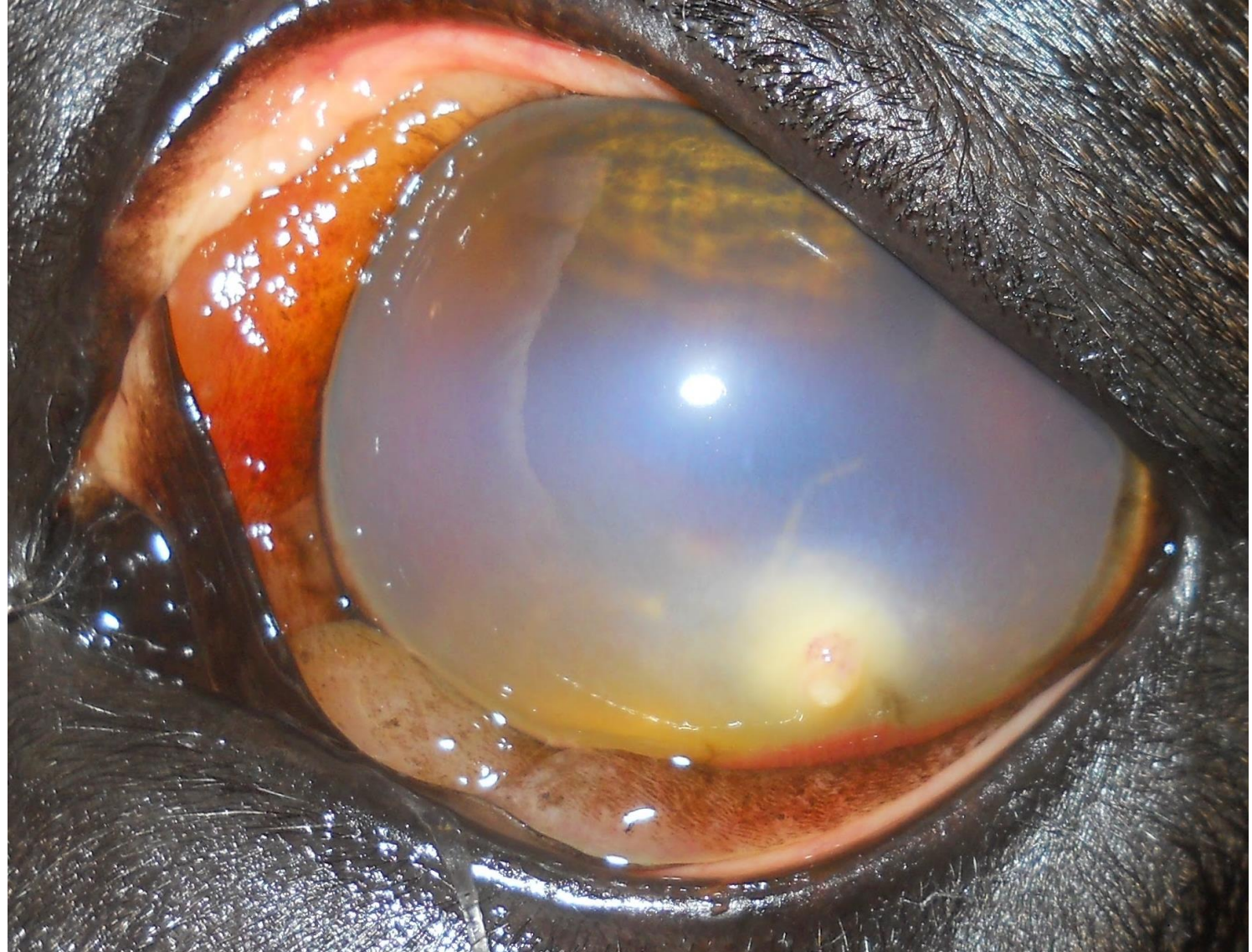Corneal grafting techniques

- Allografts
 - Conjunctiva
 - Outside the visual axis
 - >40% stroma left
 - Avoid rotational pedicle graft
 - When fungus suspected
 - Corneal sliding grafts
 - Perforations
 - >40% stromal loss
 - Repairing lesions in visual axis
 - Corneal lamellar grafts
 - Penetrating keratoplasty
- Xenografts
 - (cornea)
 - Amnion
 - “Collagen scaffolds”



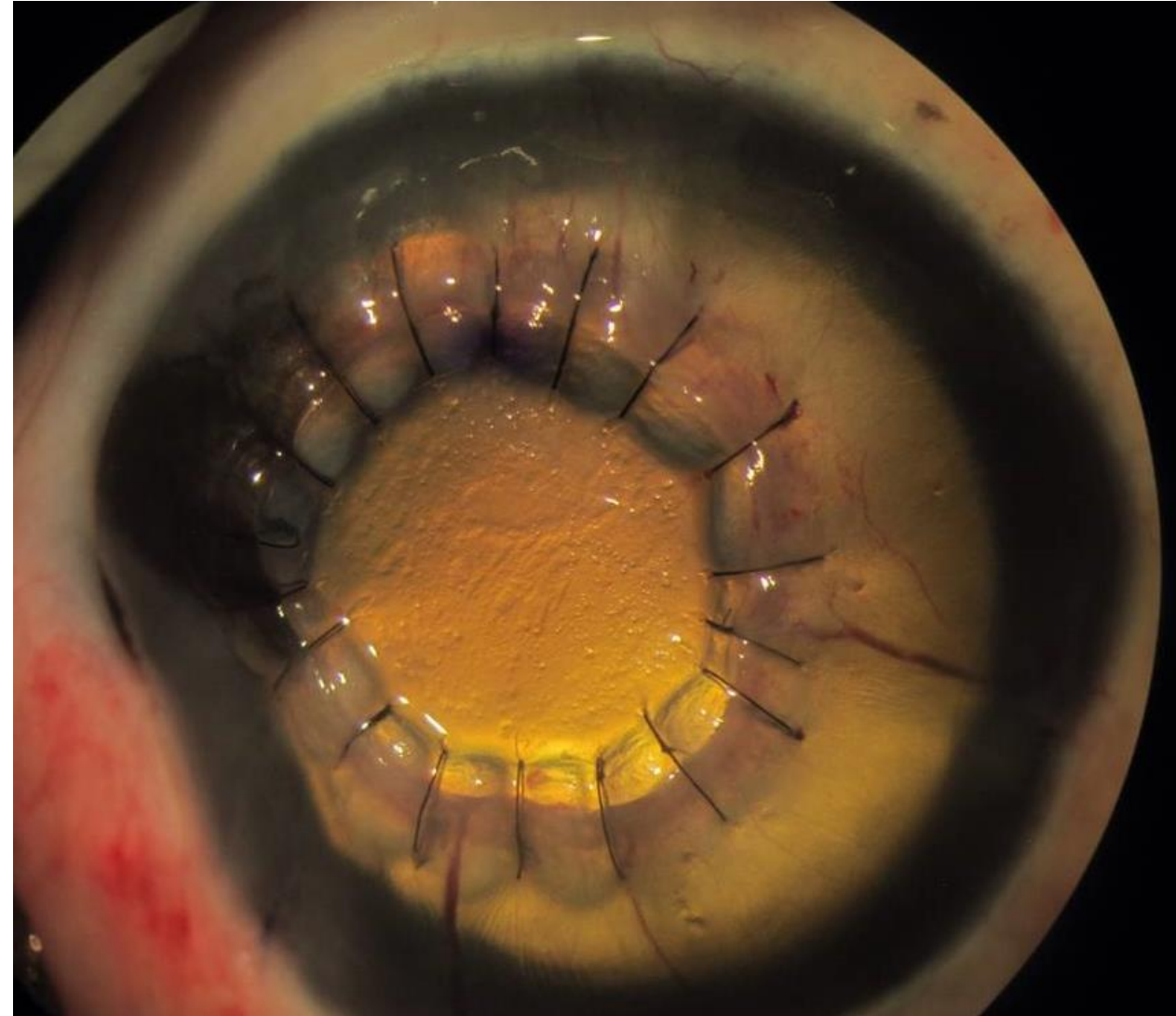
Corneal grafting techniques

- Allografts
 - Conjunctiva
 - Outside the visual axis
 - >40% stroma left
 - Avoid rotational pedicle graft
 - When fungus suspected
 - Corneal sliding grafts
 - Perforations
 - >40% stromal loss
 - Repairing lesions in visual axis
 - Corneal lamellar grafts
 - Penetrating keratoplasty
- Xenografts
 - (cornea)
 - Amnion
 - “Collagen scaffolds”



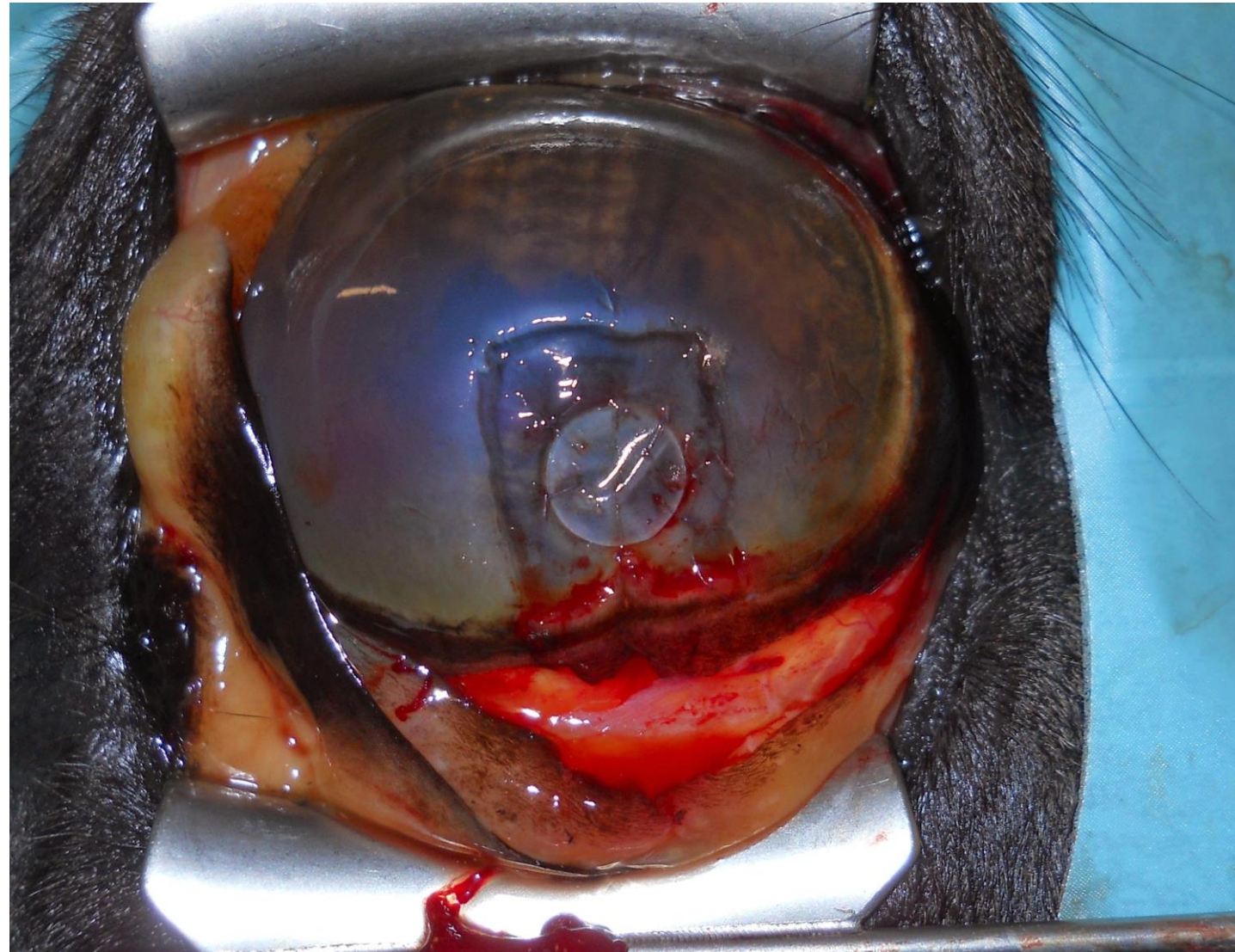
Corneal grafting techniques

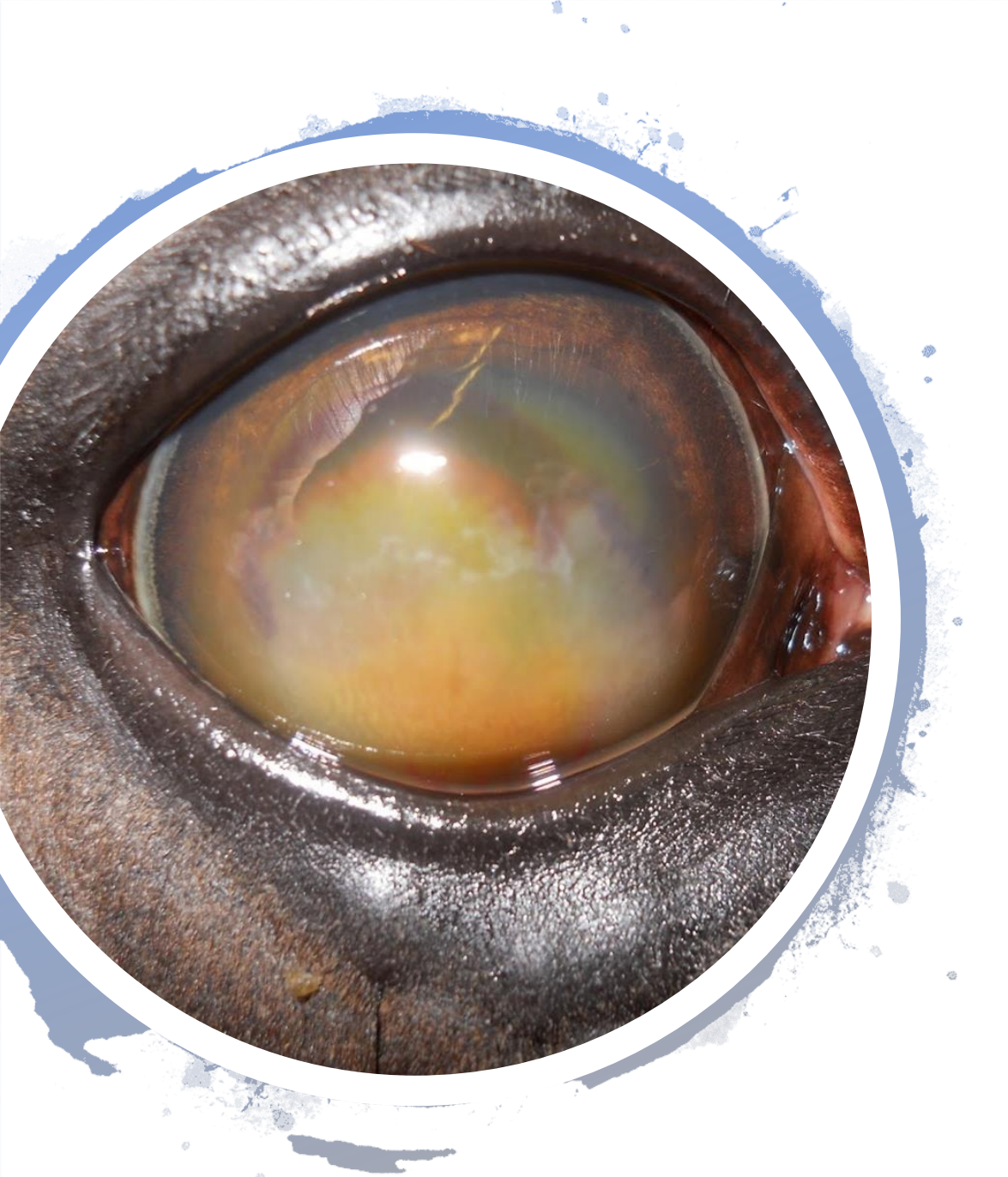
- Allografts
 - Conjunctiva
 - Outside the visual axis
 - >40% stroma left
 - Avoid rotational pedicle graft
 - When fungus suspected
 - Corneal sliding grafts
 - Perforations
 - >40% stromal loss
 - Repairing lesions in visual axis
 - Corneal lamellar grafts
 - Penetrating keratoplasty
- Xenografts
 - (cornea)
 - Amnion
 - “Collagen scaffolds”



Corneal grafting techniques

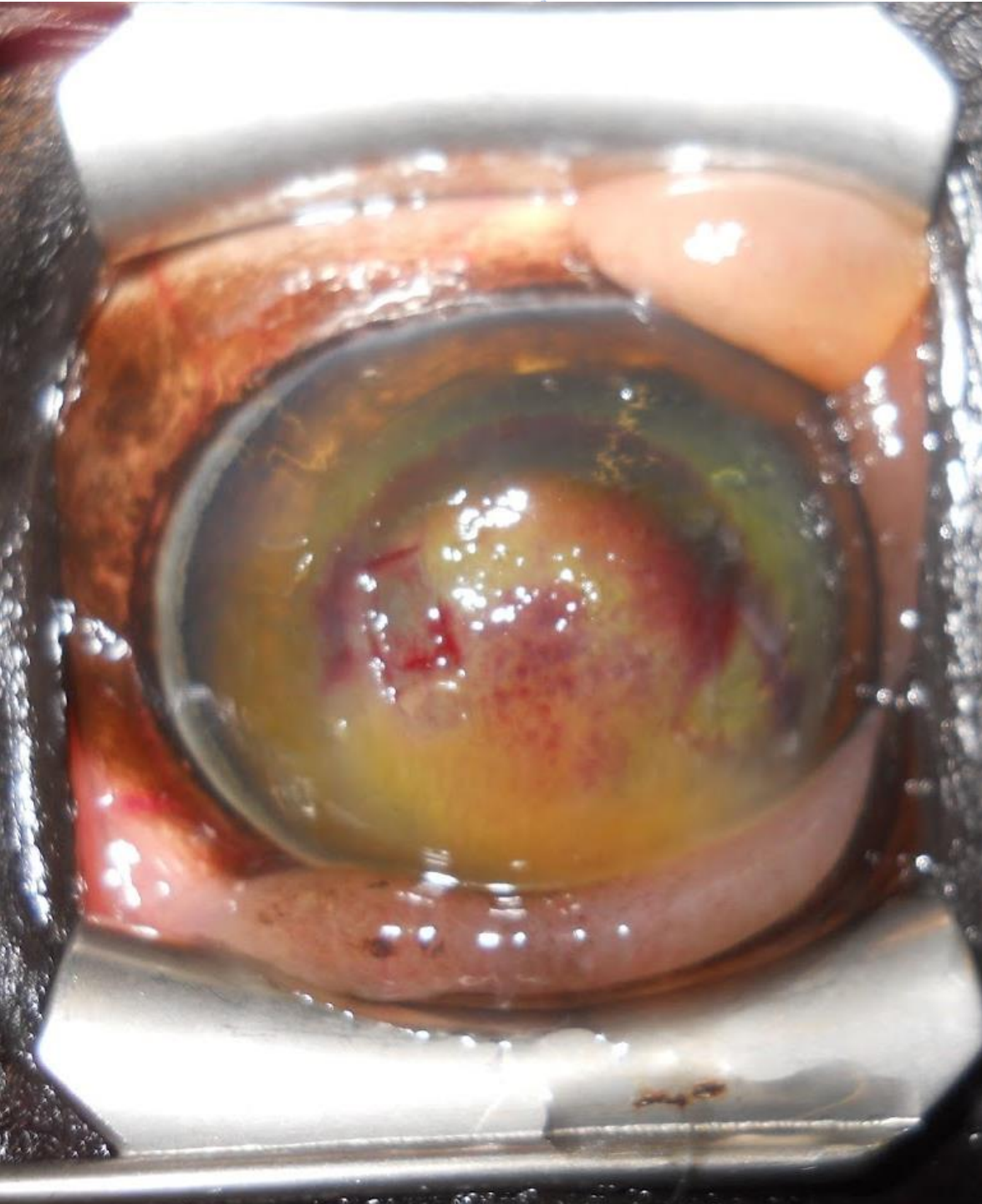
- Allografts
 - Conjunctiva
 - Outside the visual axis
 - >40% stroma left
 - Avoid rotational pedicle graft
 - When fungus suspected
 - Corneal sliding grafts
 - Perforations
 - >40% stromal loss
 - Repairing lesions in visual axis
 - Corneal lamellar grafts
 - Penetrating keratoplasty
- Xenografts
 - (cornea)
 - Amnion
 - “Collagen scaffolds”






What's new in presumed immune mediated keratitis (PIMK)

- Corneal biopsy done earlier & more aggressively and *may* have a therapeutic effect
- Cyclosporine impregnated bio-degradable silicon implants have been more recently developed for surgical implantation in the epi-scleral space which can be of help in the management of some immune mediated superficial corneal diseases.



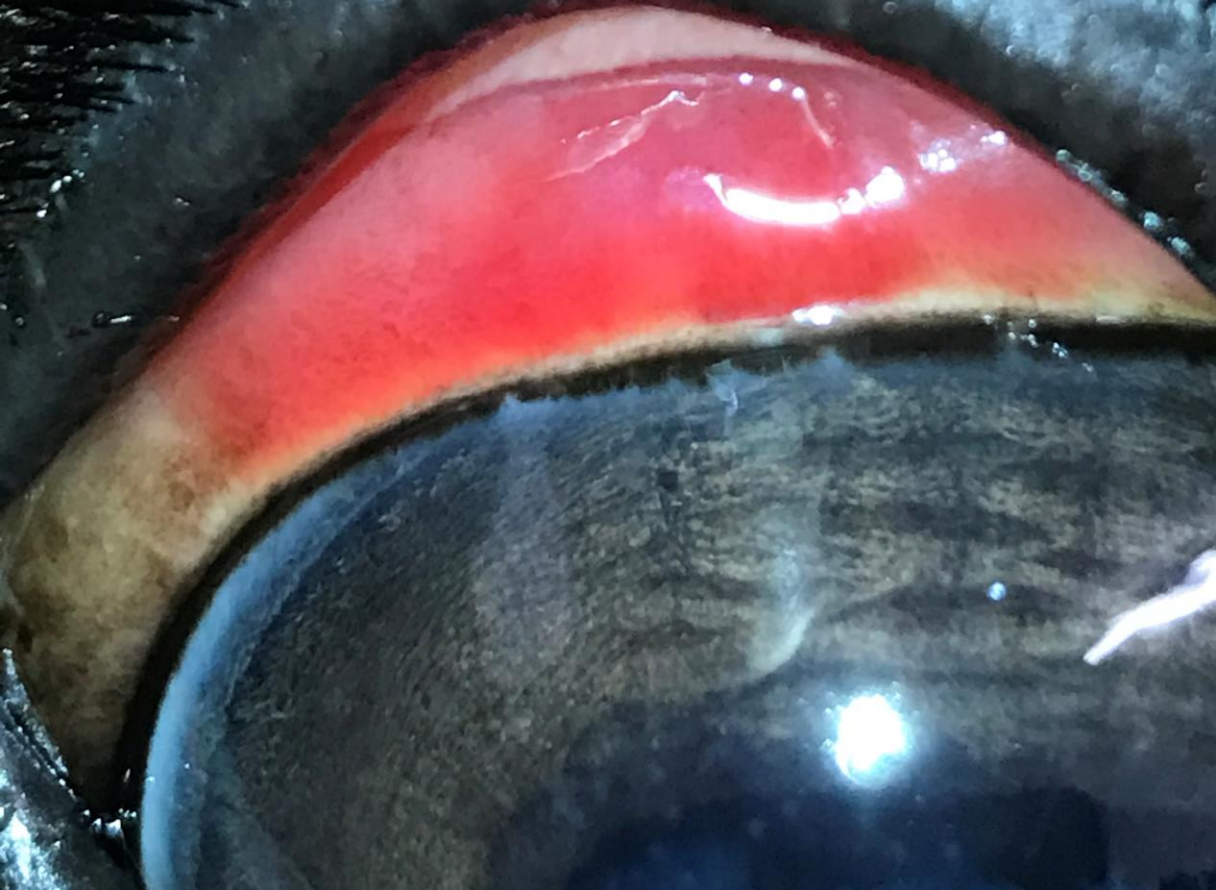
What's new in presumed immune mediated keratitis (PIMK)

- Corneal biopsy done earlier & more aggressively and **may** have a therapeutic effect
- Cyclosporine impregnated bio-degradable silicon implants have been more recently developed for surgical implantation in the epi-scleral space which can be of help in the management of some immune mediated superficial corneal diseases.




What's new in presumed immune mediated keratitis (PIMK)


- Corneal biopsy done earlier & more aggressively and *may* have a therapeutic effect
- Cyclosporine impregnated bio-degradable silicon implants have been more recently developed for surgical implantation in the epi-scleral space which can be of help in the management of some immune mediated superficial corneal diseases.



What's new in presumed immune mediated keratitis (PIMK)

- Corneal biopsy done earlier & more aggressively and *may* have a therapeutic effect
- Cyclosporine impregnated bio-degradable silicon implants have been more recently developed for surgical implantation in the epi-scleral space which can be of help in the management of some immune mediated superficial corneal diseases.

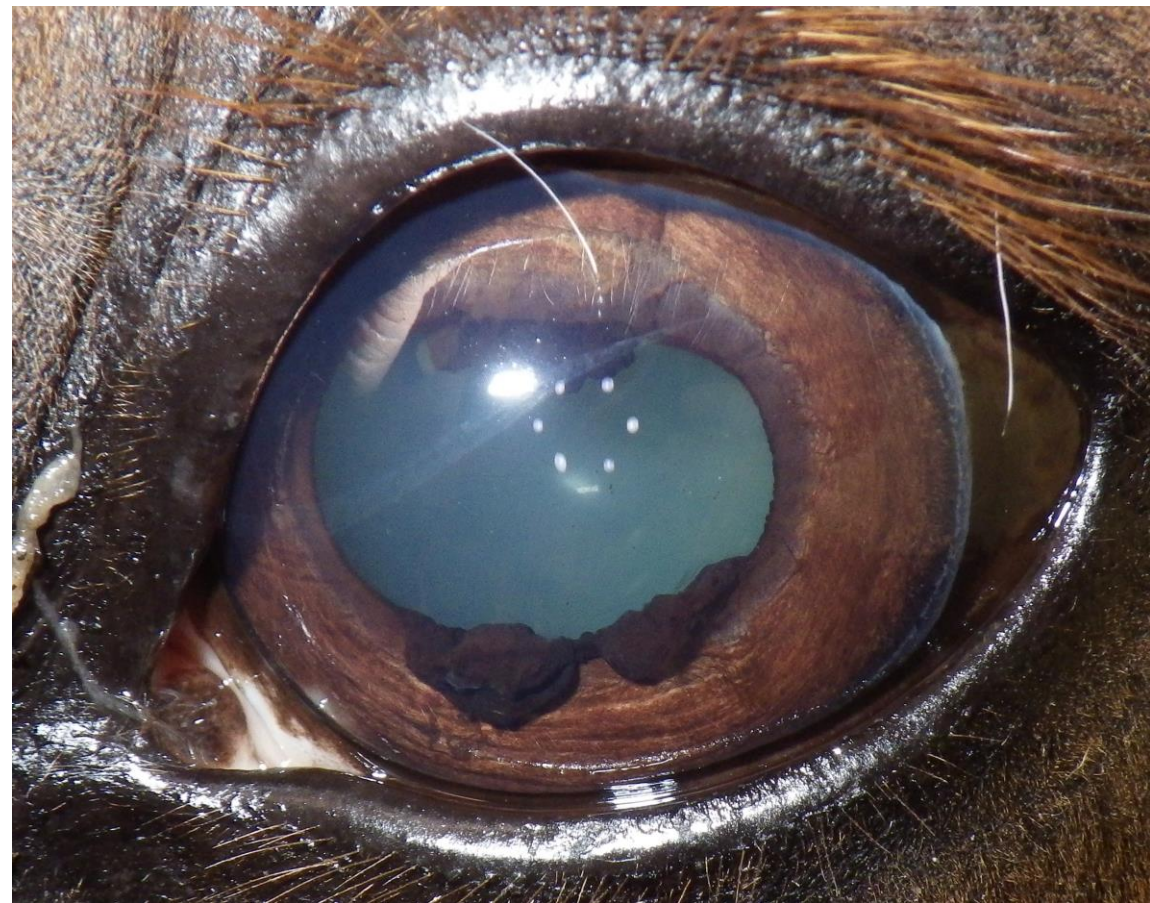
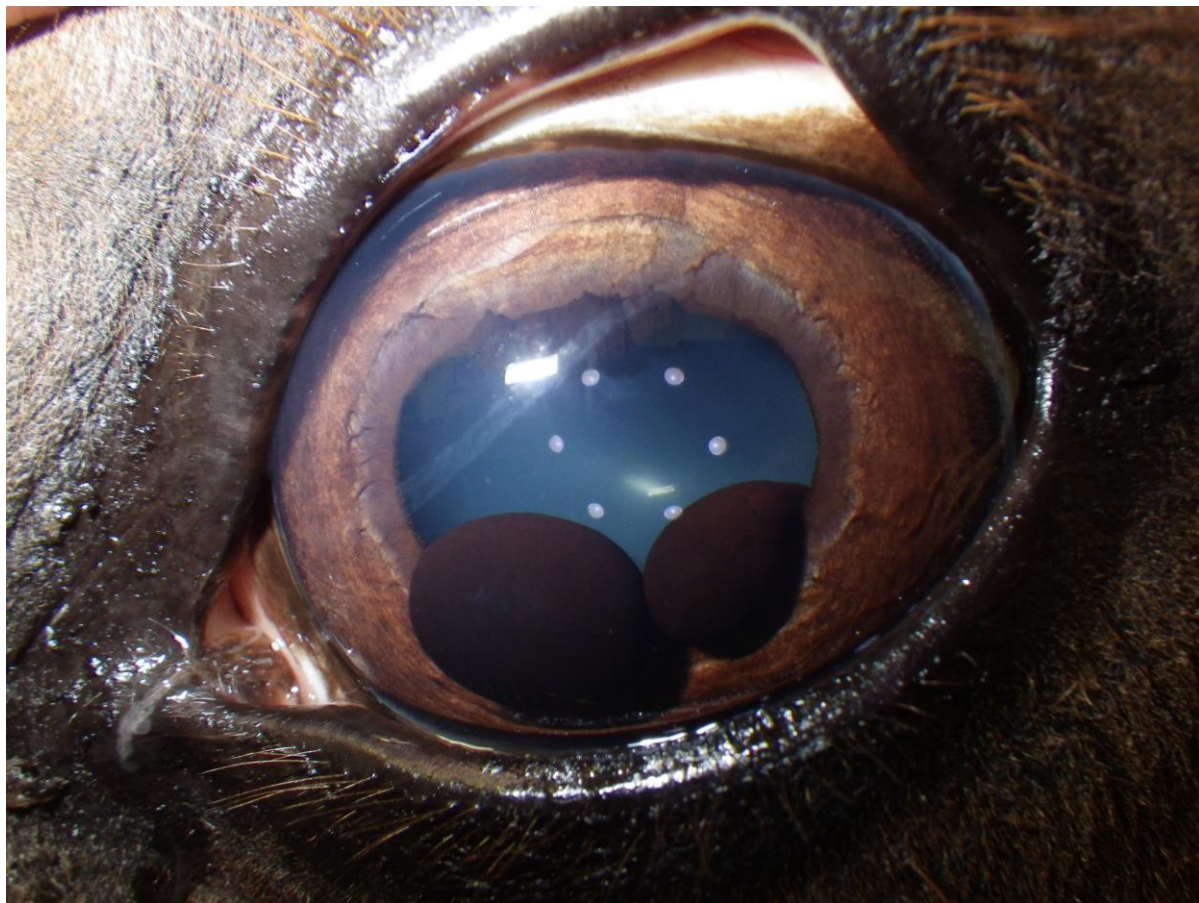



What's new in intraocular surgery?

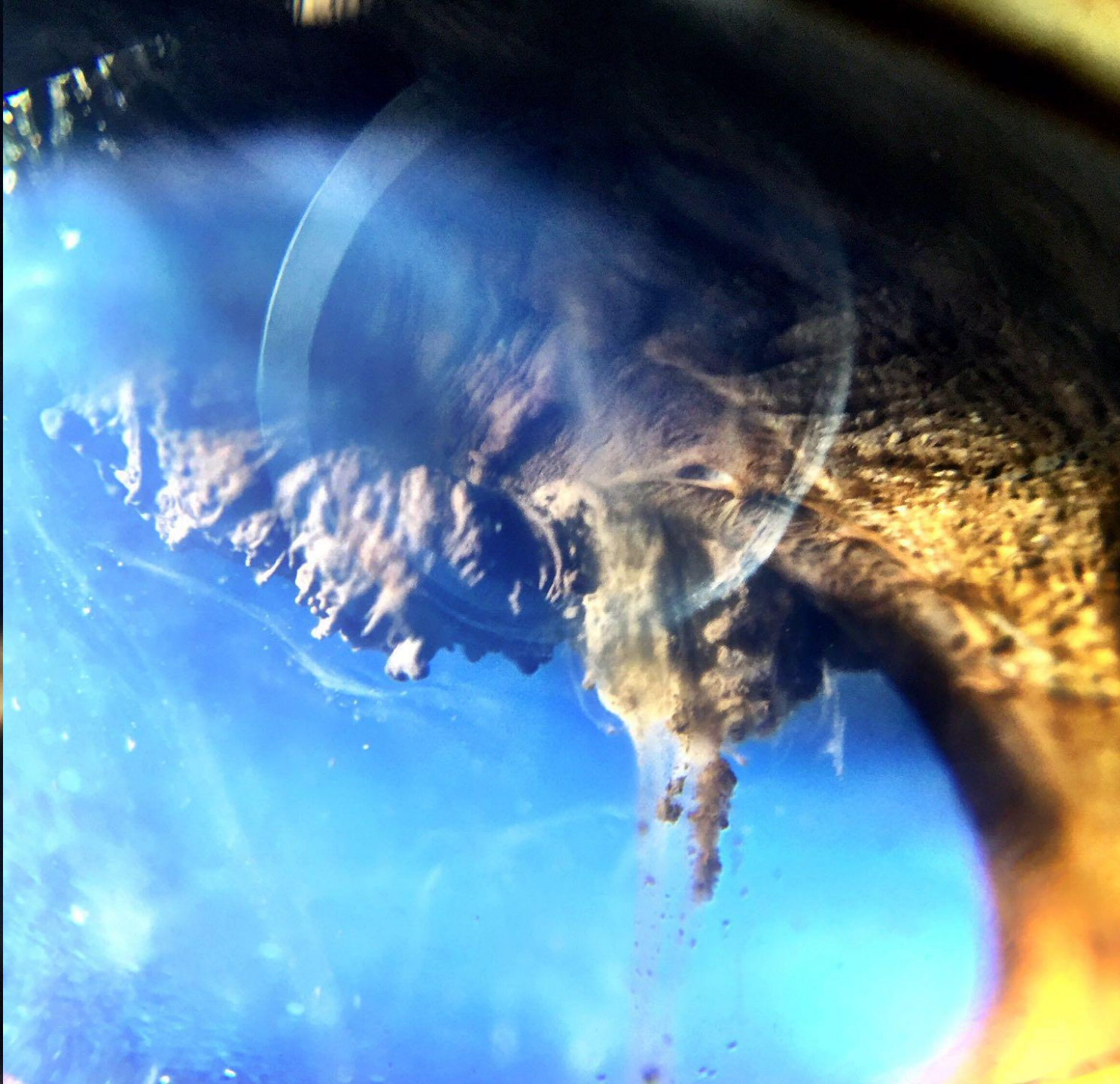
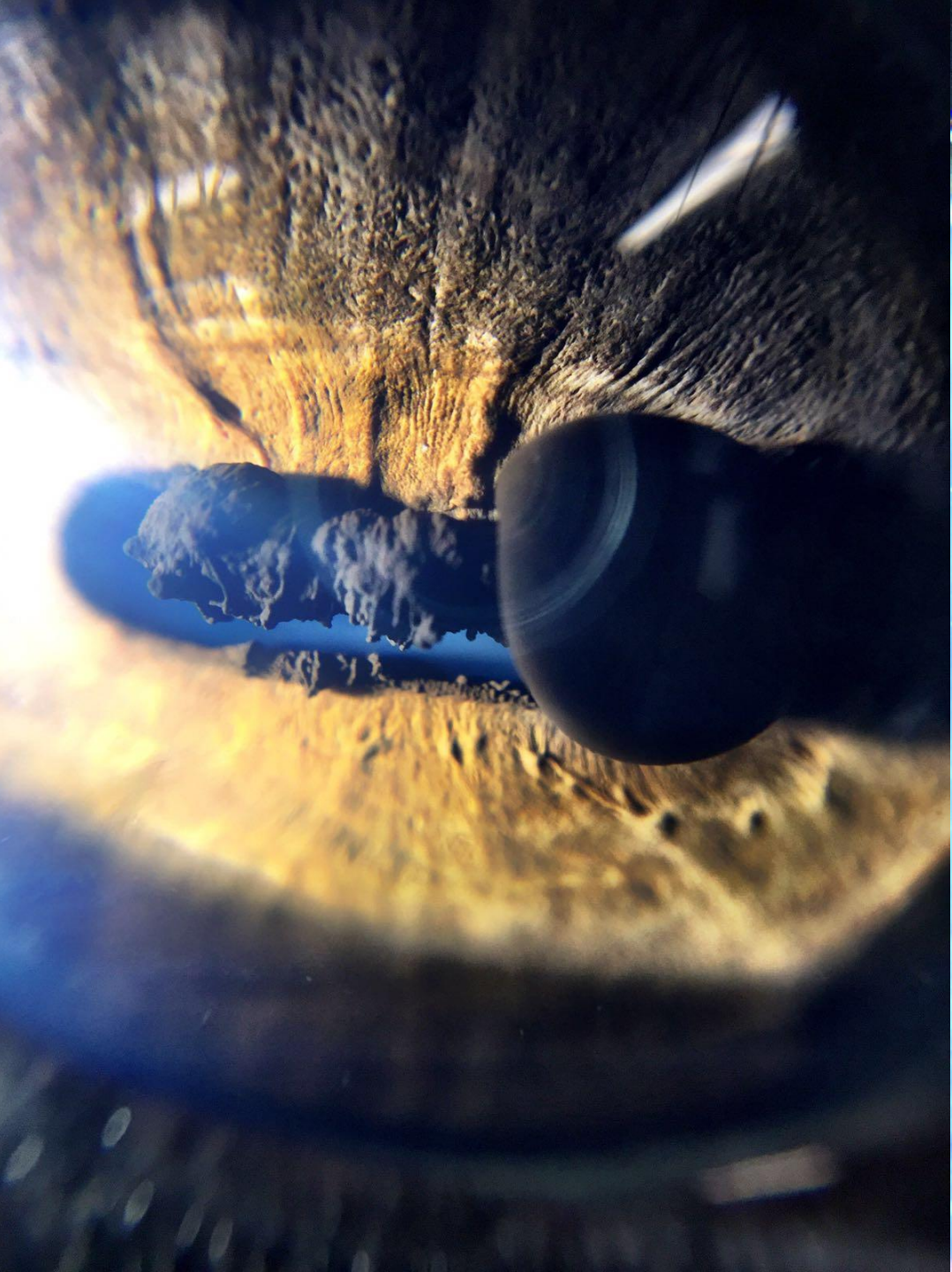
- Transcorneal photocoagulation allows ablation of pigmented intraocular lesions notably iridal melanomas and cysts.
- Cataract surgery by phacoemulsification is now offered by several sites across Europe. Advances in cataract machine technology, increasing surgeon experience, an appreciation of the importance of intensive postoperative medication and the more widespread use of prosthetic intraocular lenses is leading to increased visual rehabilitation rates in elective cataract surgery and in traumatic lens laceration cases.
- While vitrectomy is still widely used for the treatment of Leptospiral vitritis particularly in mainland Europe, intravitreal low dose gentacin (2-4mg) has been used as an alternative treatment with apparent success in UK cases with laboratory evidence of intraocular Leptospiral infection.

Iris cyst surgery


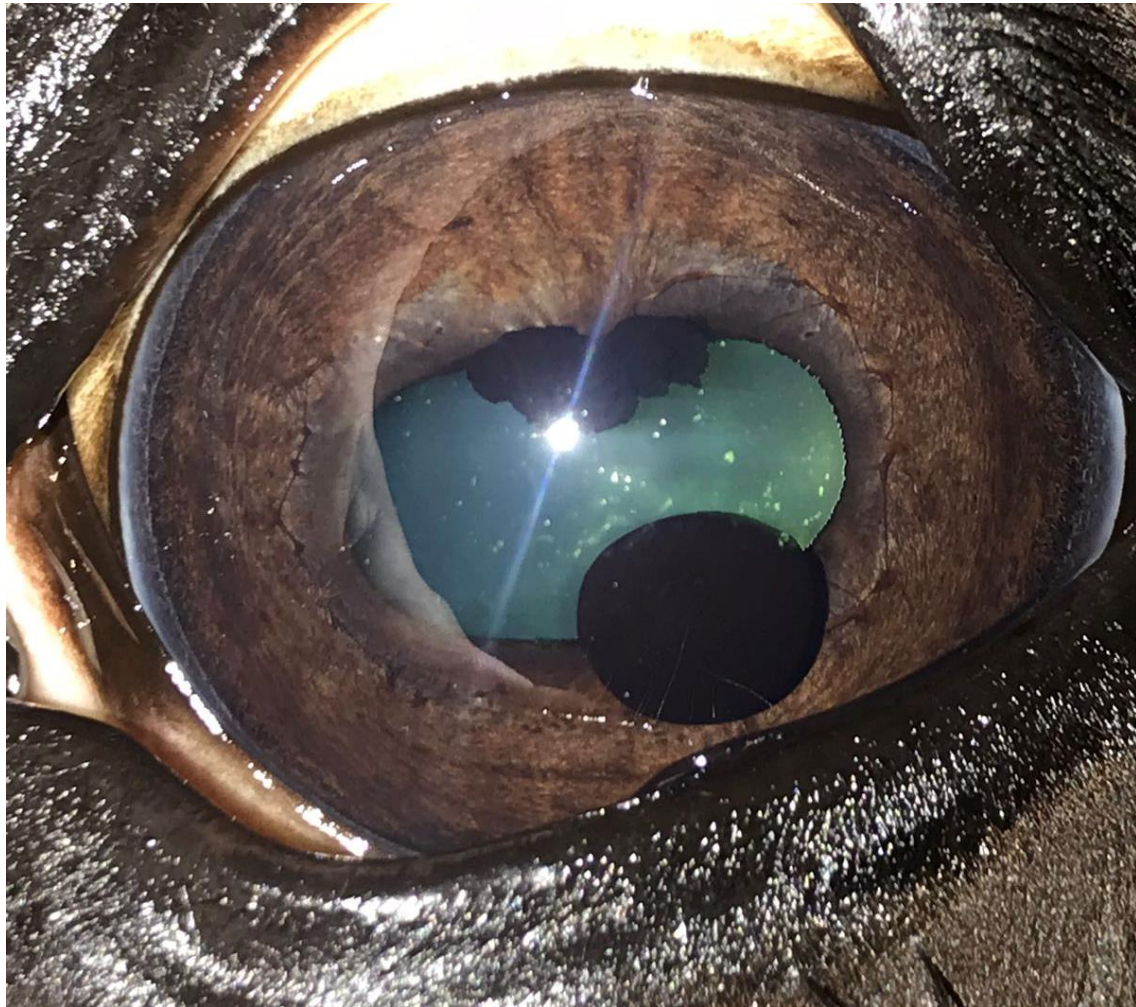


Iris cyst surgery

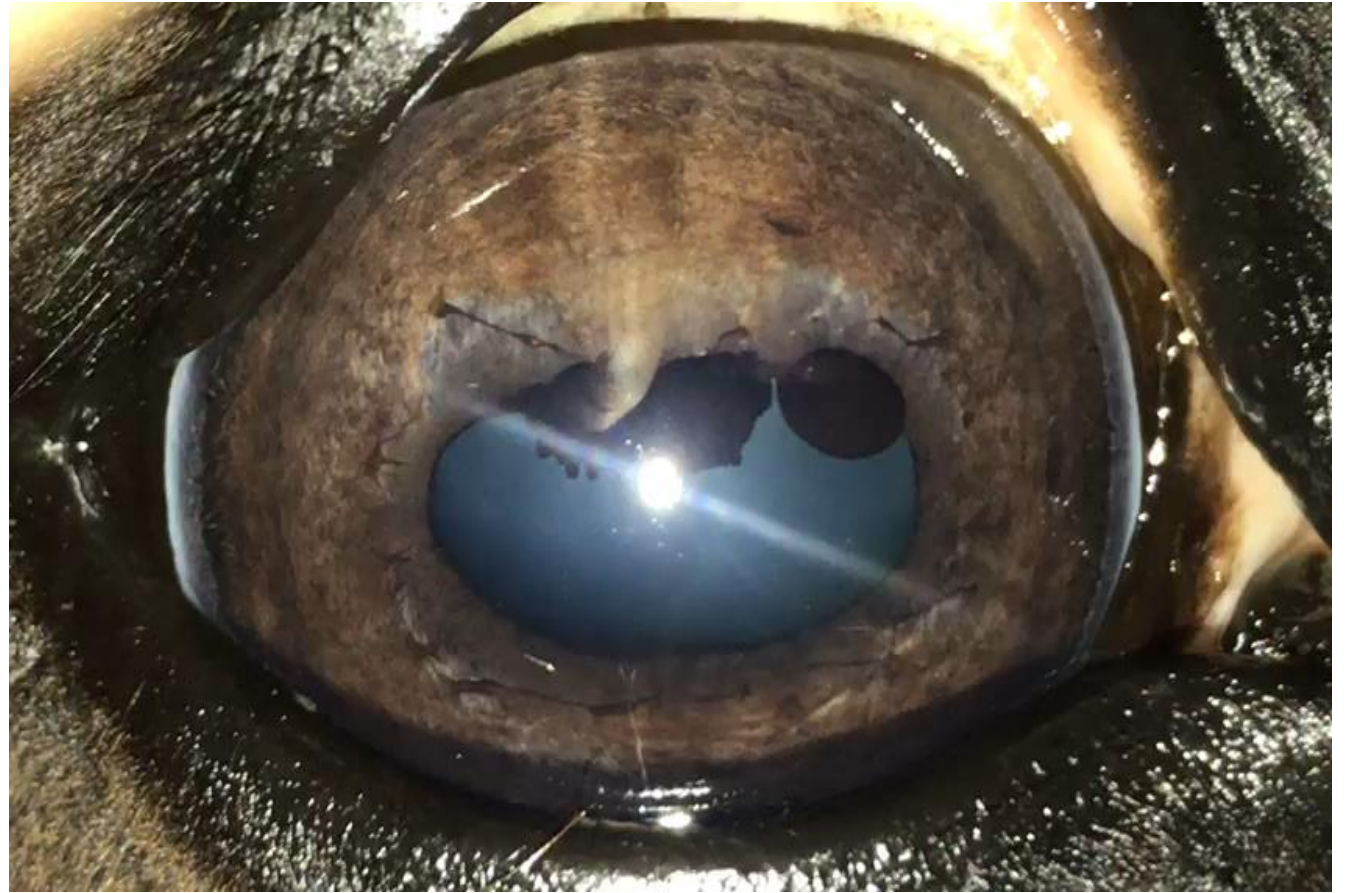
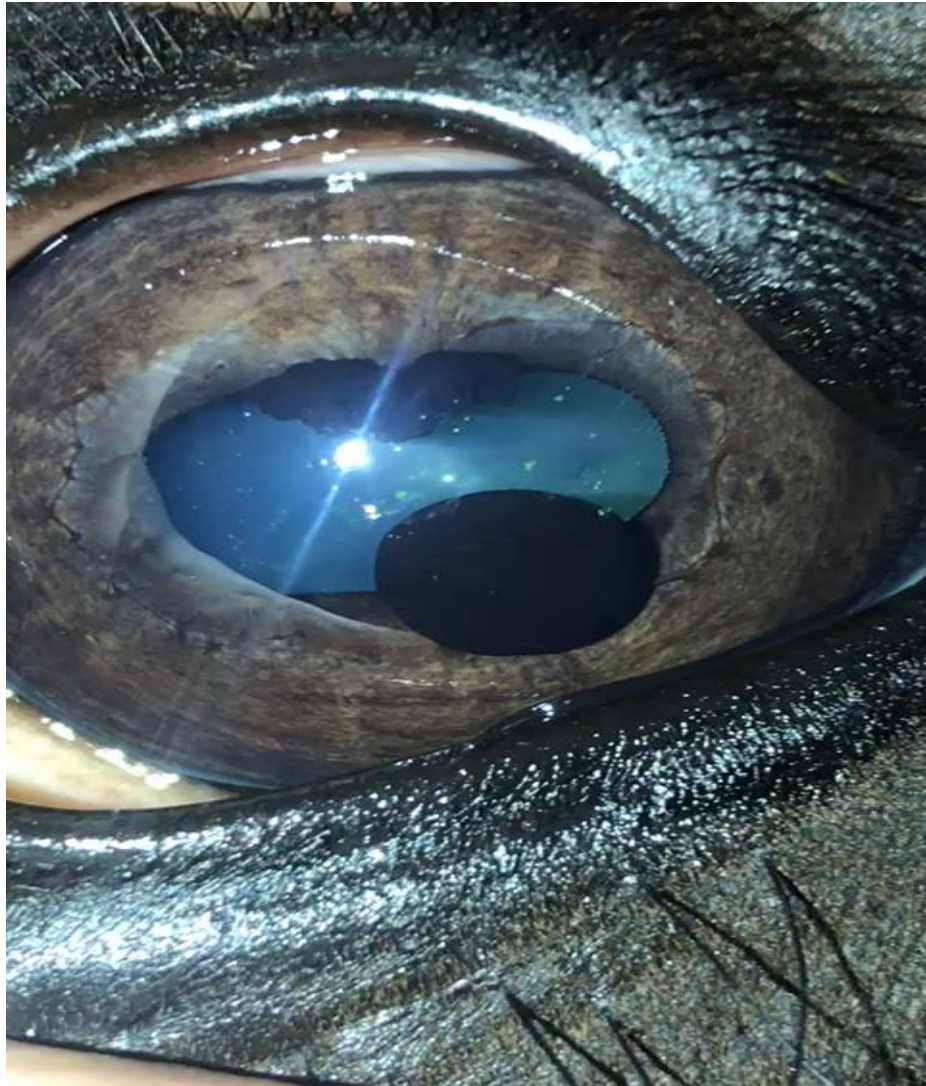


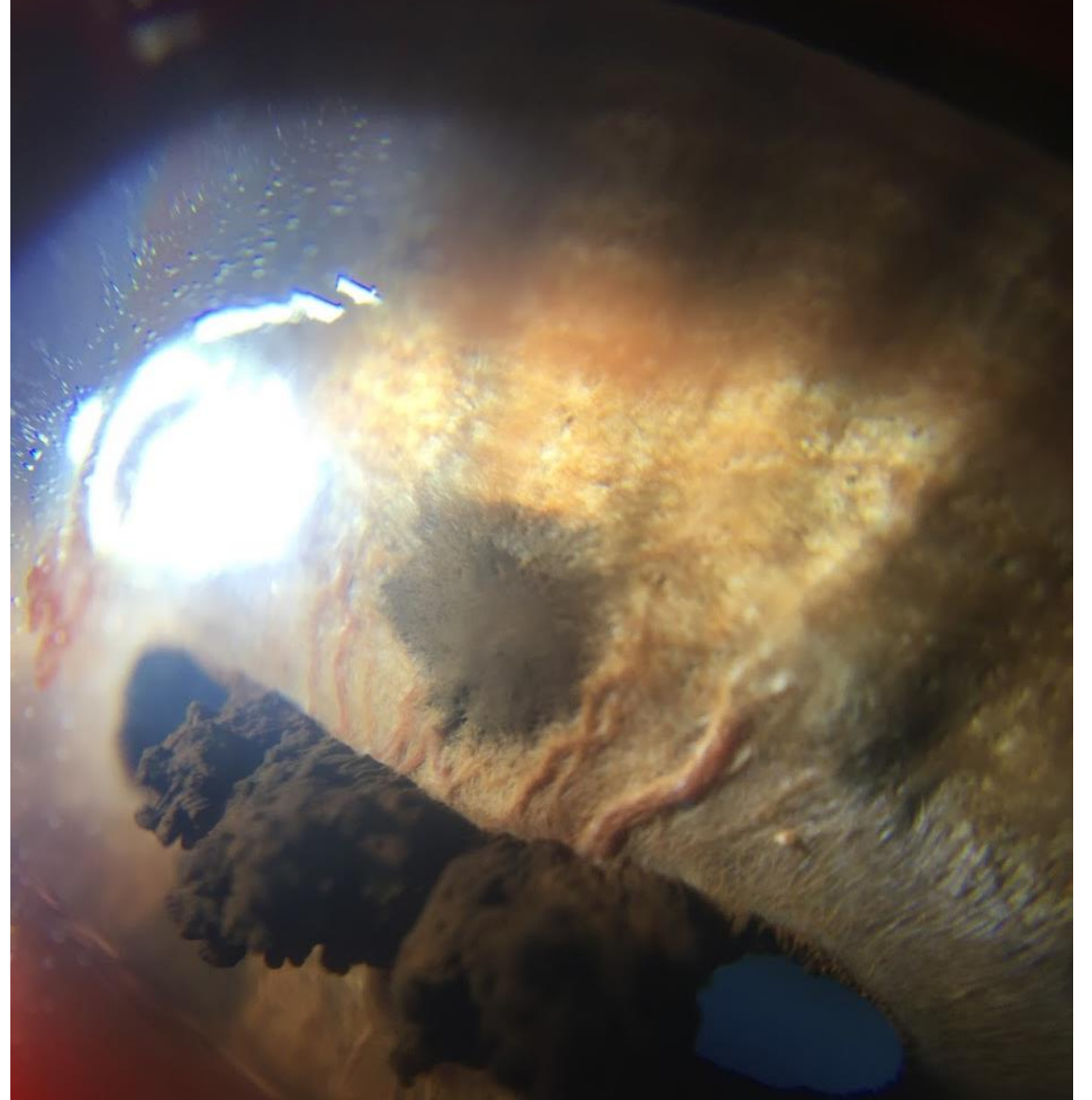


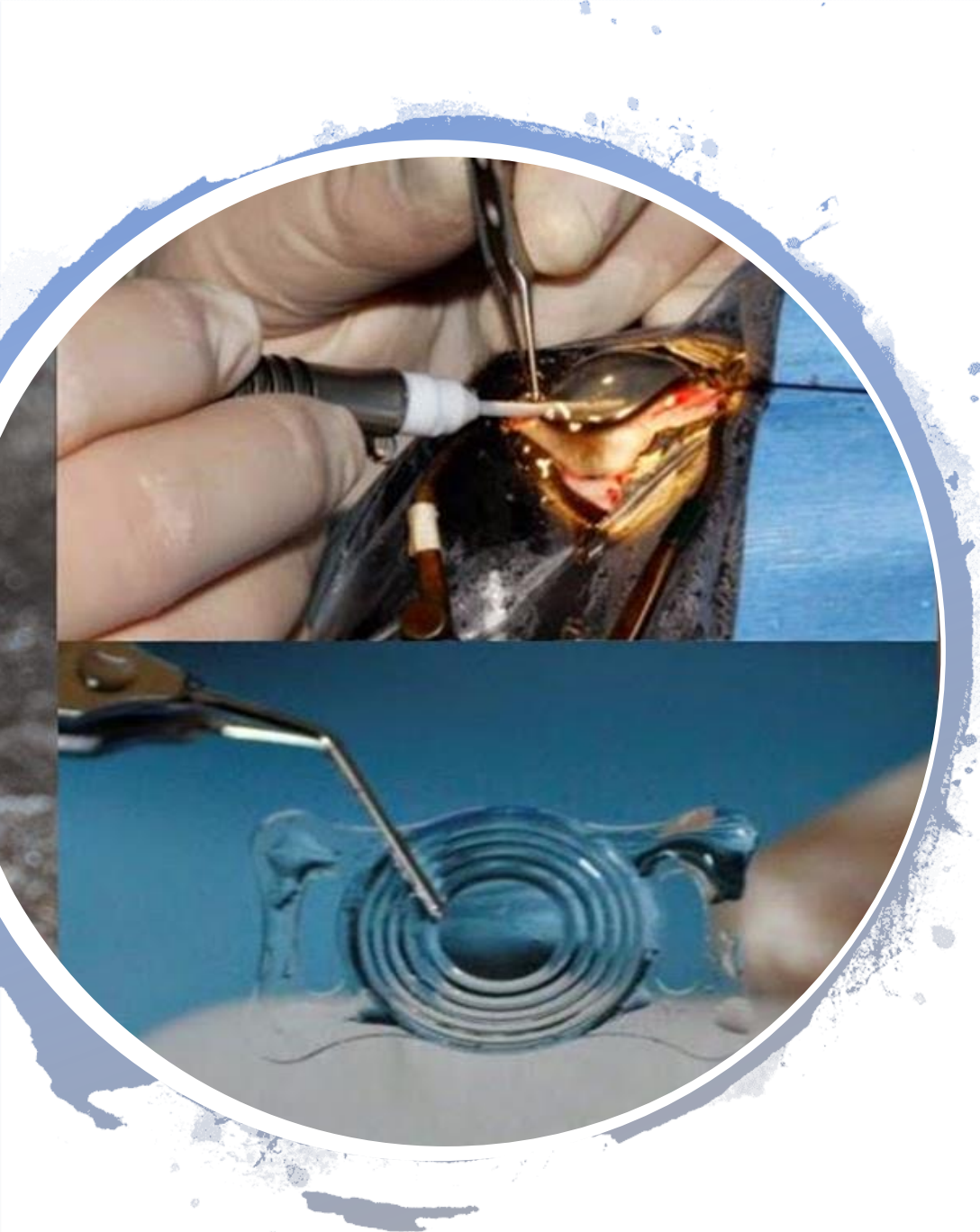
Which is most significant?



Which is most significant?





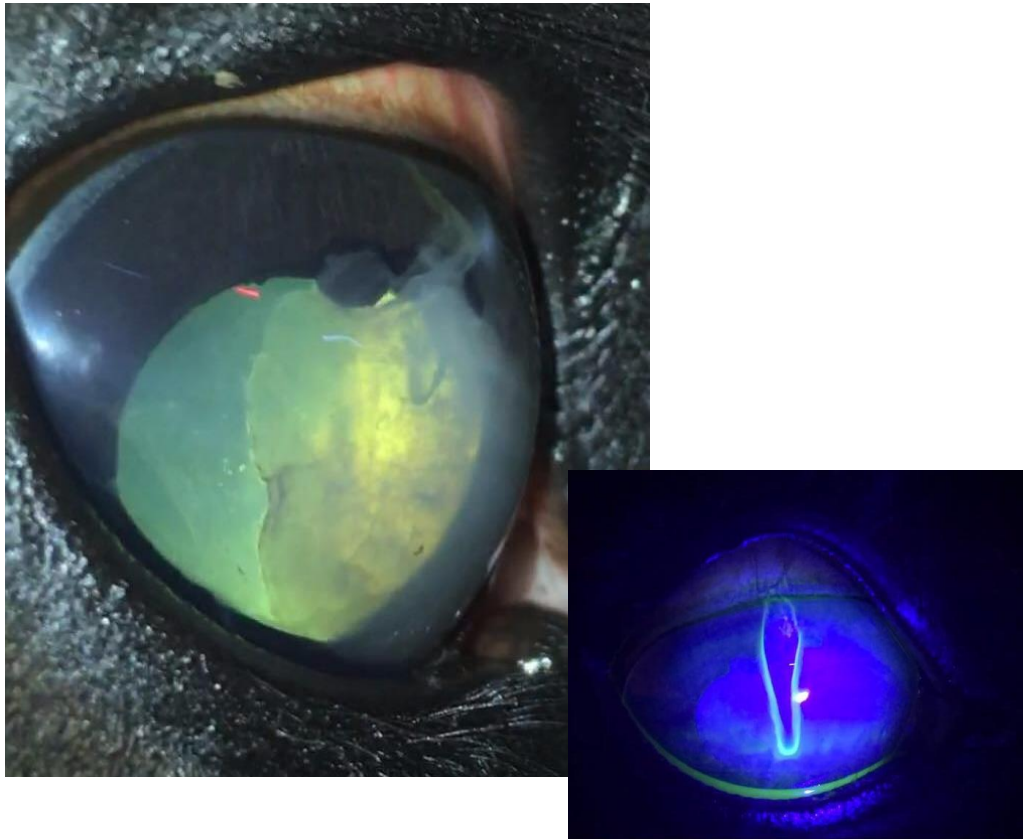


Lens surgery

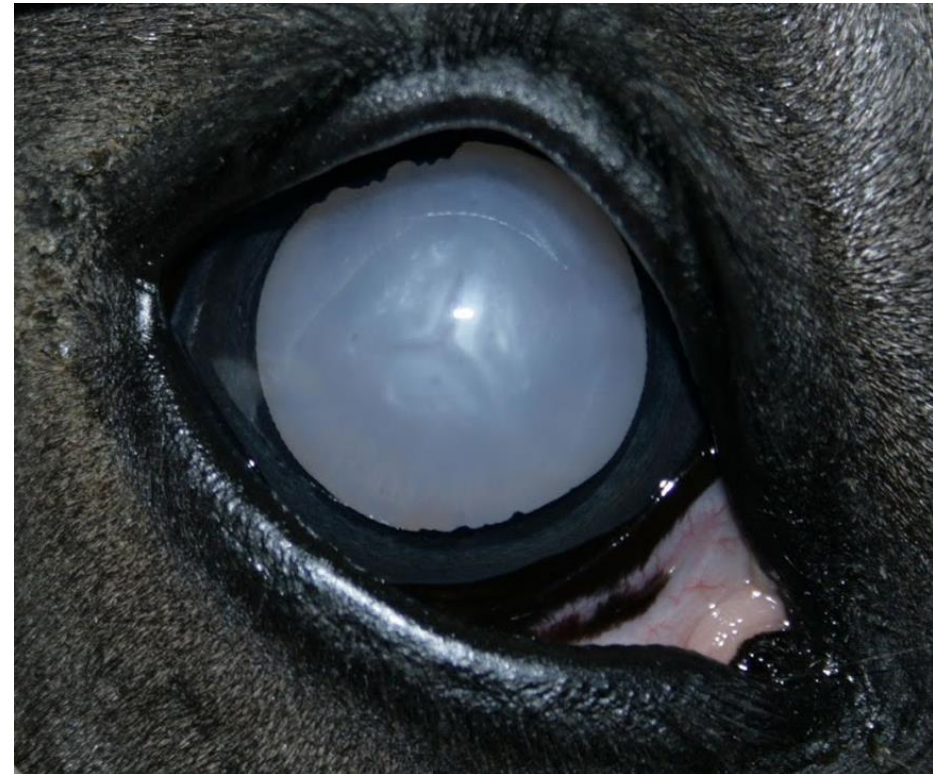- Equine specific prosthetic intraocular lenses & intraocular instrumentation alongside improvements in cataract machine technology means outcomes for equine cataract surgery have improved significantly in recent years.

Cataract / lens surgery

Emergent

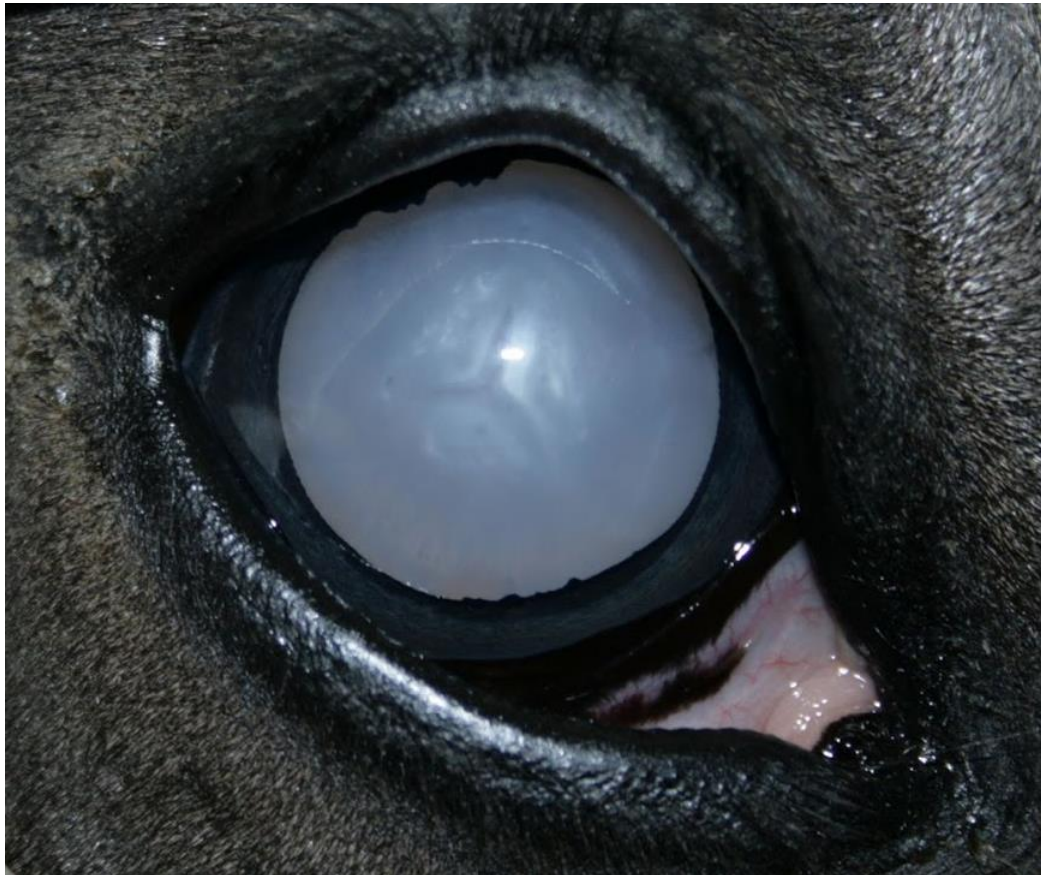

Elective

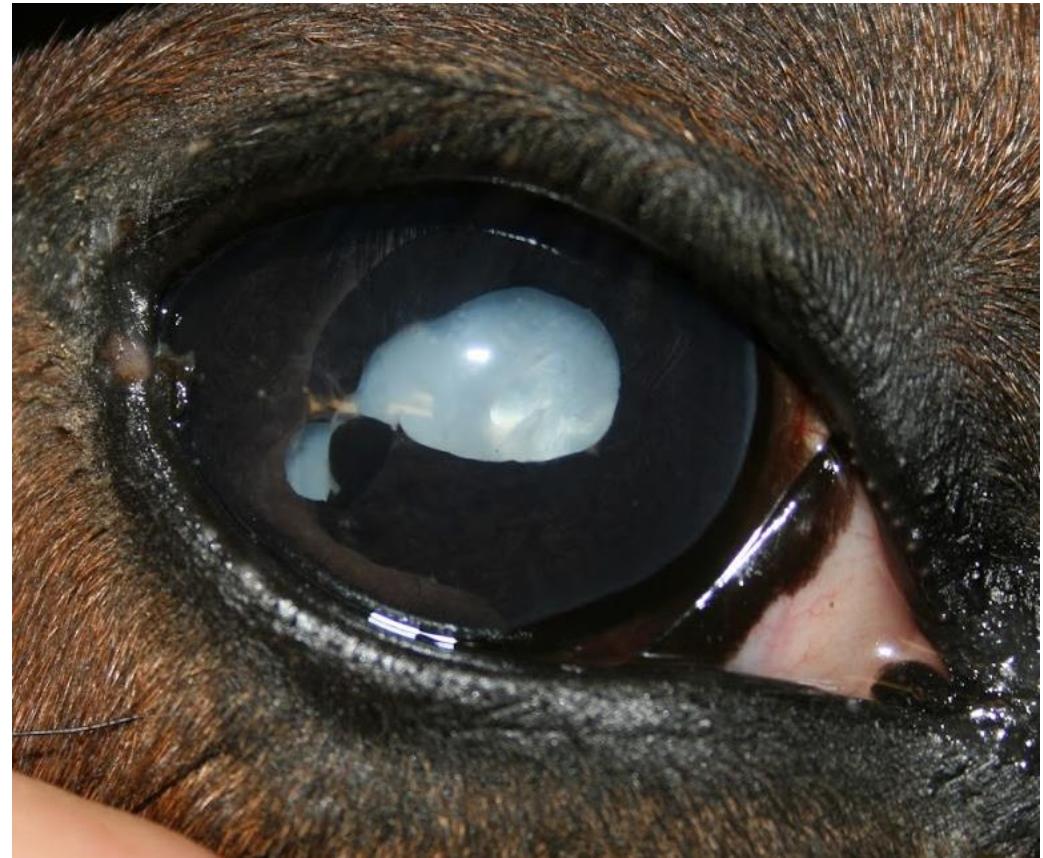

Elective cataract surgery

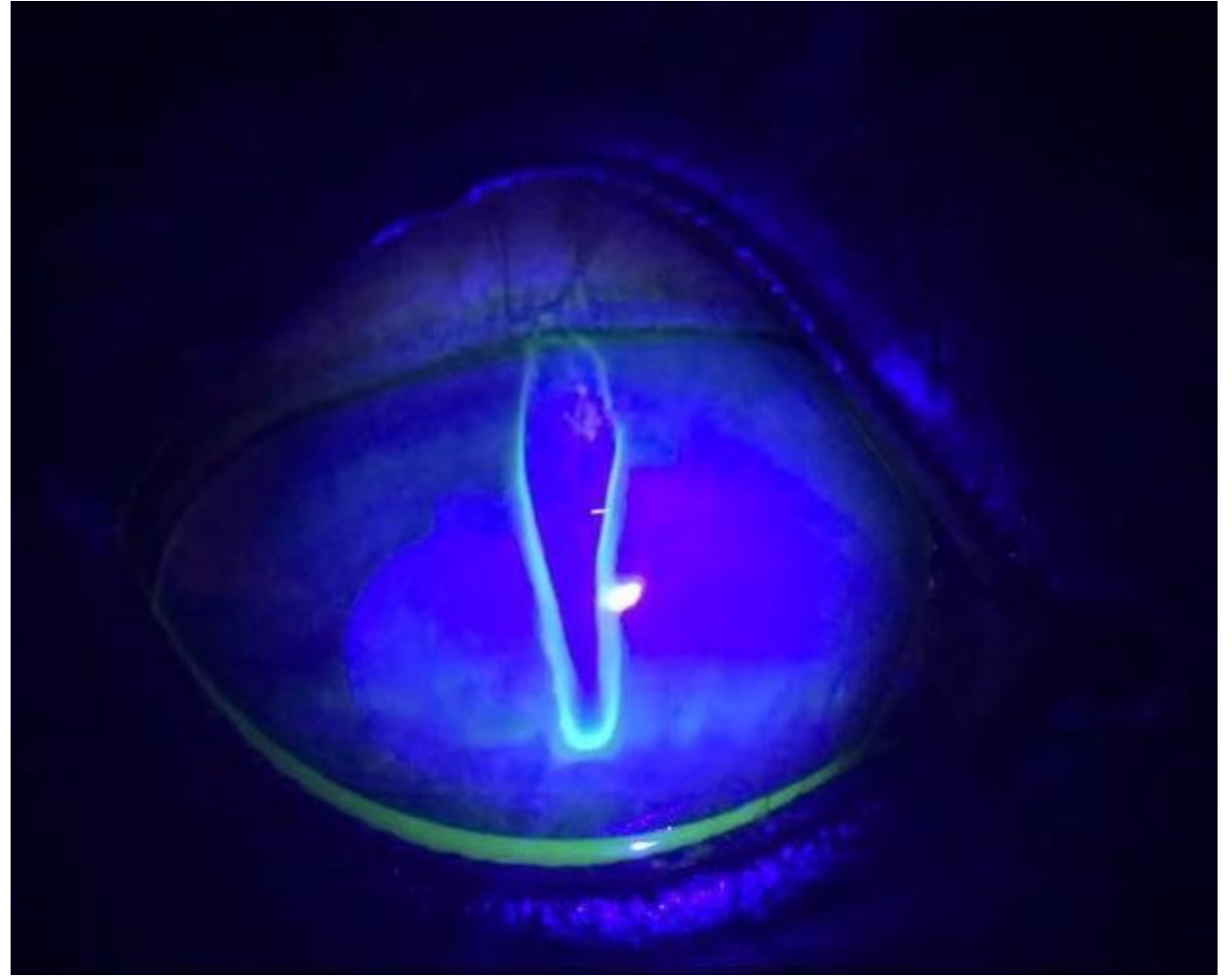
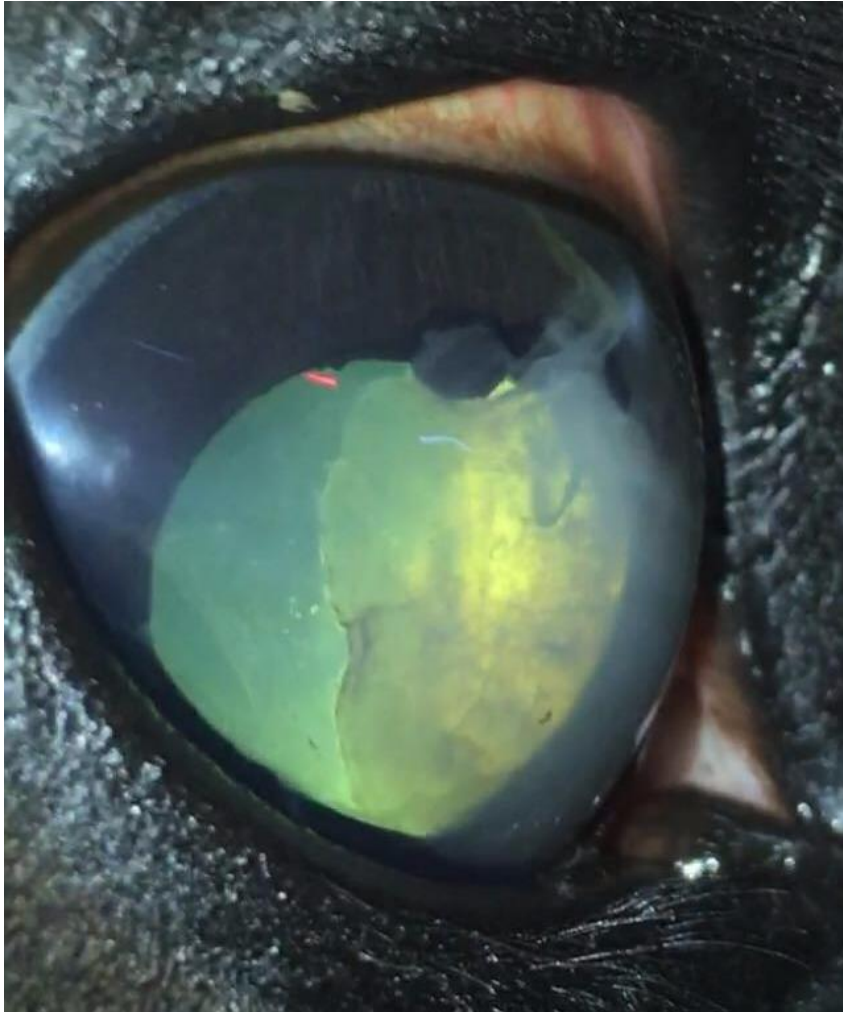
Developmental – do well



Secondary cataracts – case dependent

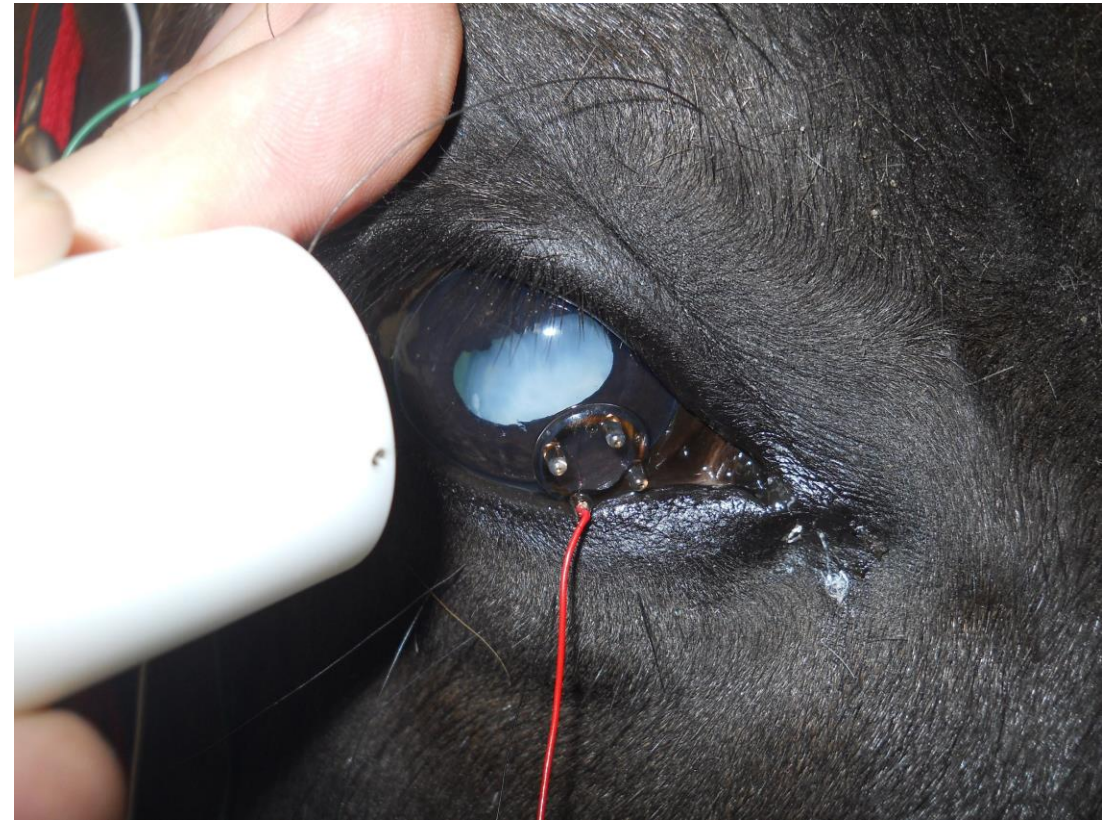

Emergent lens surgery

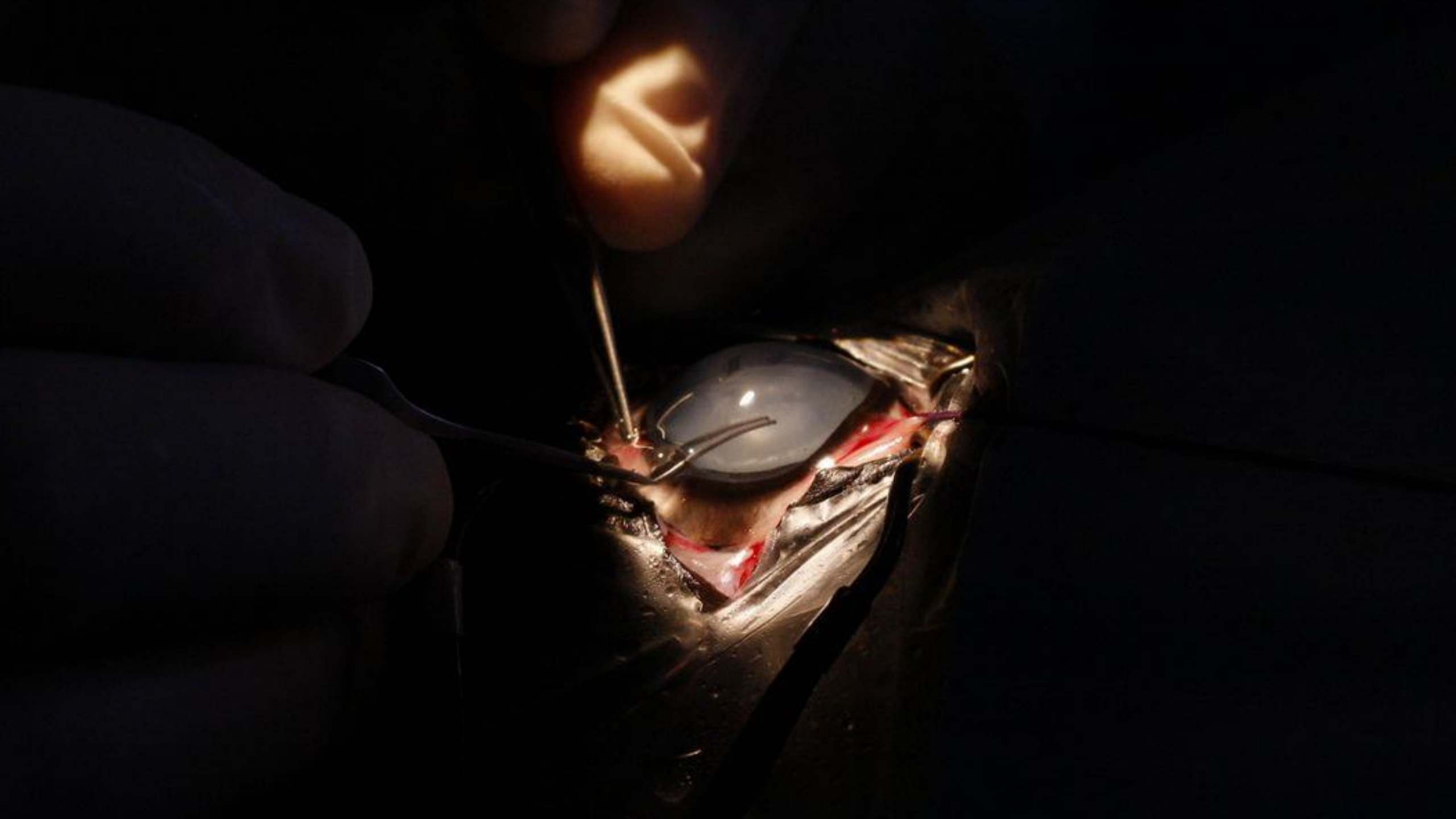

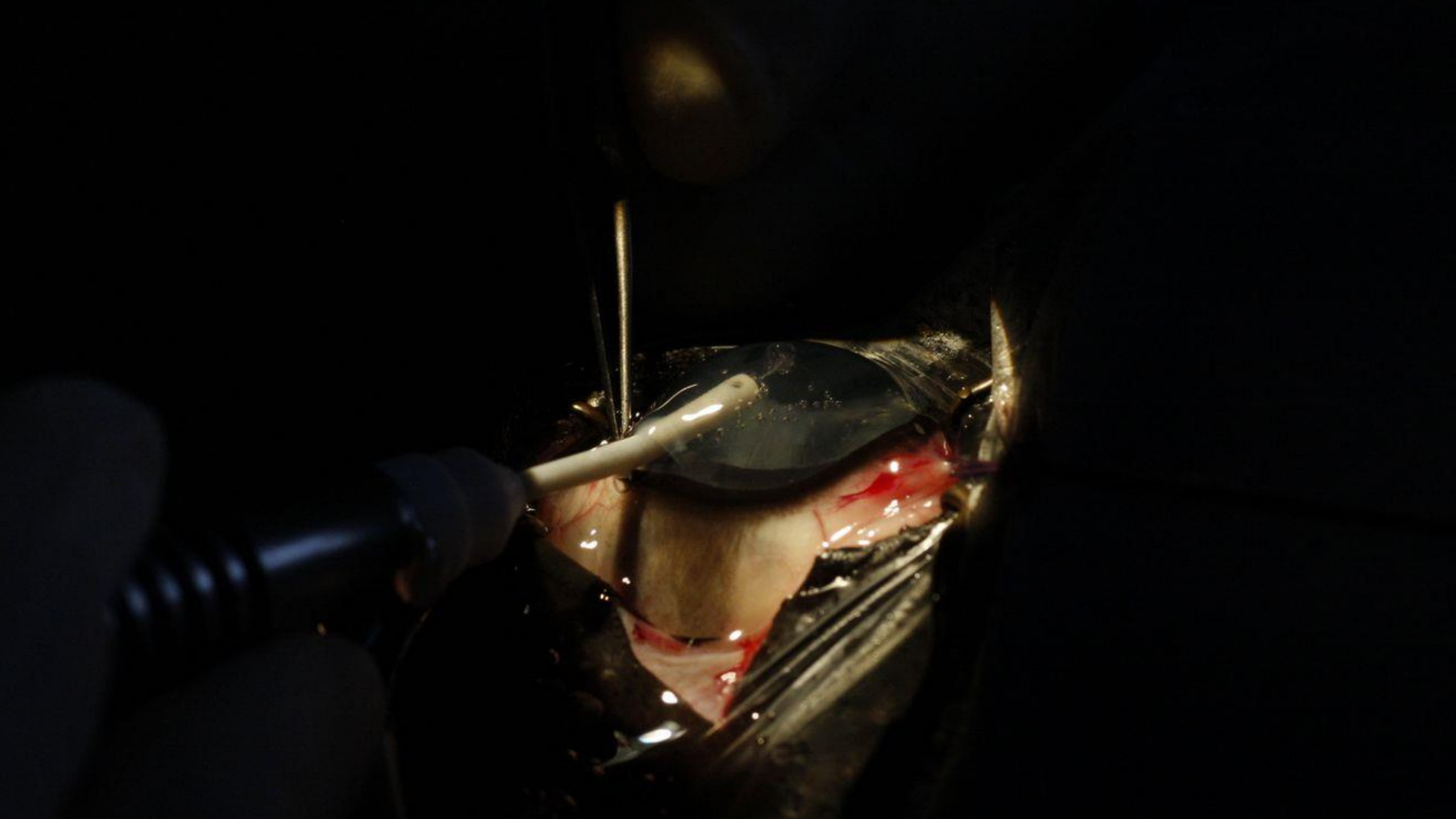
Protocol for elective cataract surgery

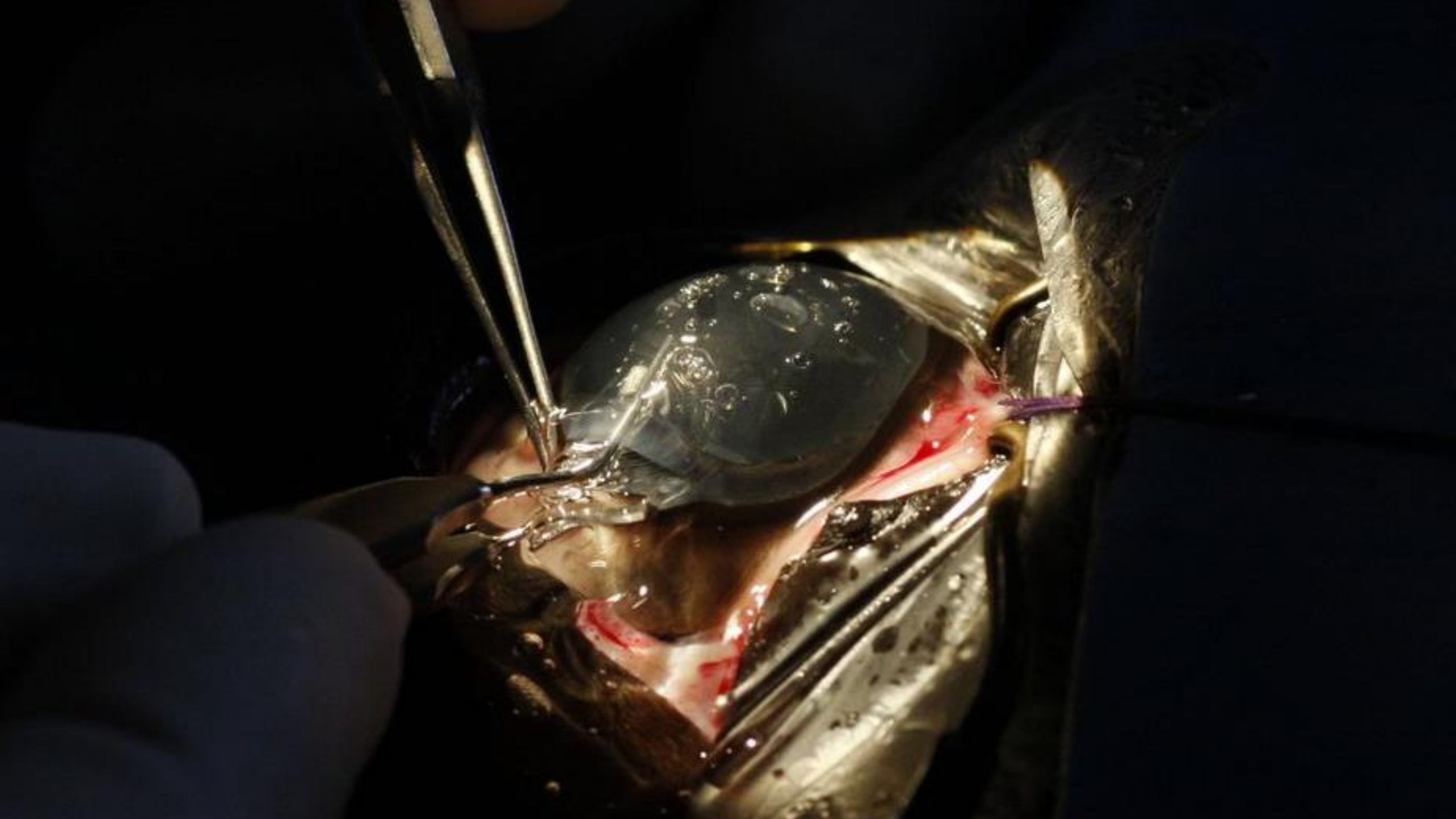
- Investigations & pre-treatment for 7 days
- GA
- Hospitalisation for 2 weeks post op
- 6-12 weeks systemic and/or topical anti-inflammatory medication

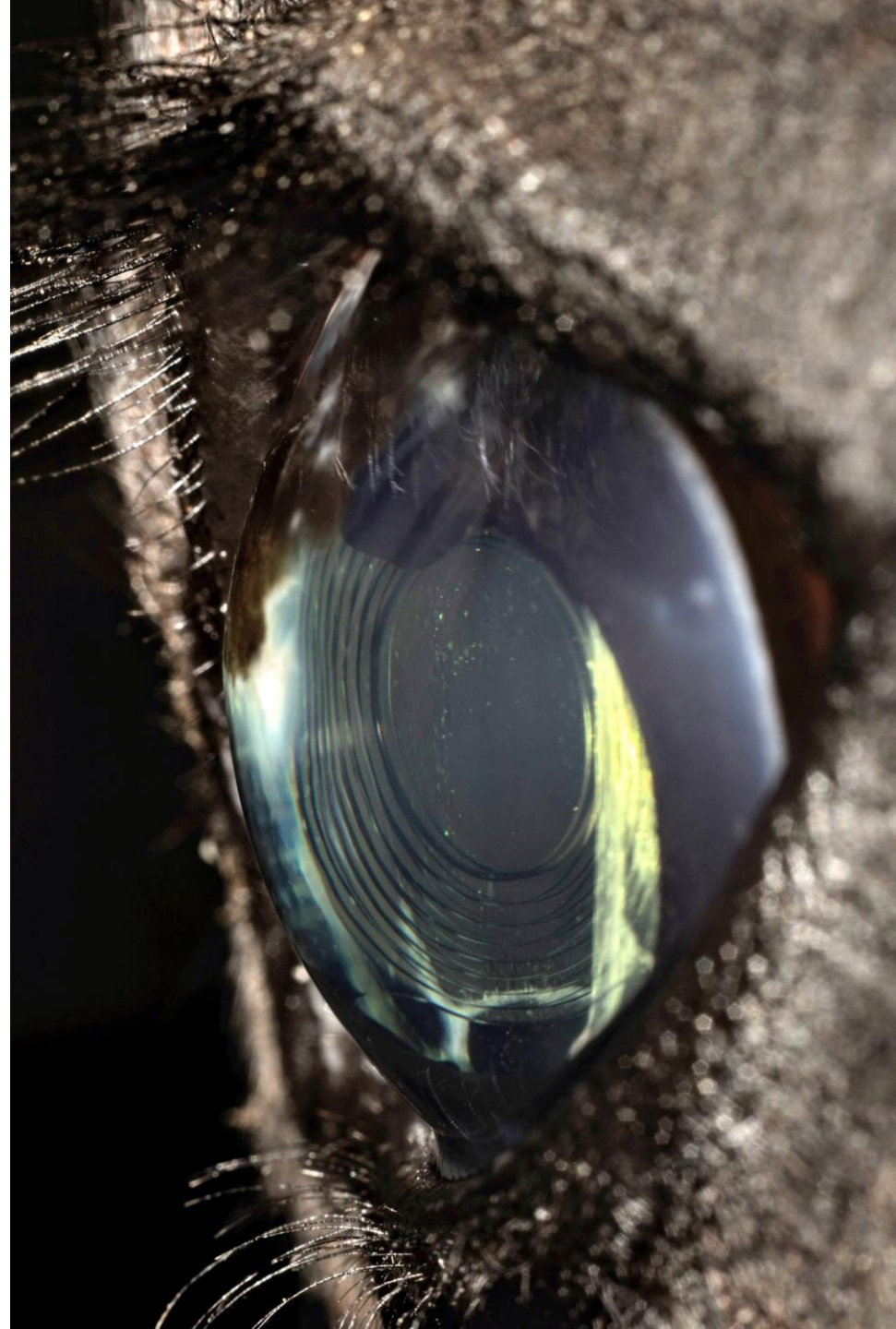




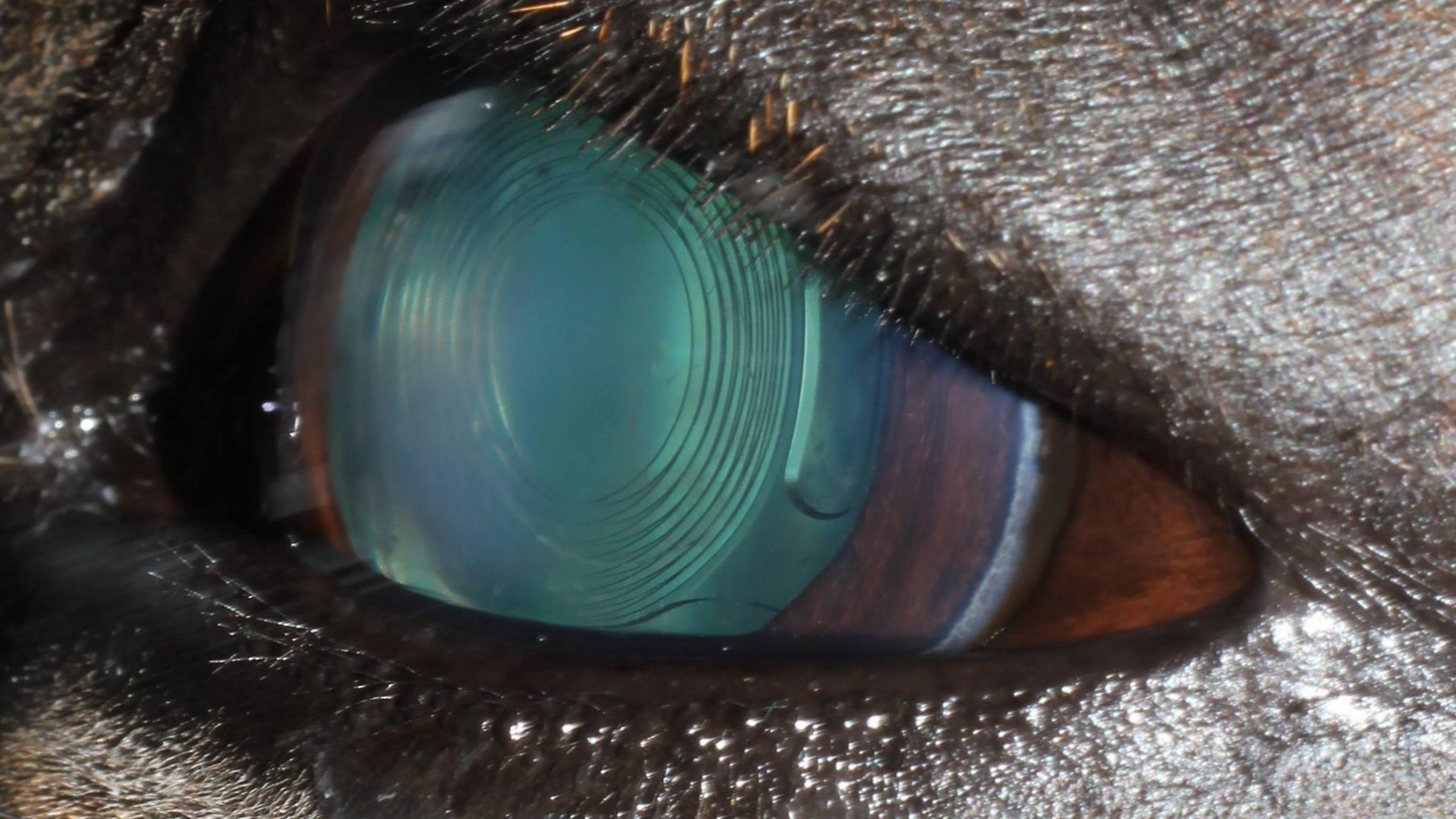




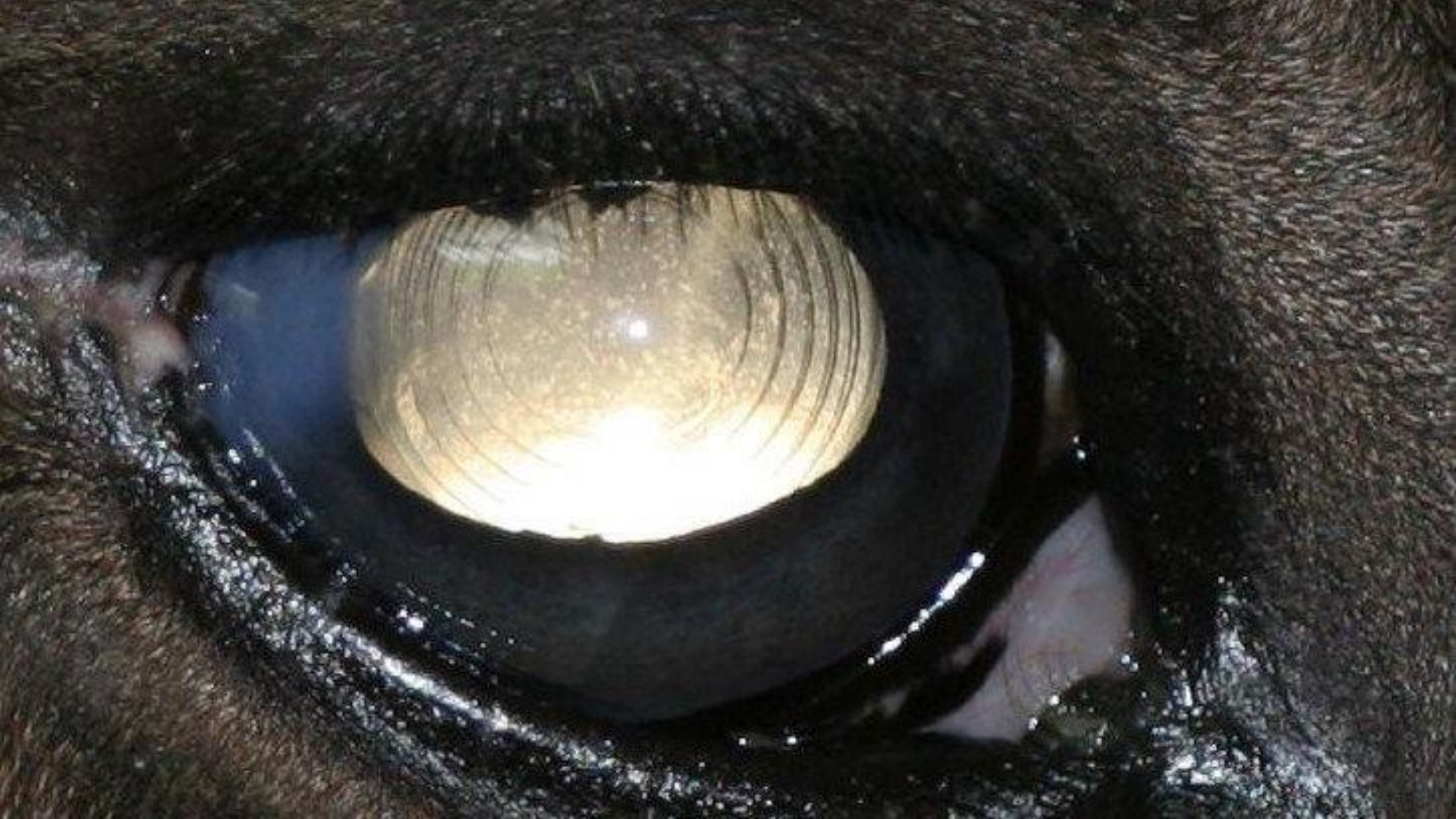


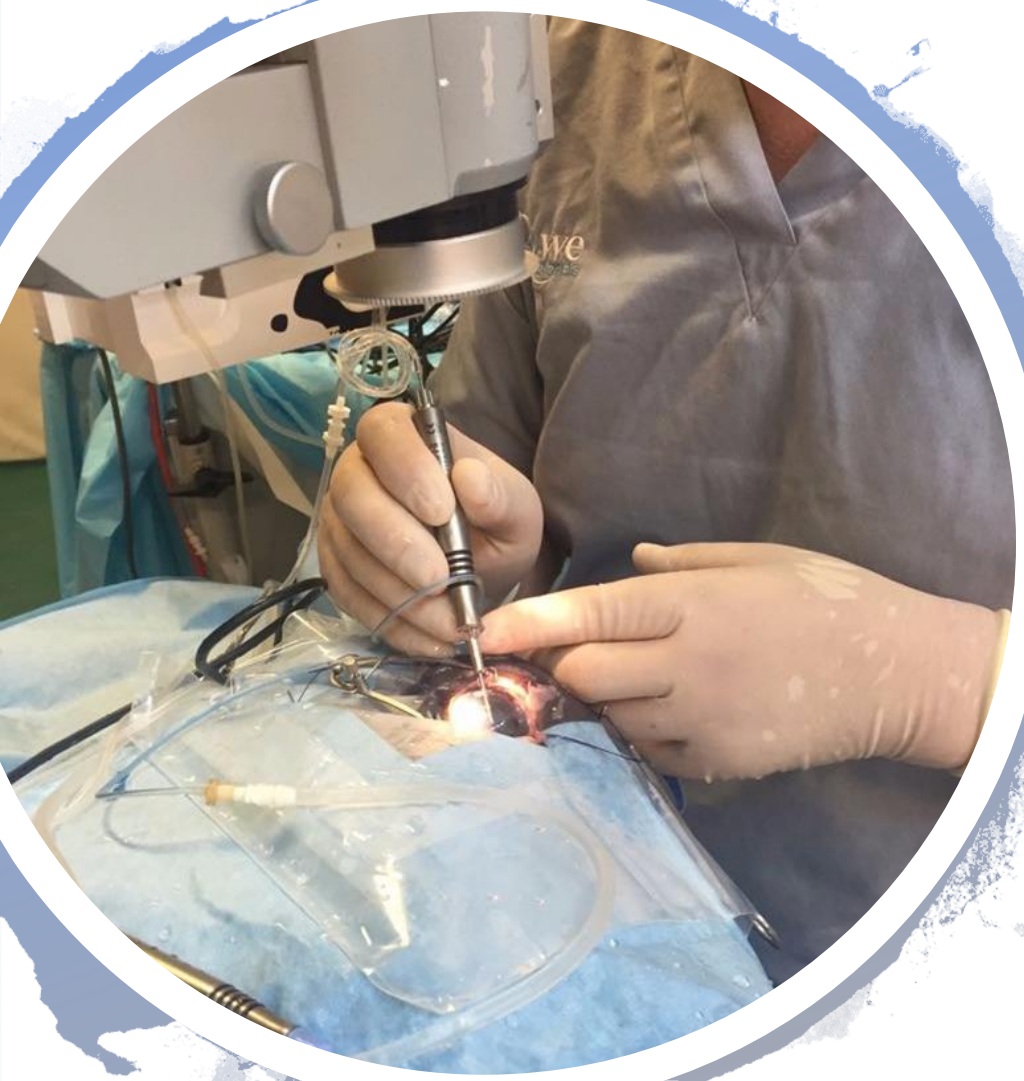








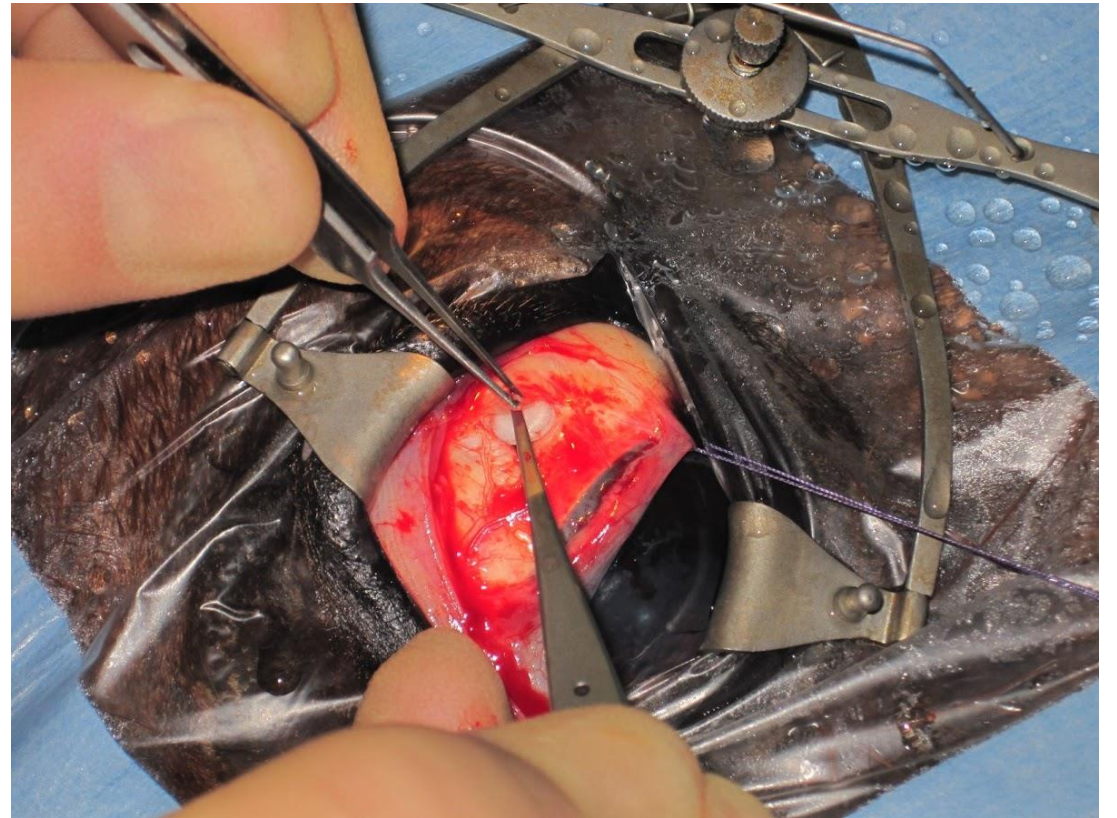
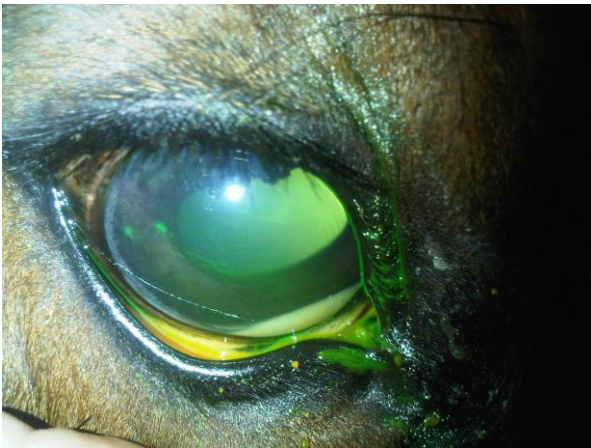


Uveitis surgery

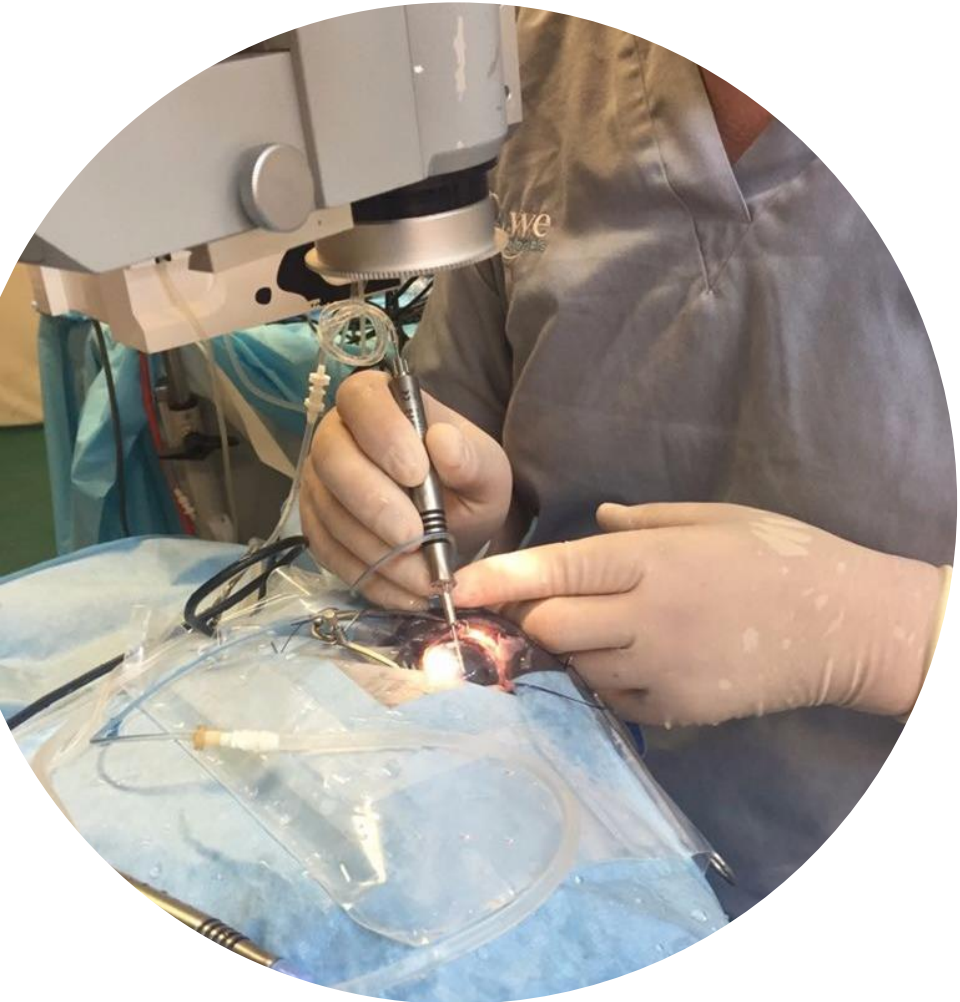- “Surgical treatment of recurrent uveitis using pars planar removal of the vitreal body and irrigation of the posterior segment with low dose Gentacin is widespread and reportedly successful in parts of mainland Europe for many years. This success has not been replicated in other parts of the world leading to the suggestion that there are geographical differences in aetiology. Leptospiral vitritis is thought to be a likely aetiology in the vitrectomy responsive cases. “

“Classic” ERU: Suprachoroidal cyclosporine

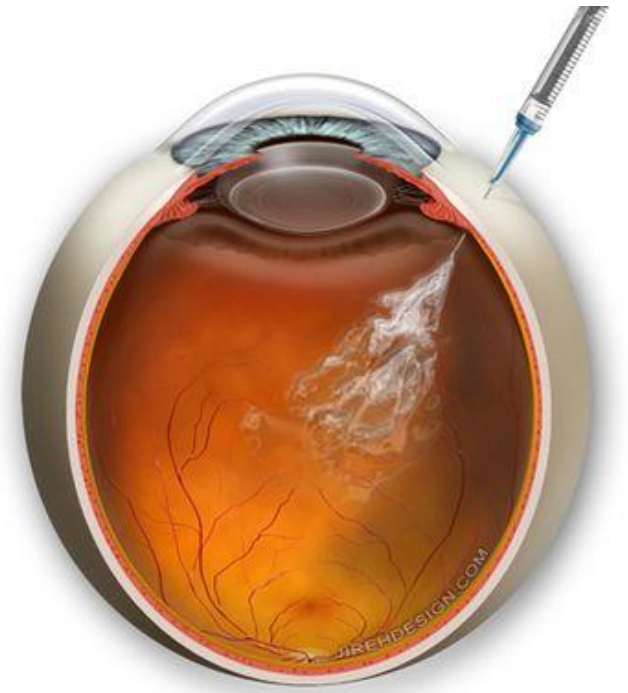Suprachoroidal implantation of slow release cyclosporine implants for the treatment of the Equine Recurrent Uveitis syndrome has been available for over a decade & still has a place in cases of steroid responsive classical ERU.



Posterior/Leptospiral vitritis

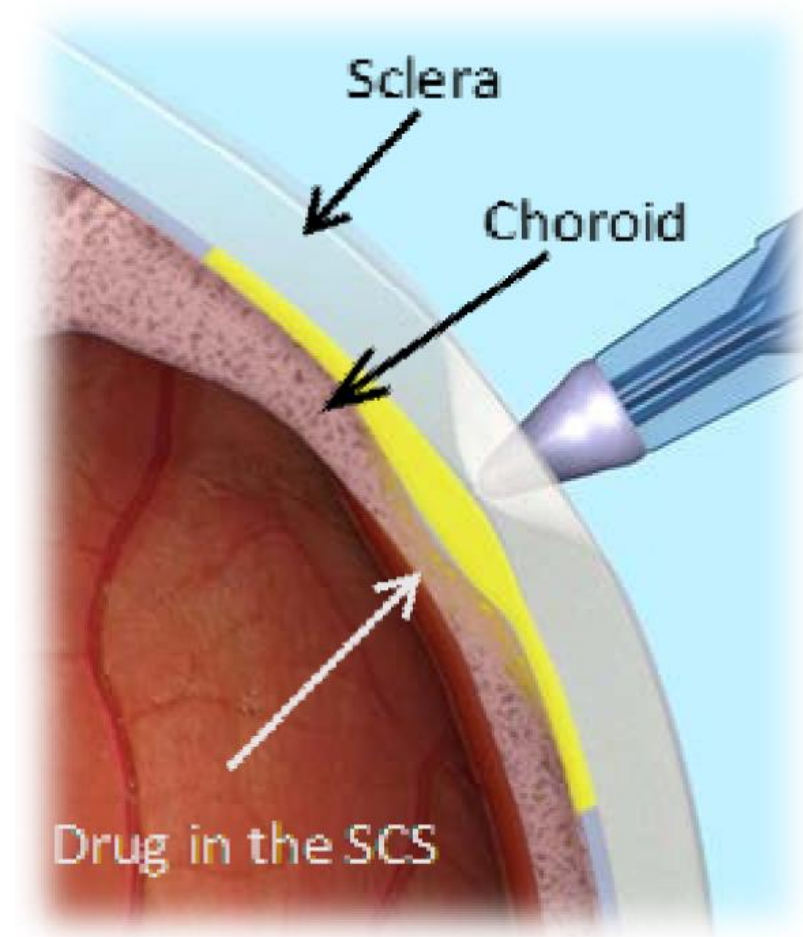
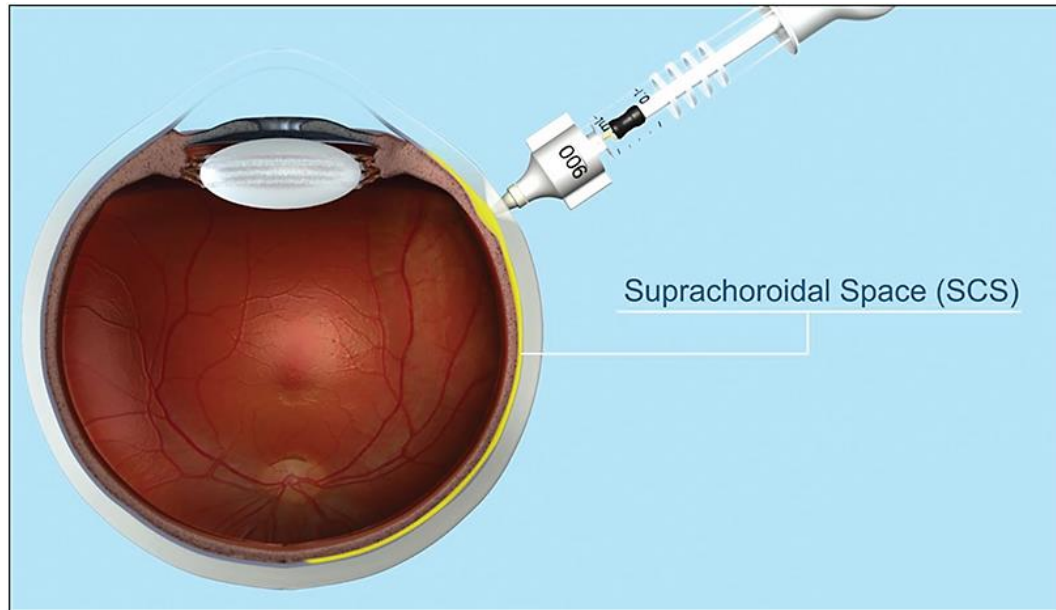


- Traditionally treated by vitrectomy
- Intra-vitreal injections- currently a specialist procedure but watch this space:
 - When to do?
 - What to give?
 - How to give?
 - Risks?



Supra-choroidal injection – the future?

- Technique likely to be more forgiving and thus more appropriate for more wide spread use.



[Home](#)[Locate a Member](#)[Membership](#)[Resources](#)[Education](#)[Research](#)

Edinburgh, Scotland, EU - 2023



2023 IEOC Equine Ophthalmology Symposium Edinburgh, Scotland

June 1-3, 2023



Quick Links

- [Home](#)
- [Forums](#)
- [Forum & Profile Help](#)
- [Industry News](#)
- [Resources](#)
- [Locate a Member](#)
- [What's Your Diagnosis?](#)
- [Member Publications](#)
- [Clinical Articles](#)
- [Glossary](#)